

PATIENT

Chester Kaminski

SPECIES

Canine

BREED

Beagle Mix

SEX

Neutered male

AGE

5 years

WEIGHT

21.2 lbs

PRESENTING CLINICAL SIGNS

History: Patient with history of megaesophagus presents for echo due to a grade 3/6 heart murmur. No current meds.

ULTRASONOGRAPHIC EXAMINATION OF THE HEART

CANINE CARDIAC PARAMETERS	MR VMAX (m/s)	TR VMAX (m/s)	LA/AO (Boon method)	LA/AO (Heart Base; Swe)	FS (%)	EF (%)	EPSS (cm)
NORMAL PARAMETER	4.5-5.5	<2.7	1.3	<1.3	28-40	40-100	<0.6
PATIENT	--	--	1.0	1.2	31	60	0.19
CANINE CARDIAC PARAMETERS	HR (BPM)	AV VMAX (m/s)	PV MAX (m/s)	BODY WEIGHT (kg)	LA 2D short axis Base view (cm)	LVIDd Avg; 2D and m-mode short axis (cm)	LVIDs Avg; 2D and m-mode short axis (cm)
NORMAL PARAMETER	50-100	0.7-1.7	0.7-1.6				
PATIENT	136	1.41	1.43	--	2.53	2.62	--

INTERPRETED BY

Eric Lindquist, DMV, DABVP, Cert. IVUSS, CFO of SonoPath.com

IMAGING PERFORMED BY

Kelly Vazquez, CVT

HOSPITAL NAME

Sova AH

REFERRING VET

Dr. Bott Wentworth

INVOICE

18201

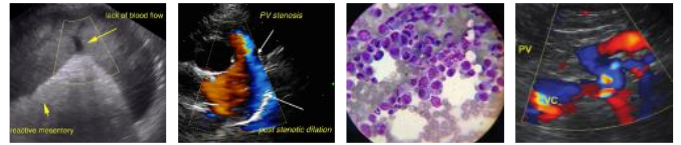
DATE

11/25/22

Cardiac Presentation

The echocardiogram in this patient demonstrated normal **left atrial** size based on 3 different LA measurement methods. Chamber volumes and echogenicity were normal. The cranial and caudal **mitral** valve leaflets presented vegetative thickening consistent with endocardiosis. Doppler indicated measurable insufficiency. The **left ventricle** presented thicknesses with linear contour and was not dilated nor restricted. The **myocardium** presented normal echogenicity without subjective evidence of significant fibrotic or ischemic disease. **Contractility** of the ventricular walls was adequate and in normal range for this patient evidenced by the fractional shortening measurement and subjective evaluation of the different regions of the myocardium. The **left ventricular outflow tract** demonstrated normal laminar flow and subjective structural integrity. The **right atrium** and auricle revealed normal size, structure and content. No evidence of masses was noted or chamber overload. **Tricuspid** valvular assessment demonstrated adequate linear morphology. The **right ventricle** was of normal size (1/3 diameter of LV), chordae structure, myocardial echogenicity and thickness. **Pulmonic** tract assessment revealed normal valve structure, laminar flow, and diameter (approx.1:1 pa/ao ratio). No visible **pericardial** or free pleura fluid was noted. No echographically detectable evidence of infiltrative disease was visible. The cranial **mediastinum and pericardial regions** were free of masses in the visible window. The patient presented tachypnea with some respiratory interference of the mitral valve, however, some minor mitral insufficiency appeared to be present yet not clinically significant.

ULTRASONOGRAPHIC FINDINGS



PATIENT

- Normal echocardiogram with minor trivial mitral turbulene, not clinically significant

Chester Kaminski

INTERPRETATION OF THE FINDINGS & FURTHER RECOMMENDATIONS

No therapy is recommended.

SPECIES

Canine

BREED

Beagle Mix

SEX

Neutered male

AGE

5 years

WEIGHT

21.2 lbs

INTERPRETED BY

Eric Lindquist, DMV,
DABVP, Cert. IVUSS,
CFO of SonoPath.com

IMAGING PERFORMED BY

Kelly Vazquez, CVT

HOSPITAL NAME

Sova AH

REFERRING VET

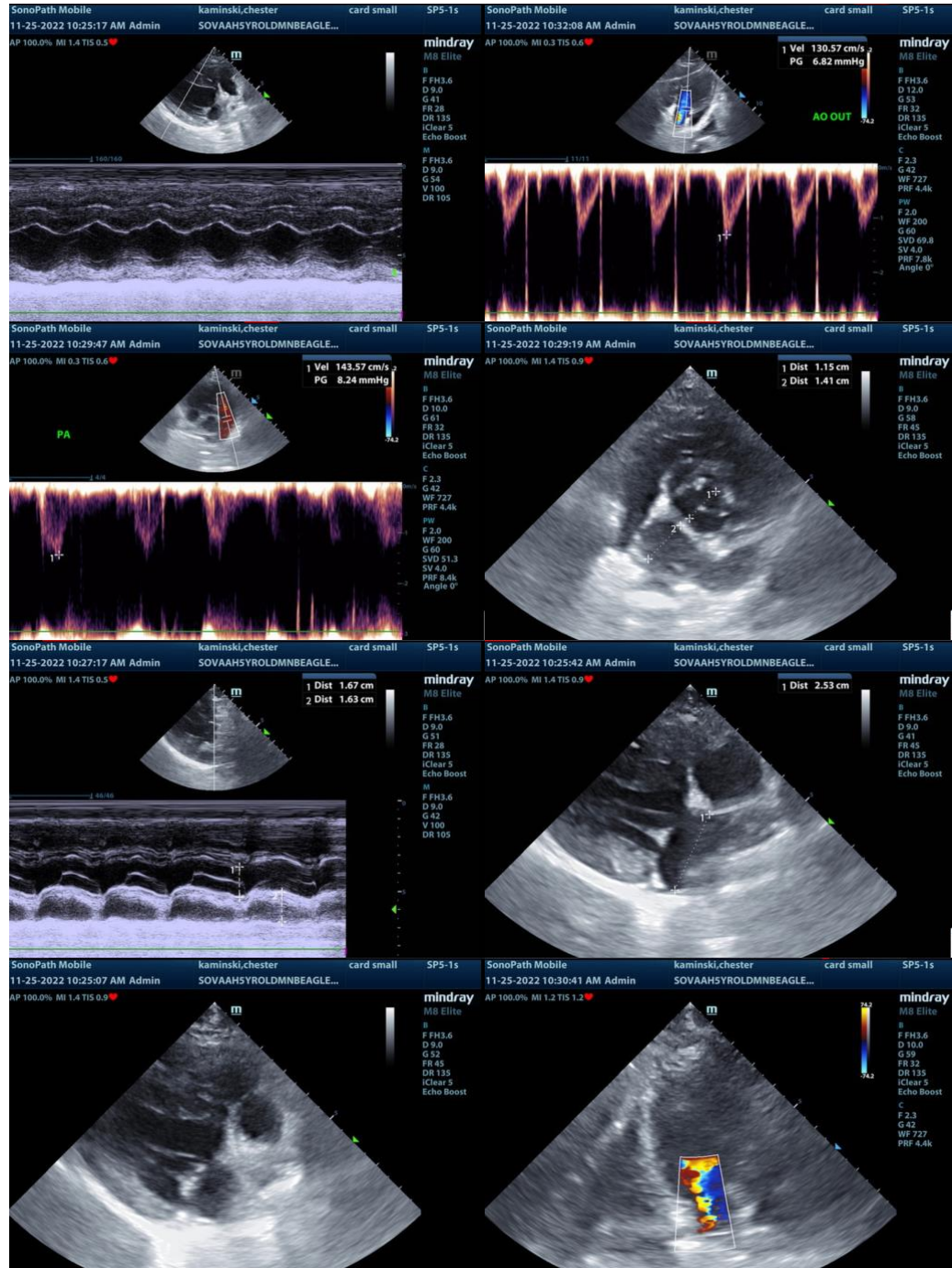
Dr. Bott Wentworth

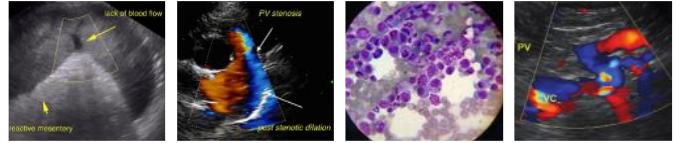
INVOICE

18201

DATE

11/25/22





PATIENT

Chester Kaminski

The information and recommendations provided are based on the images presented by the referring veterinarian/sonographer. No evaluation can be communicated regarding pathology that was not visible in the image/video clips provided.

SPECIES

Canine

Thank you for this referral. If the clinical or image interpretation does not parallel your findings or if I can be of any further assistance please contact me.

Eric Lindquist, DMV, DABVP, Cert. IVUSS, CEO of SonoPath.com

BREED

Beagle Mix

Info@SonoPath.com

SEX

Neutered male

AGE

5 years

WEIGHT

21.2 lbs

INTERPRETED BY

Eric Lindquist, DMV,
DABVP, Cert. IVUSS,
CEO of SonoPath.com

**IMAGING
PERFORMED BY**

Kelly Vazquez , CVT

HOSPITAL NAME

Sova AH

REFERRING VET

Dr. Bott Wentworth

INVOICE

18201

DATE

11/25/22