


PATIENT PRESENTING CLINICAL SIGNS

King Jones History: heart murmur; not on any meds

SPECIES ULTRASONOGRAPHIC EXAMINATION OF THE HEART

Canine

BREED

Doberman Pinscher

The cardiac presentation presented moderate volume overload of the left atrium and left ventricle with hypocontractility. This is consistent with myocardial insufficiency. Excessive aortic outflow velocity is noted with aortic insufficiency. Mitral insufficiency was moderate to severe with septal deviated jet. The right ventricle and right atrium were unremarkable; however, the deep pulmonary artery revealed a holosystolic flow. This is consistent with patent ductus arteriosus. Tricuspid insufficiency was noted. No pericardial or pleural pathology.

SEX

Intact male

AGE

5 months

WEIGHT

44.2 lbs

INTERPRETED BY

 Eric Lindquist, DMV
 DABVP, Cert. IVUSS

IMAGING PERFORMED BY

Diane McFadden, RVT

HOSPITAL NAME

Advanced VC

REFERRING VET

Dr. Weingartner

INVOICE

42658

DATE

11/22/22

CANINE CARDIAC PARAMETERS	MR VMAX (m/s)	TR VMAX (m/s)	LA/AO (Boon method)	LA/AO (Heart Base; Swe)	FS (%)	EF (%)	EPSS (cm)
NORMAL PARAMETER	4.5-5.5	<2.7	1.3	<1.6	28-40	40-100	<0.6
PATIENT	5.2	2.5	NM	1.27	17	36	1.76
CANINE CARDIAC PARAMETERS	HR (BPM)	AV VMAX (m/s)	PV MAX (m/s)	BODY WEIGHT	LA (2D short axis Base view) (cm)	LVIDd (Avg; 2D and m-mode short axis) (cm)	LVIDs (Avg; 2D and m-mode short axis) (cm)
NORMAL PARAMETER	50-100	0.7-1.7	0.7-1.6	BELOW	BELOW	BELOW	BELOW
PATIENT	162	5.5	1.2	44.2 lbs	5.4 max	6.0	

ULTRASONOGRAPHIC FINDINGS

Patent ductus arteriosus with mitral insufficiency and pseudo stenosis of the left ventricular outflow tract. This may be compensatory from the PDA or primary subaortic stenosis.

Concurrent myocardial insufficiency.

INTERPRETATION OF THE FINDINGS & FURTHER RECOMMENDATIONS

Referral for cardiology intervention is recommended. Poor prognosis without intervention.



PATIENT

King Jones

SPECIES

Canine

BREED

Doberman Pinscher

SEX

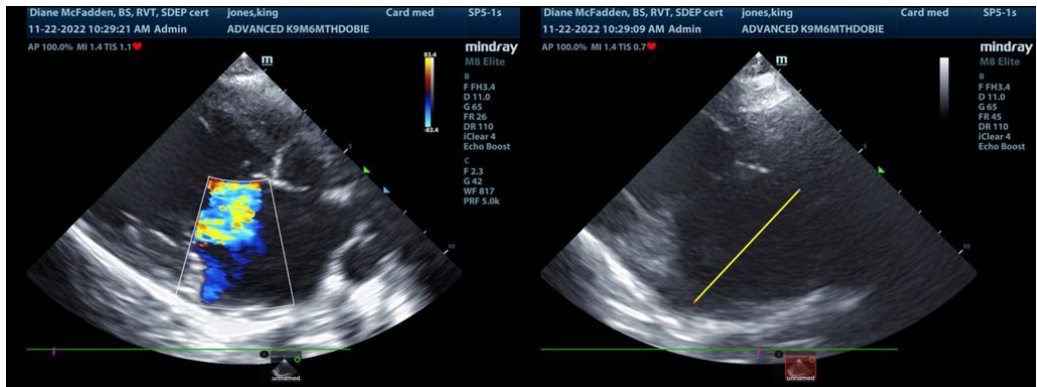
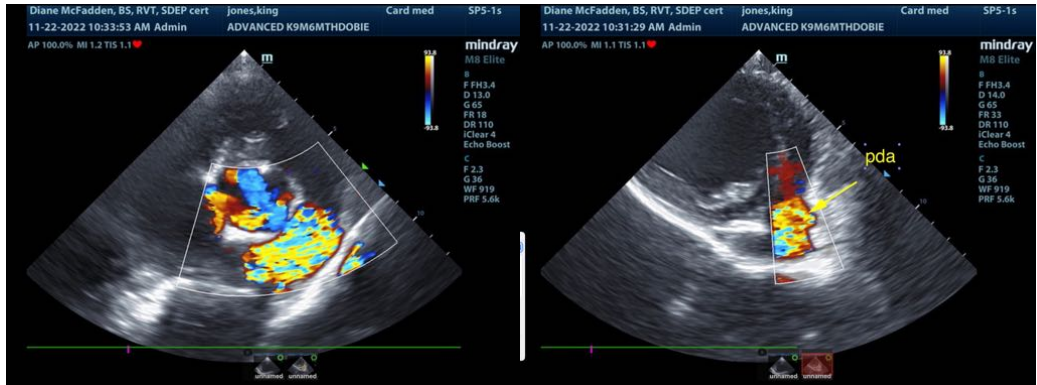
Intact male

AGE

5 months

WEIGHT

44.2 lbs



INTERPRETED BY

Eric Lindquist, DMV
DABVP, Cert. IVUS

IMAGING PERFORMED BY

Diane McFadden, RVT

HOSPITAL NAME

Advanced VC

REFERRING VET

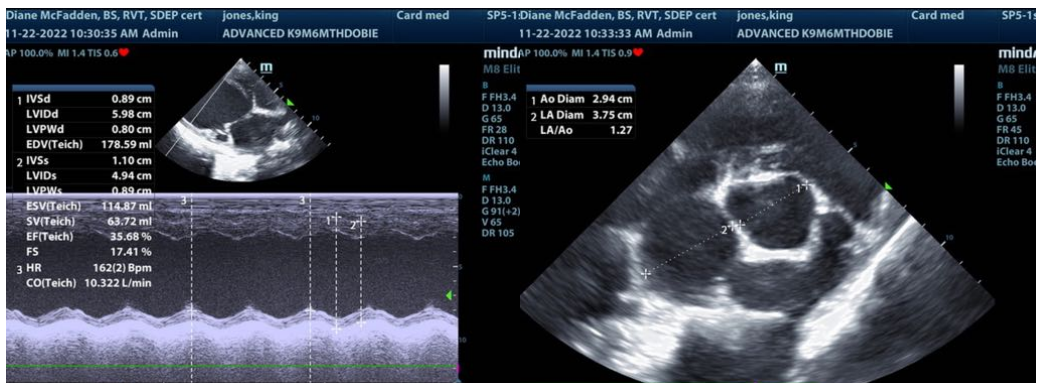
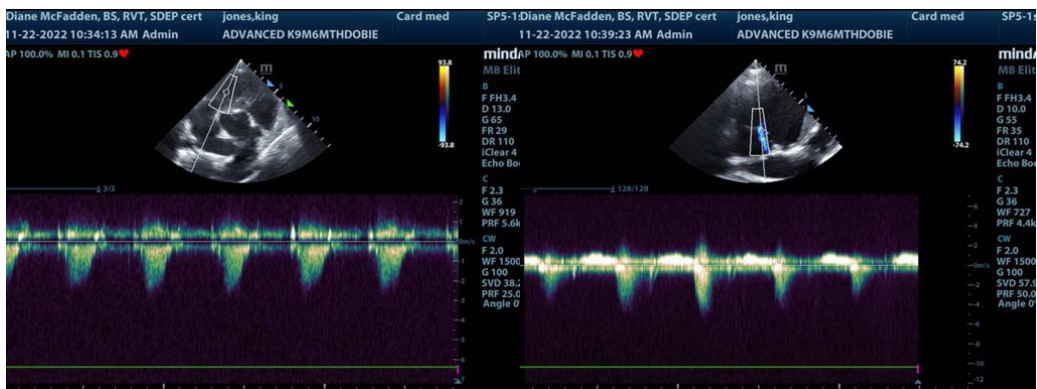
Dr. Weingartner

INVOICE

42658

DATE

11/22/22





PATIENT

King Jones

SPECIES

Canine

BREED

Doberman Pinscher

SEX

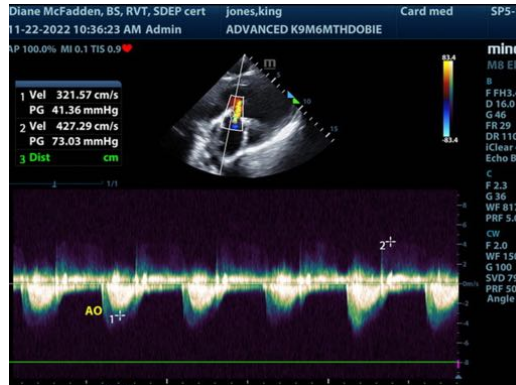Intact male

AGE

5 months

WEIGHT

44.2 lbs



The information and recommendations provided are based on the images presented by the referring veterinarian/sonographer. No evaluation can be communicated regarding pathology that was not visible in the image/video clips provided.

Thank you for this referral. If the clinical or image interpretation does not parallel your findings or if I can be of any further assistance please contact me.

Eric Lindquist, DMV, DABVP, Cert. IVUSS, CEO of SonoPath.com
Info@SonoPath.com

INTERPRETED BY

Eric Lindquist, DMV
DABVP, Cert. IVUSS

IMAGING PERFORMED BY

Diane McFadden, RVT

HOSPITAL NAME

Advanced VC

REFERRING VET

Dr. Weingartner

INVOICE

42658

DATE

11/22/22