



**PATIENT**

Oscar Purushothaman

**SPECIES**

Canine

**BREED**

Cavapoo

**SEX**

Neutered male

**AGE**

9 ½ years

**WEIGHT**

21.4 lbs

**INTERPRETED BY**

Eric Lindquist, DMV  
DABVP, Cert. IVUSS

**IMAGING PERFORMED BY**

Diane McFadden, RVT

**HOSPITAL NAME**

Animal Care Center of  
Flanders

**REFERRING VET**

Dr. Hallihan

**INVOICE**

42134

**DATE**

10/24/22

**PRESENTING CLINICAL SIGNS**

History: 10/8/22 murmur noted

Abnormal PE/Chem/CBC/UA Results: platelets 108 decreased; chol 436, amylase 277, neuts decr 59, lymphs incr 33

**ULTRASONOGRAPHIC EXAMINATION OF THE ABDOMEN**

The echocardiogram in this patient demonstrated normal **left atrial** size based on 3 different LA measurement methods. Chamber volumes and echogenicity were normal. The cranial and caudal **mitral** valve leaflets presented vegetative thickening consistent with endocardiosis. Doppler indicated measurable insufficiency. The **left ventricle** presented normal thicknesses with linear contour and was not dilated nor restricted. The **myocardium** presented normal echogenicity without subjective evidence of significant fibrotic or ischemic disease. **Contractility** of the ventricular walls was adequate and in normal range for this patient evidenced by the fractional shortening measurement and subjective evaluation of the different regions of the myocardium. The **left ventricular outflow** tract demonstrated normal laminar flow and subjective structural integrity. The **right atrium** and auricle revealed normal size, structure and content. No evidence of masses was noted or chamber overload. **Tricuspid** valvular assessment demonstrated adequate linear morphology. The **right ventricle** was of normal size (1/3 diameter of LV), chordae structure, myocardial echogenicity and thickness. **Pulmonic** tract assessment revealed normal valve structure, laminar flow, and diameter (approx. 1:1 pa/ao ratio). No visible **pericardial** or free pleura fluid was noted. No echographically detectable evidence of infiltrative disease was visible. The cranial **mediastinum and pericardial regions** were free of masses in the visible window.

CANINE CARDIAC PARAMETERS	MR VMAX (m/s)	TR VMAX (m/s)	LA/AO (Boon method)	LA/AO (Heart Base; Swe)	FS (%)	EF (%)	EPSS (cm)
NORMAL PARAMETER	4.5-5.5	<2.7	1.3	<1.6	28-40	40-100	<0.6
PATIENT	5.18		1.3	1.56	32	62	0.2
CANINE CARDIAC PARAMETERS	HR (BPM)	AV VMAX (m/s)	PV MAX (m/s)	BODY WEIGHT	LA (2D short axis Base view) (cm)	LVIDd (Avg; 2D and m-mode short axis) (cm)	LVIDs (Avg; 2D and m-mode short axis) (cm)
NORMAL PARAMETER	50-100	0.7-1.7	0.7-1.6	BELOW	BELOW	BELOW	BELOW
PATIENT	127	0.98	1.0	21.4 lbs	2.5	2.56	



**PATIENT**

**ULTRASONOGRAPHIC FINDINGS**

Oscar Purushothaman

Stage B1 valvular disease.

**SPECIES**

Canine

**INTERPRETATION OF THE FINDINGS & FURTHER RECOMMENDATIONS**

There is no evidence of volume overload.

**BREED**

Cavapoo

The heart is stable without clinical disease. No overt contraindication for anesthesia of brief to moderate duration. I suggest Torbutrol premed, Propofol induction, Isoflor maintenance or similar protocol if anesthesia is desired. Blood pressure recommended if not already performed and target white coat negative systolic pressure of < 160 mmHg. If higher than this ACE-inhibitor is suggested to reach this level. Recheck echocardiogram is recommended in 6 months, earlier if murmur grade increases or clinical signs initiate.

**SEX**

Neutered male

**AGE**

9 ½ years

**WEIGHT**

21.4 lbs

**INTERPRETED BY**

Eric Lindquist, DMV  
DABVP, Cert. IVUSS

**IMAGING PERFORMED BY**

Diane McFadden, RVT

**HOSPITAL NAME**

Animal Care Center of  
Flanders

**REFERRING VET**

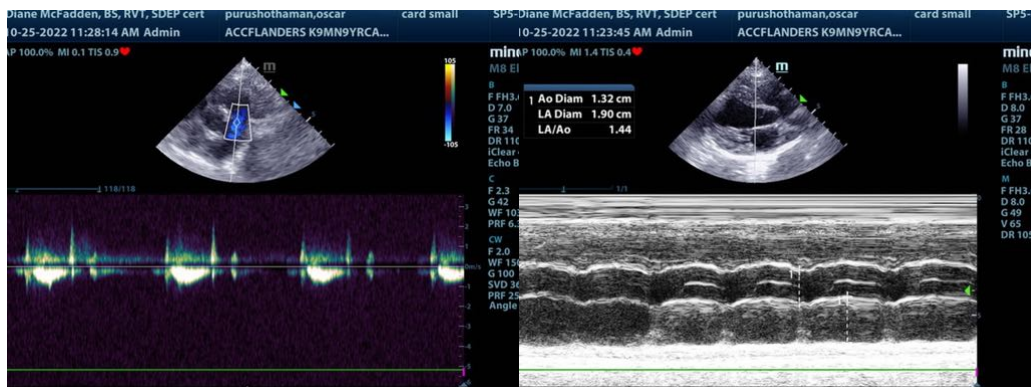
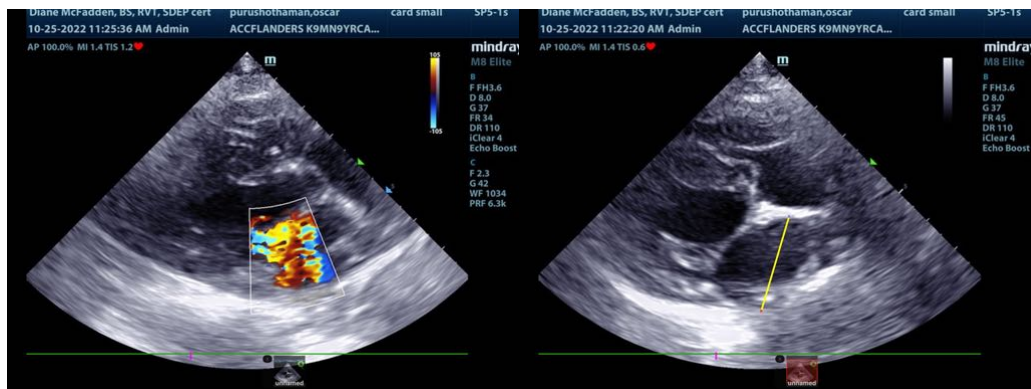
Dr. Hallihan

**INVOICE**

42134

**DATE**

10/24/22





**PATIENT**

Oscar Purushothaman

**SPECIES**

Canine

**BREED**

Cavapoo

**SEX**

Neutered male

**AGE**

9 ½ years

**WEIGHT**

21.4 lbs

**INTERPRETED BY**

Eric Lindquist, DMV  
DABVP, Cert. IVUSS

**IMAGING PERFORMED BY**

Diane McFadden, RVT

**HOSPITAL NAME**

Animal Care Center of  
Flanders

**REFERRING VET**

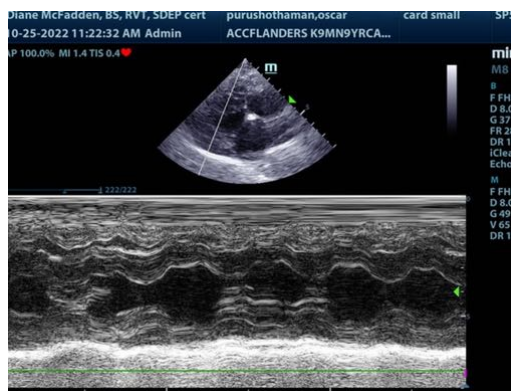
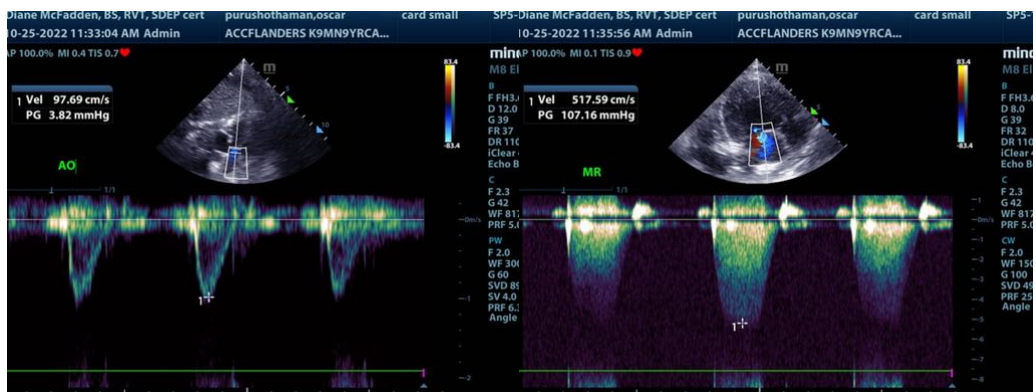
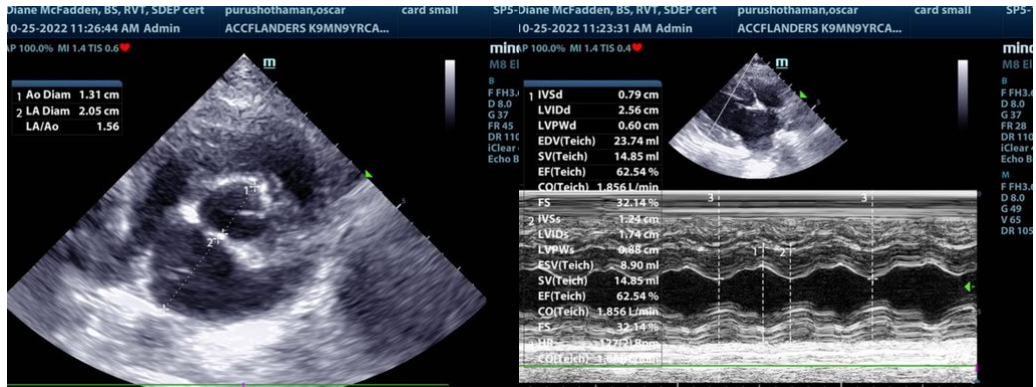
Dr. Hallihan

**INVOICE**

42134

**DATE**

10/24/22



The information and recommendations provided are based on the images presented by the referring veterinarian/sonographer. No evaluation can be communicated regarding pathology that was not visible in the image/video clips provided.

Thank you for this referral. If the clinical or image interpretation does not parallel your findings or if I can be of any further assistance please contact me.

Eric Lindquist, DMV, DABVP, Cert. IVUSS, CEO of SonoPath.com  
Info@SonoPath.com