



PATIENT PRESENTING CLINICAL SIGNS

Gracie Keihm Seizure.

SPECIES ULTRASONOGRAPHIC EXAMINATION OF THE HEART

Feline

BREED

Domestic Shorthair

SEX

Spayed female

AGE

18 years

The echocardiogram in this patient demonstrated normal **left atrial** size based on 3 separate LA measurements. Trivial **mitral** valve insufficiency was noted, yet not clinically significant. The **left ventricle** presented normal thicknesses with linear contour and was not dilated nor restricted. **Myocardial** remodeling was noted in this patient, yet no dysfunction was noted. **Contractility** of the ventricular walls was adequate and in normal range for this patient evidenced by the fractional shortening measurement and subjective evaluation of the different regions and angles of the myocardium. The **left ventricular outflow** tract demonstrated normal laminar flow and subjective structural integrity. The **right atrium** and auricle revealed normal size, structure and content. No evidence of masses was noted or chamber overload. **Tricuspid** valvular assessment demonstrated adequate linear morphology and kinetics. The **right ventricle** was of normal size (1/3 diameter of LV), chordae structure, myocardial echogenicity and thickness. **Pulmonic** tract assessment revealed normal valve structure, laminar flow, and diameter (approx. 1:1 pa/ao ratio). No visible **pericardial** or free pleura fluid was noted or extra cardiac pathology in the visible planes. The cranial **mediastinum** and **pericardial regions** were free of masses in the visible window.

INTERPRETED BY

Eric Lindquist, DMV
DABVP, Cert. IVUSS

IMAGING PERFORMED BY

Eric Lindquist, DMV
DABVP, Cert. IVUSS

HOSPITAL NAME

Franklin Lakes AH

REFERRING VET

Dr. Pomerantz

INVOICE

42125

DATE

10/25/22

ULTRASONOGRAPHIC FINDINGS

Minor myocardial remodeling.

Otherwise, normal echocardiogram with trivial mitral valve insufficiency.

FELINE CARDIAC PARAMETERS	BODY WEIGHT (kg)	HR (BPM)	IVSd (cm)	LVIDd (cm)	LVWd (cm)	FS (%)	EF (%)
NORMAL PARAMETER	-----	150-240	0.3-0.6	1.0-2.1	0.25-0.6	35-67	80-100
PATIENT		158	0.58	1.26	0.62	47	82
FELINE CARDIAC PARAMETERS	LA/AO (Boon)	LA/AO HEART BASE (Sisson)	LA 2D 4-chamber long axis AS to FW (Sisson) (cm)	LVOT VEL. (m/s)	RVOT VEL. (m/s)	IVRT (m/)	
NORMAL PARAMETER	<1.5	0.88-1.79	0.7-1.7	<1.6	<1.3	40-60	
PATIENT		1.1		1.3	0.81	NM	
Adapted from June Boon, Veterinary Echocardiography, 1998 Sisson D et al. JVIM 1991; 5: 232, Jacobs et al. Am J Vet Res 1985; 46:1705							



PATIENT

Gracie Keihm

SPECIES

Feline

BREED

Domestic Shorthair

SEX

Spayed female

AGE

18 years

INTERPRETED BY

Eric Lindquist, DMV
DABVP, Cert. IVUSS

IMAGING PERFORMED BY

Eric Lindquist, DMV
DABVP, Cert. IVUSS

HOSPITAL NAME

Franklin Lakes AH

REFERRING VET

Dr. Pomerantz

INVOICE

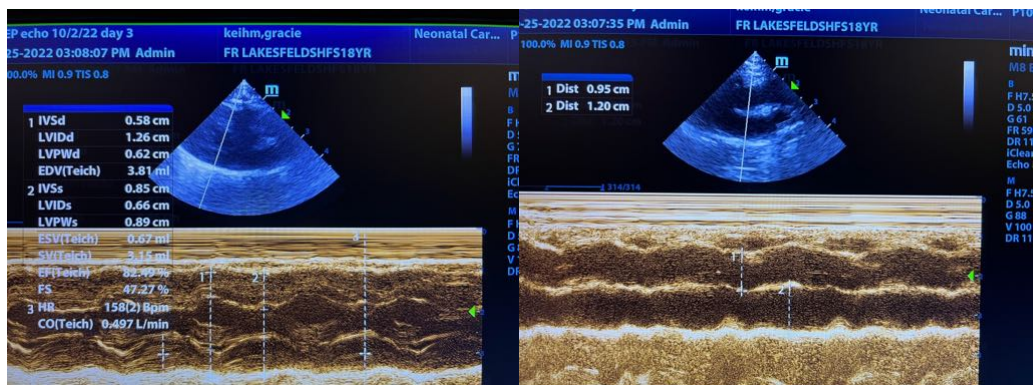
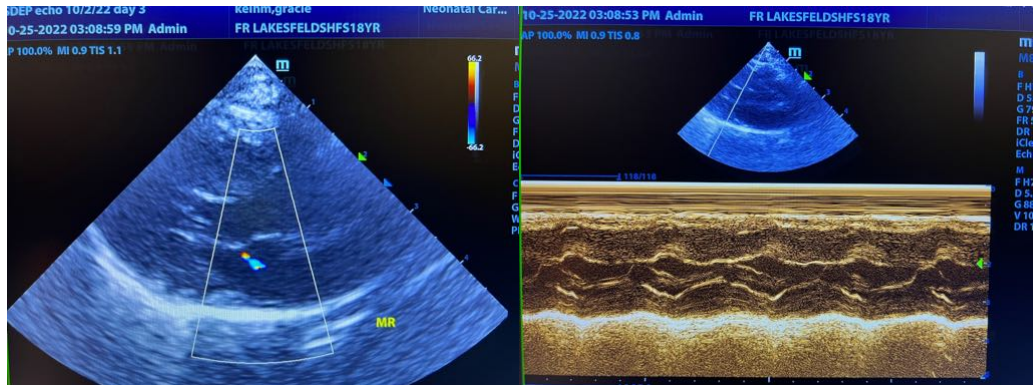
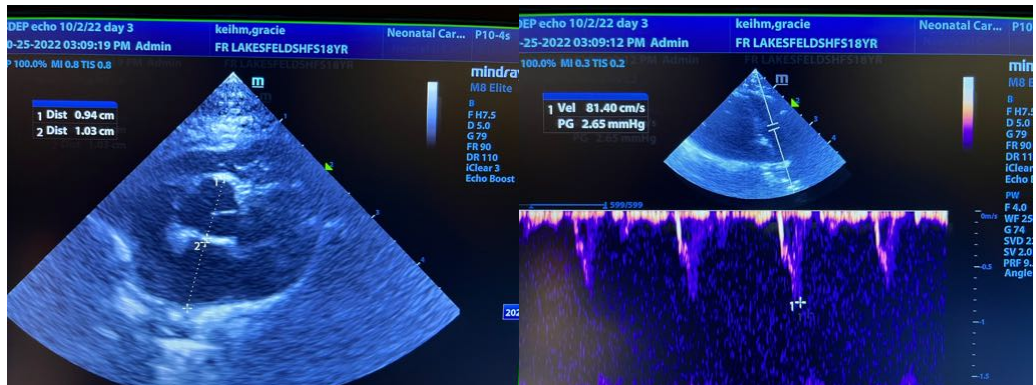
42125

DATE

10/25/22

INTERPRETATION OF THE FINDINGS & FURTHER RECOMMENDATIONS

There is no evidence of significant disease. No treatment is recommended. Blood pressure measurements and thyroid assessment are recommended.



The information and recommendations provided are based on the images presented by the referring veterinarian/sonographer. No evaluation can be communicated regarding pathology that was not visible in the image/video clips provided.

Thank you for this referral. If the clinical or image interpretation does not parallel your findings or if I can be of any further assistance please contact me.

Eric Lindquist, DMV, DABVP, Cert. IVUSS, CEO of SonoPath.com
Info@SonoPath.com