



**PATIENT**

Lucy Lantigua

**SPECIES**

Canine

**BREED**

Jack Russell Terrier

**SEX**

Spayed female

**AGE**

14 years

**WEIGHT**

13 lbs

**INTERPRETED BY**

Eric Lindquist, DMV,  
DABVP, Cert. IVUSS,  
CEO of SonoPath.com

**IMAGING PERFORMED BY**

Kelly Vazquez, CVT

**HOSPITAL NAME**

Bergen Passaic AH

**REFERRING VET**

Dr. Talik

**INVOICE**

42083

**DATE**

10/24/22

**PRESENTING CLINICAL SIGNS**

History: Elevated liver enzymes, chronic diarrhea/loose stool - loss of appetite. Current med: Denamarin 225 mgs.

**ULTRASONOGRAPHIC EXAMINATION OF THE ABDOMEN**

**Urinary System**

The **urinary bladder**, trigone, and pelvic urethra presented normal thicknesses and normal tone. The ureters were not visible which is normal. No uroliths or sediment were visualized and anechoic urine was present. No evidence of inflammatory or neoplastic changes was noted. Ureteral papillae were normal.

The **kidneys** revealed largely normal size and structure, corticomedullary definition and ratio (cortex 1/3 of medulla) were essentially maintained with some age-related loss of curvilinear patterns regarding the capsule and C/M junction. The cortices presented largely uniform texture with some increased echogenicity expected for his age patient. Medullary structure differed distinctly from that of the cortex and no evidence of pelvic dilation was present. The right kidney measured 4.44 cm. The left kidney measured 4.17 cm.

**Adrenal Glands**

Both **adrenal glands** were visualized and recognized as having normal shape, size, position and echogenicity for this breed. The phrenic vasculature, glandular echogenicity and detail were unremarkable. Capsule, cortex, and medullary definition were normal for this age patient. The right adrenal gland measured 0.42 cm. The left adrenal gland measured 0.45 cm.

**Spleen**

The **spleen** presented a smooth homogeneous parenchyma hyperechoic to liver and renal cortical parenchyma. The capsule was smooth without noticeable expansion or deviation from within the spleen or adjacent pathology. The splenic vasculature demonstrated normal volume without signs of congestion or thrombosis. No sonographic evidence of acute or chronic inflammatory, neoplastic, or infarctual changes was noted.

**Liver**

The **liver** revealed an expansive, mixed echogenic, puffy cloud type mass measuring 7.0 cm with multiple, other hypoechoic expansive disruptive masses up to 3.2 cm. The gallbladder was deviated and congested.

**Gastrointestinal**

Examination of the **gastrointestinal tract** revealed a stomach and intestine free of stasis, of normal wall thickness, acceptable curvilinear mural detail, and peristaltic activity. Small and large intestine



**PATIENT**

Lucy Lantigua

demonstrated normal luminal chyme and stool consistency respectively. No obstructive or overt infiltrative disease was noted. No associated abnormal lymphatic activity was noted.

**SPECIES**

Canine

**Pancreas**

The base and limbs of the **pancreas** were observed to be largely isoechoic to surrounding omental fat. Some parenchymal remodeling, however, with mild deviation from curvilinear normalcy was observed. Pancreatic duct and capsular irregularities were present consistent with age related changes. If pain upon imaging (+ Murphy sign) was present or if the patient is focally painful in subxiphoid palpation then low-grade smoldering chronic pancreatitis should be suspected.

**BREED**

Jack Russell Terrier

**SEX**

Spayed female

**Free Abdomen**

Free fluid was noted in the abdomen. This is likely paraneoplastic manifestation.

**AGE**

14 years

**ULTRASONOGRAPHIC FINDINGS**

Diffuse hepatic neoplasia and is non-resectable. Masses occupy the left and right liver.

**WEIGHT**

13 lbs

Aggressive, paraneoplastic effusion.

**INTERPRETATION OF THE FINDINGS & FURTHER RECOMMENDATIONS**

**INTERPRETED BY**

The prognosis is poor, this is likely carcinoma. FNA can be considered for further definition; however, humane euthanasia should be considered in this patient.

Eric Lindquist, DMV,  
DABVP, Cert. IVUSS,  
CEO of SonoPath.com

**IMAGING PERFORMED BY**

Kelly Vazquez, CVT

**HOSPITAL NAME**

Bergen Passaic AH

**REFERRING VET**

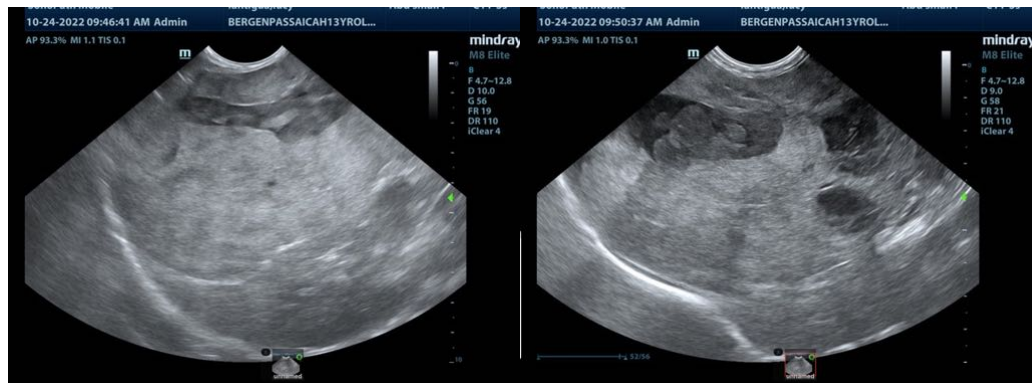Dr. Talik

**INVOICE**

42083

**DATE**

10/24/22





**PATIENT**

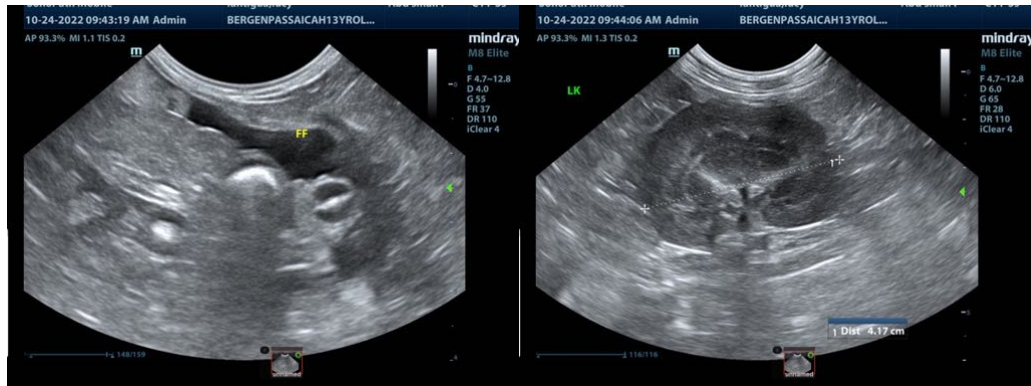Lucy Lantigua

**SPECIES**

Canine

**BREED**

Jack Russell Terrier



**SEX**

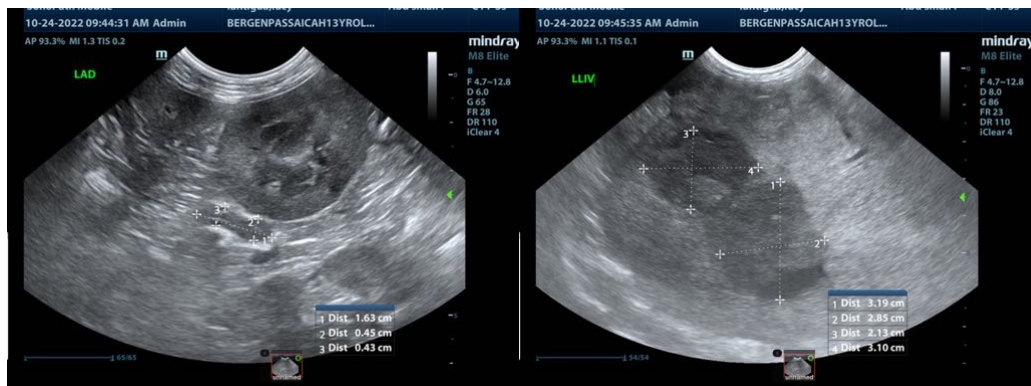
Spayed female

**AGE**

14 years

**WEIGHT**

13 lbs



**INTERPRETED BY**

Eric Lindquist, DMV,  
DABVP, Cert. IVUSS,  
CEO of SonoPath.com

**IMAGING PERFORMED BY**

Kelly Vazquez, CVT

**HOSPITAL NAME**

Bergen Passaic AH

**REFERRING VET**

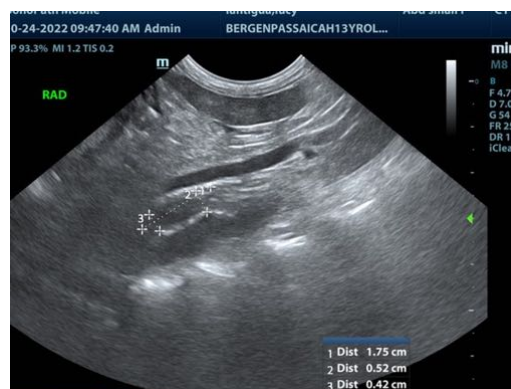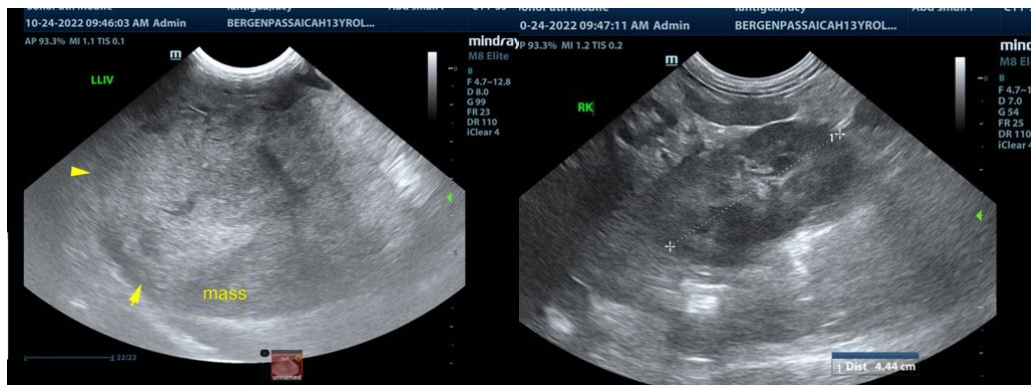
Dr. Talik

**INVOICE**

42083

**DATE**

10/24/22





**PATIENT**

Lucy Lantigua

The information and recommendations provided are based on the images presented by the referring veterinarian/sonographer. No evaluation can be communicated regarding pathology that was not visible in the image/video clips provided.

**SPECIES**

Canine

Thank you for this referral. If the clinical or image interpretation does not parallel your findings or if I can be of any further assistance please contact me.

**Eric Lindquist**, DMV, DABVP, Cert. IVUSS, CEO of SonoPath.com

**BREED**

Jack Russell Terrier

Info@SonoPath.com

**SEX**

Spayed female

**AGE**

14 years

**WEIGHT**

13 lbs

**INTERPRETED BY**

**Eric Lindquist**, DMV,  
DABVP, Cert. IVUSS,  
CEO of SonoPath.com

**IMAGING  
PERFORMED BY**

Kelly Vazquez, CVT

**HOSPITAL NAME**

Bergen Passaic AH

**REFERRING VET**

Dr. Talik

**INVOICE**

42083

**DATE**

10/24/22