SonoPath
Clinical Sonography & Telecytology

EDUCATIONAL TELECONSULTATION SERVICES™

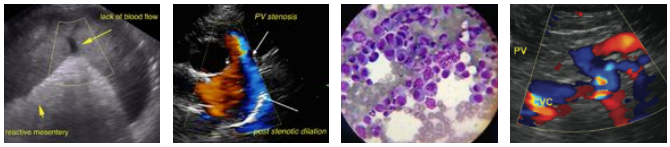

SonoPath.com™
1-800-838-4268 info@sonopath.com

PATIENT
Kicker Ramage

SPECIES
Canine

BREED
German Shorthair Pointer

SEX
Neutered male

AGE
10 years

WEIGHT
68 lbs

INTERPRETED BY
Eric Lindquist, DMV DABVP, Cert. IVUSS

IMAGING PERFORMED BY
Jessica Miller, RDMS

HOSPITAL NAME
Newton VH

REFERRING VET
Dr. Wyman-Greenwald

INVOICE
42072

DATE
10/24/22

PRESENTING CLINICAL SIGNS

History: 4 months inappetence, peritoneal effusion on ultrasound. BW pending. Cranial abdomen feels "full" on palpation.

ULTRASONOGRAPHIC EXAMINATION OF THE ABDOMEN

Urinary System

The **urinary bladder**, trigone, and pelvic urethra presented normal thicknesses and normal tone. The ureters were not visible which is normal. No uroliths or sediment were visualized and anechoic urine was present. No evidence of inflammatory or neoplastic changes was noted. Ureteral papillae were normal.

The **kidneys** revealed largely normal size and structure, corticomedullary definition and ratio (cortex 1/3 of medulla) were essentially maintained with some age-related loss of curvilinear patterns regarding the capsule and C/M junction. The cortices presented largely uniform texture with some increased echogenicity expected for his age patient. Medullary structure differed distinctly from that of the cortex and no evidence of pelvic dilation was present. The right kidney measured 8.1 cm.

Adrenal Glands

Both **adrenal glands** were visualized and recognized as having normal shape, size, position and echogenicity for this breed. The phrenic vasculature, glandular echogenicity and detail were unremarkable. Capsule, cortex, and medullary definition were normal for this age patient. The left adrenal gland measured 3.94 x 0.84 cm at the caudal pole and 0.78 cm at the cranial pole. The right adrenal gland measured 2.76 x 1.48 cm at the cranial pole and 0.65 cm at the caudal pole.

Spleen

The **spleen** was unremarkable with minor, heterogenous changes. The spleen was volume contracted.

Liver

The **liver** in this patient revealed an expansive, mixed, echogenic, complex 10.0 cm mass that was deriving from the left medial liver with nodular changes elsewhere in the liver. The liver mass appeared to be pedunculated. The heterogenous changes associated with the remainder of the liver appeared to be mildly to moderately disruptive. A separate, mixed echogenic right cranial liver nodule was noted with similar echotexture to that of the primary mass. However, nodular hyperplasia cannot be completely ruled out. The gallbladder presented acceptably thin walls with primarily anechoic content. The cystic and common bile ducts were normal. No pathological hepatic lymphadenopathy was evident.

Gastrointestinal

Examination of the **gastrointestinal tract** revealed a stomach and intestine free of stasis, of normal wall thickness, acceptable curvilinear mural detail, and peristaltic activity. Small and large intestine

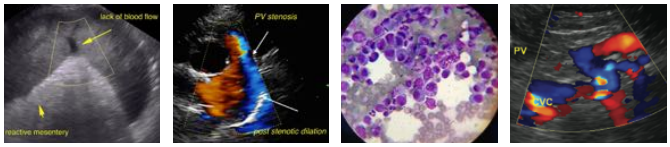

SonoPath.com™
1-800-838-4268 info@sonopath.com

PATIENT
Kicker Ramage

SPECIES
Canine

BREED
German Shorthair Pointer

SEX
Neutered male

AGE
10 years

WEIGHT
68 lbs

INTERPRETED BY
Eric Lindquist, DMV DABVP, Cert. IVUSS

IMAGING PERFORMED BY
Jessica Miller, RDMS

HOSPITAL NAME
Newton VH

REFERRING VET
Dr. Wyman-Greenwald

INVOICE
42072

DATE
10/24/22

demonstrated normal luminal chyme and stool consistency respectively. No obstructive or overt infiltrative disease was noted. No associated abnormal lymphatic activity was noted.

Pancreas

The base and limbs of the **pancreas** were observed to be largely isoechoic to surrounding omental fat. Pancreatic duct and capsular contour were acceptably normal and parenchyma respected normal curvilinear patterns. No overt evidence of active inflammatory or neoplastic disease was noted.

Free Abdomen

Free fluid was noted in the abdomen. I suspect hemorrhage or paraneoplastic effusion. Heterogenous omentum was noted.

ULTRASONOGRAPHIC FINDINGS

Pedunculated and possibly ruptured or torsed liver mass with other nodular changes and nodular omentum.

Normal GI.

INTERPRETATION OF THE FINDINGS & FURTHER RECOMMENDATIONS

I suspect hemorrhage or paraneoplastic effusion. Abdominal CT would be ideal in this patient to assess for potential surgical options; however, the nodular changes elsewhere in the liver are concerning. If the patient is not stable and abdominocentesis reveals hemorrhage then direct exploratory surgery is necessary. I suspect hepatic carcinoma.

ABOUT SONOPATH CT SERVICES:

SonoPath CT Services are offered at the SonoPath Imaging and Veterinary Education Center, 141 Main St (rt 206), Andover, New Jersey, a 20-minute drive west on route 80/206 North from the route 80/287 interchange/Parsippany, New Jersey. More information can be found at https://sonopath.com/services/sonopath-ct-services

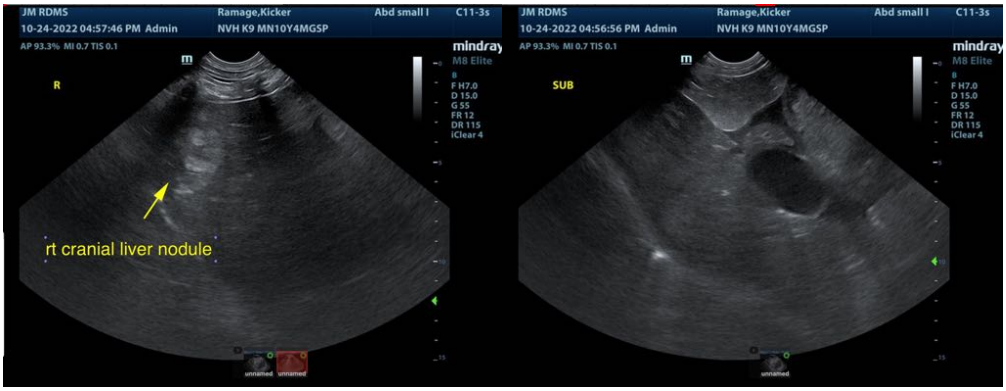

SonoPath
Clinical Sonography & Telecytology

EDUCATIONAL TELECONSULTATION SERVICES™

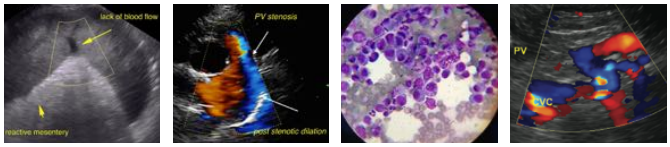

SonoPath.com™
1-800-838-4268 info@sonopath.com

PATIENT

Kicker Ramage

SPECIES

Canine

BREED

German Shorthair Pointer

SEX

Neutered male

AGE

10 years

WEIGHT

68 lbs

INTERPRETED BY

Eric Lindquist, DMV DABVP, Cert. IVUSS

IMAGING PERFORMED BY

Jessica Miller, RDMS

HOSPITAL NAME

Newton VH

REFERRING VET

Dr. Wyman-Greenwald

INVOICE

42072

DATE

10/24/22

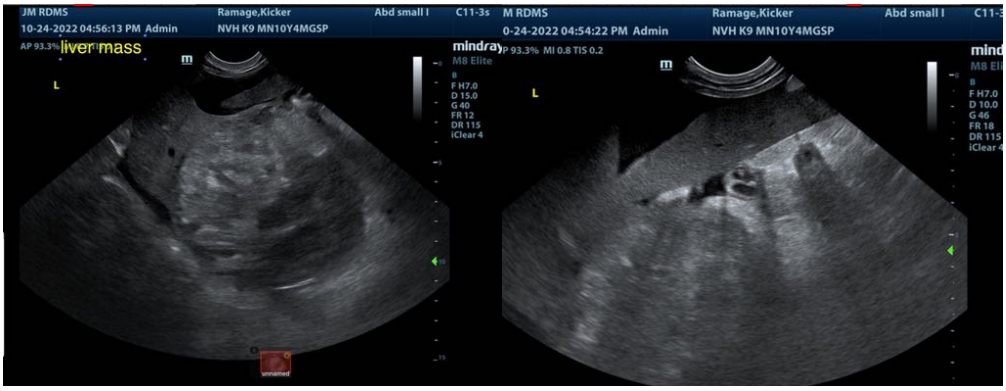

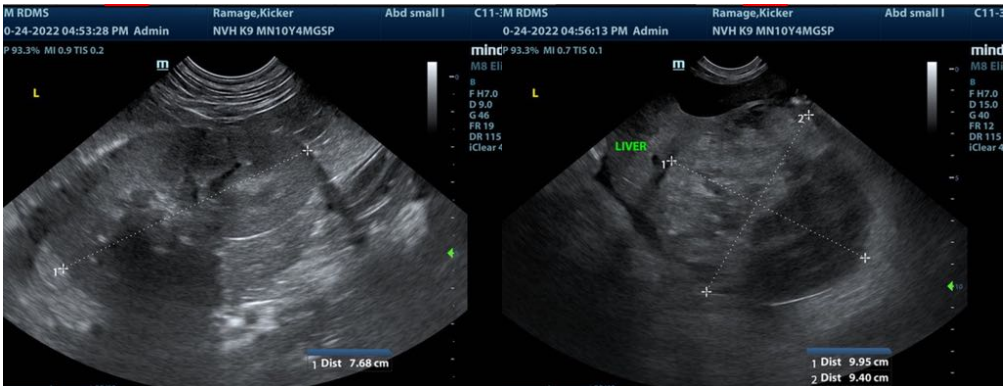

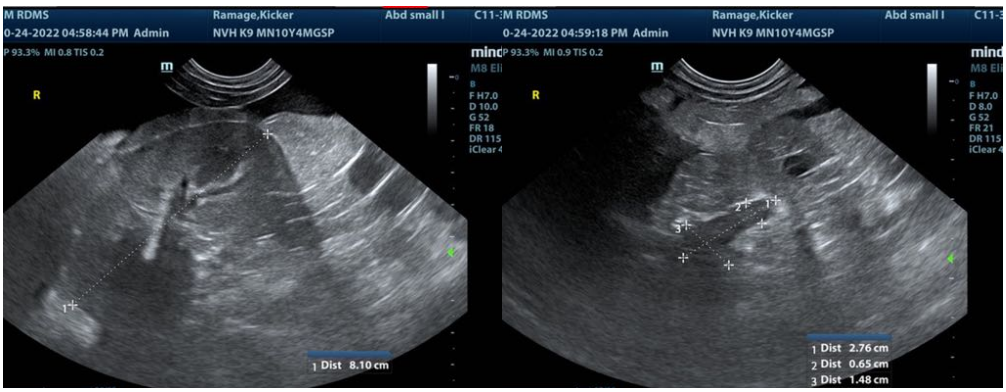

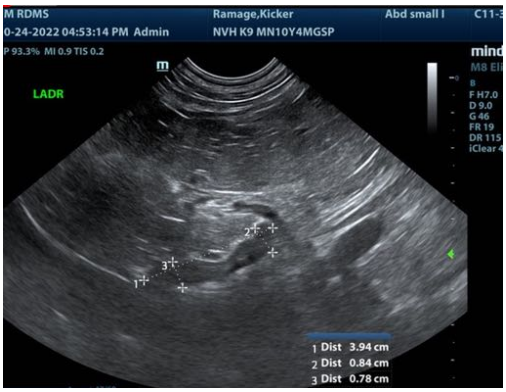

SonoPath
Clinical Sonography & Telecytology

EDUCATIONAL TELECONSULTATION SERVICES™

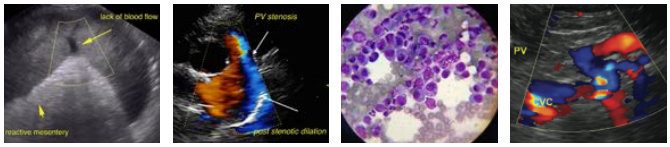

SonoPath.com™
1-800-838-4268 info@sonopath.com

PATIENT

Kicker Ramage

SPECIES

Canine

BREED

German Shorthair Pointer

SEX

Neutered male

AGE

10 years

WEIGHT

68 lbs

INTERPRETED BY

Eric Lindquist, DMV DABVP, Cert. IVUSS

IMAGING PERFORMED BY

Jessica Miller, RDMS

HOSPITAL NAME

Newton VH

REFERRING VET

Dr. Wyman-Greenwald

INVOICE

42072

DATE

10/24/22

The information and recommendations provided are based on the images presented by the referring veterinarian/sonographer. No evaluation can be communicated regarding pathology that was not visible in the image/video clips provided.

Thank you for this referral. If the clinical or image interpretation does not parallel your findings or if I can be of any further assistance please contact me.

Eric Lindquist, DMV, DABVP, Cert. IVUSS, CEO of SonoPath.com
info@SonoPath.com