



PATIENT

Bullseye Giordano

SPECIES

Canine

BREED

Cavalier King Charles

SEX

Neutered male

AGE

9 years

WEIGHT

26 lbs

PRESENTING CLINICAL SIGNS

History: Patient presents for new grade I/VI heart murmur. Patient needs a dental. BP mean systolic 162. No current meds.

Abnormal PE/Chem/CBC/UA Results: No current blood work. U/A: WNL, USG 1.043.

ULTRASONOGRAPHIC EXAMINATION OF THE HEART

The echocardiogram in this patient demonstrated normal **left atrial** size based on 3 different LA measurement methods. Chamber volumes and echogenicity were normal. The cranial and caudal **mitral** valve leaflets presented vegetative thickening consistent with endocardiosis. Doppler indicated measurable insufficiency. The **left ventricle** presented normal thicknesses with linear contour and was not dilated nor restricted. The **myocardium** presented normal echogenicity without subjective evidence of significant fibrotic or ischemic disease. **Contractility** of the ventricular walls was adequate and in normal range for this patient evidenced by the fractional shortening measurement and subjective evaluation of the different regions of the myocardium. The **left ventricular outflow** tract demonstrated normal laminar flow and subjective structural integrity. The **right atrium** and auricle revealed normal size, structure and content. No evidence of masses was noted or chamber overload. **Tricuspid** valvular assessment demonstrated adequate linear morphology. The **right ventricle** was of normal size (1/3 diameter of LV), chordae structure, myocardial echogenicity and thickness. Minor **pulmonic** insufficiency was noted at 2.0 m/sec. No visible **pericardial** or free pleura fluid was noted. No echographically detectable evidence of infiltrative disease was visible. The cranial **mediastinum and pericardial regions** were free of masses in the visible window.

INTERPRETED BY

Eric Lindquist, DMV,
DABVP, Cert. IVUSS,
CEO of SonoPath.com

IMAGING PERFORMED BY

Kelly Vazquez, CVT

HOSPITAL NAME

Parsippany AH

REFERRING VET

Dr. Dulude

INVOICE

40237

DATE

10/21/22

CANINE CARDIAC PARAMETERS	MR VMAX (m/s)	TR VMAX (m/s)	LA/AO (Boon method)	LA/AO (Heart Base; Swe)	FS (%)	EF (%)	EPSS (cm)
NORMAL PARAMETER	4.5-5.5	<2.7	1.3	<1.6	28-40	40-100	<0.6
PATIENT	6.0		1.0	1.2	31	61	0.25
CANINE CARDIAC PARAMETERS	HR (BPM)	AV VMAX (m/s)	PV MAX (m/s)	BODY WEIGHT	LA 2D short axis Base view (cm)	LVIDd Avg; 2D and m- mode short axis (cm)	LVIDs Avg; 2D and m- mode short axis (cm)
NORMAL PARAMETER	50-100	0.7-1.7	0.7-1.6	BELOW	BELOW	BELOW	BELOW
PATIENT	81	1.29	1.08	26 lbs	3.6 max	2.9	



PATIENT

Bullseye Giordano

ULTRASONOGRAPHIC FINDINGS

B1 valvular disease.

SPECIES

Canine

INTERPRETATION OF THE FINDINGS & FURTHER RECOMMENDATIONS

There was no evidence of volume overload.

BREED

Cavalier King Charles

The heart is stable without clinical disease. No overt contraindication for anesthesia of brief to moderate duration. I suggest Torbutrol premed, Propofol induction, Isoflo maintenance or similar protocol if anesthesia is desired. Blood pressure recommended if not already performed and target white coat negative systolic pressure of < 160 mmHg. If higher than this ACE-inhibitor is suggested to reach this level. Recheck echocardiogram is recommended in 6 months, earlier if murmur grade increases or clinical signs initiate.

SEX

Neutered male

AGE

9 years

WEIGHT

26 lbs

INTERPRETED BY

Eric Lindquist, DMV,
DABVP, Cert. IVUSS,
CEO of SonoPath.com

IMAGING PERFORMED BY

Kelly Vazquez, CVT

HOSPITAL NAME

Parsippany AH

REFERRING VET

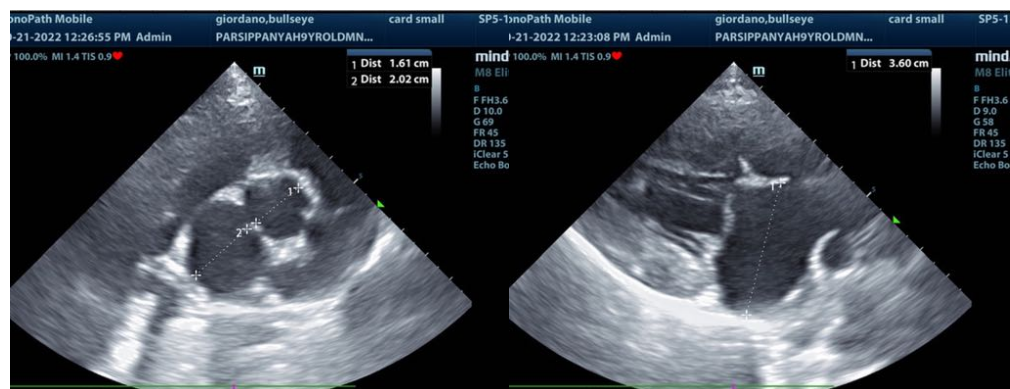
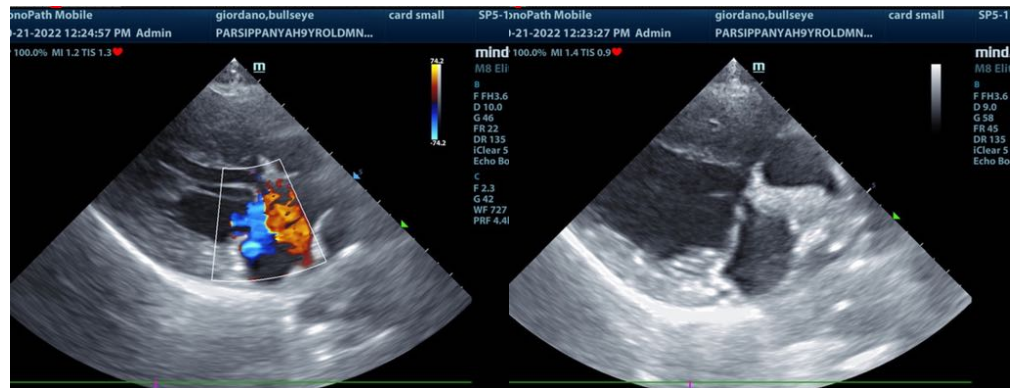
Dr. Dulude

INVOICE

40237

DATE

10/21/22





PATIENT

Bullseye Giordano

SPECIES

Canine

BREED

Cavalier King Charles

SEX

Neutered male

AGE

9 years

WEIGHT

26 lbs

INTERPRETED BY

Eric Lindquist, DMV,
DABVP, Cert. IVUSS,
CEO of SonoPath.com

**IMAGING
PERFORMED BY**

Kelly Vazquez, CVT

HOSPITAL NAME

Parsippany AH

REFERRING VET

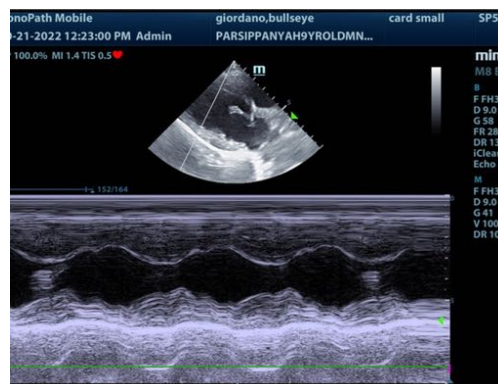
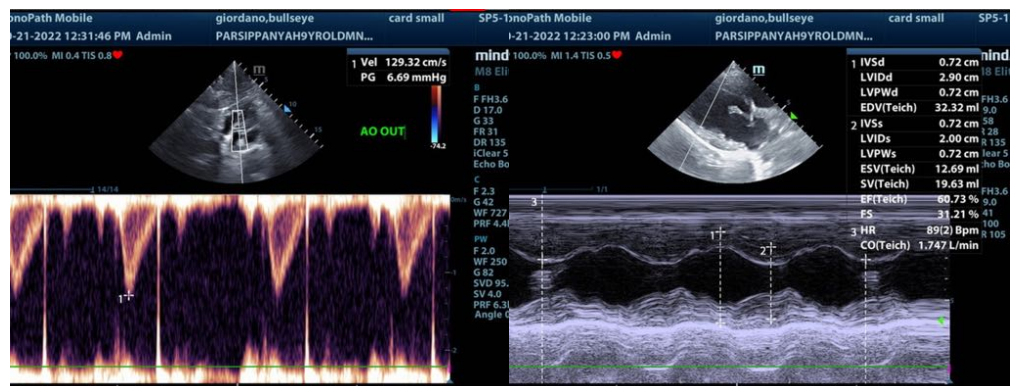
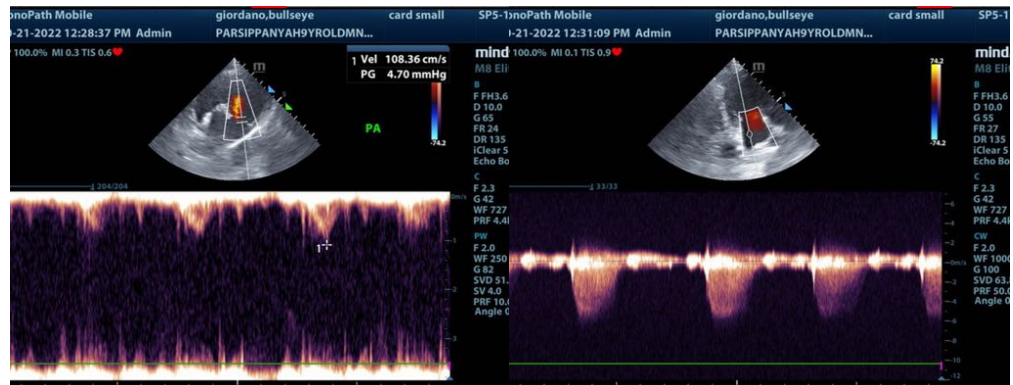
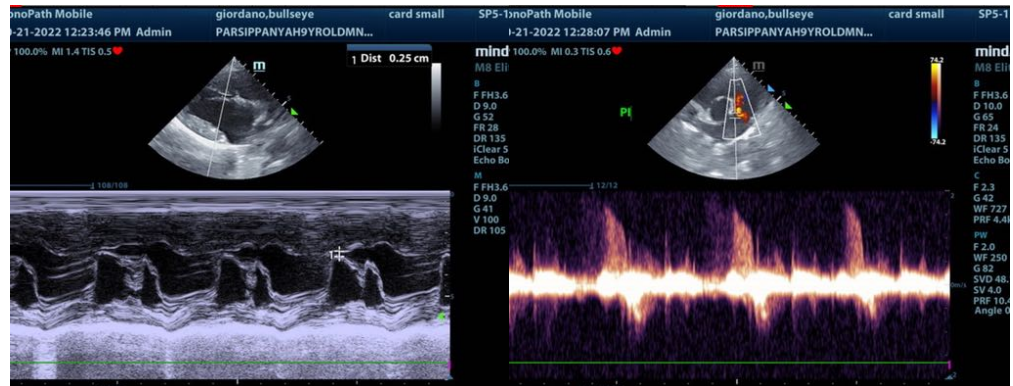
Dr. Dulude

INVOICE

40237

DATE

10/21/22





PATIENT

Bullseye Giordano

SPECIES

Canine

BREED

Cavalier King Charles

SEX

Neutered male

AGE

9 years

WEIGHT

26 lbs

INTERPRETED BY

Eric Lindquist, DMV,
DABVP, Cert. IVUSS,
CEO of SonoPath.com

**IMAGING
PERFORMED BY**

Kelly Vazquez, CVT

HOSPITAL NAME

Parsippany AH

REFERRING VET

Dr. Dulude

INVOICE

40237

DATE

10/21/22

The information and recommendations provided are based on the images presented by the referring veterinarian/sonographer. No evaluation can be communicated regarding pathology that was not visible in the image/video clips provided.

Thank you for this referral. If the clinical or image interpretation does not parallel your findings or if I can be of any further assistance please contact me.

Eric Lindquist, DMV, DABVP, Cert. IVUSS, CEO of SonoPath.com

Info@SonoPath.com