



PATIENT

Jahkri Emmerson

PRESENTING CLINICAL SIGNS

Chronic vomiting.

SPECIES

Feline

ULTRASONOGRAPHIC EXAMINATION OF THE ABDOMEN

Urinary System

BREED

Domestic Shorthair

The **urinary bladder**, trigone, and pelvic urethra presented normal thicknesses and normal tone. The ureters were not visible which is normal. No uroliths or sediment were visualized and anechoic urine was present. No evidence of inflammatory or neoplastic changes was noted. Ureteral papillae were normal.

SEX

Neutered male

The **kidneys** were slightly enlarged, yet uniform with mildly increased cortical echogenicity. There was no evidence of significant pathology. The left kidney measured 4.19 cm. The right kidney measured 4.92 cm.

AGE

10 years

Adrenal Glands

INTERPRETED BY

Eric Lindquist, DMV
DABVP, Cert. IVUSS

Both **adrenal glands** were visualized and recognized as having normal shape, size, position and echogenicity for this breed. The phrenic vasculature, glandular echogenicity and detail were unremarkable. Capsule, cortex, and medullary definition were normal for this age patient. Both adrenal glands measured 0.5 cm.

IMAGING PERFORMED BY

Eric Lindquist, DMV
DABVP, Cert. IVUSS

Spleen

The **spleen** presented a smooth homogeneous parenchyma hyperechoic to liver and renal cortical parenchyma. The capsule was smooth without noticeable expansion or deviation from within the spleen or adjacent pathology. The splenic vasculature demonstrated normal volume without signs of congestion or thrombosis. No sonographic evidence of acute or chronic inflammatory, neoplastic, or infarctual changes was noted.

HOSPITAL NAME

Franklin Lakes AH

Liver

REFERRING VET

Dr. Hudson

The **liver** images submitted revealed subjectively normal liver size, contour, and structure. Parenchymal echogenicity was naturally coarse and hypoechoic to the spleen. Vascular and biliary tracts were of normal volume with no evidence of congestion. The gallbladder presented acceptably thin walls with primarily anechoic content. The cystic and common bile ducts were normal. No pathological hepatic lymphadenopathy was evident. No overt structural evidence of inflammatory, infiltrative or regenerative pathology was evident.

INVOICE

40112

DATE

10/18/22

Gastrointestinal

The **gastrointestinal tract** revealed minor variable thickening and echogenic submucosal changes most consistent with low grade end result of chronic GI disease such as IBD and may be related to malassimilation of nutrients if any weight loss is present. No obvious neoplastic patterns were noted and luminal content as unremarkable.



PATIENT

Pancreas

Jahkri Emmerson

The base and limbs of the **pancreas** were observed to be largely isoechoic to surrounding omental fat. Pancreatic duct and capsular contour were acceptably normal and parenchyma respected normal curvilinear patterns. No overt evidence of active inflammatory or neoplastic disease was noted.

SPECIES

Feline

ULTRASONOGRAPHIC FINDINGS

BREED

Minor IBD GI pattern.

Domestic Shorthair

INTERPRETATION OF THE FINDINGS & FURTHER RECOMMENDATIONS

SEX

Neutered male

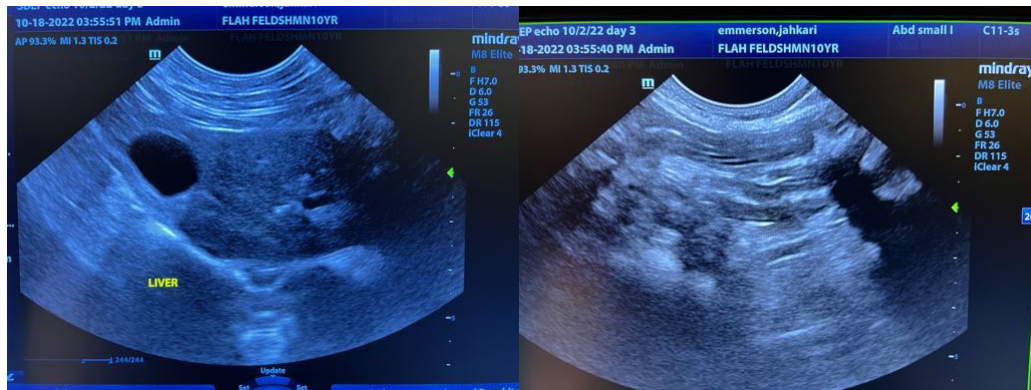
Underlying food intolerance, occult parasitism or structurally low-grade inflammatory bowel is all possible. Assessment of urinalysis is recommended to assess for any inflammatory sediment given the minor renal enlargement, yet structurally the kidneys appear unremarkable.

AGE

10 years

INTERPRETED BY

Eric Lindquist, DMV
DABVP, Cert. IVUSS

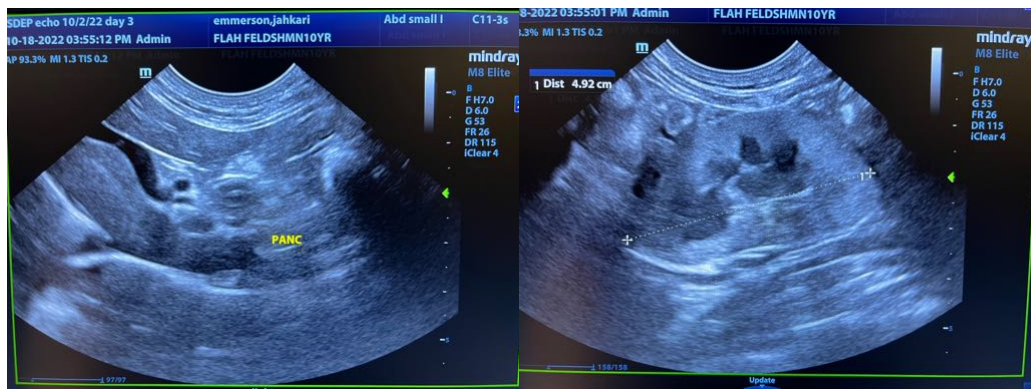


IMAGING PERFORMED BY

Eric Lindquist, DMV
DABVP, Cert. IVUSS

HOSPITAL NAME

Franklin Lakes AH



REFERRING VET

Dr. Hudson

INVOICE

40112

DATE

10/18/22



PATIENT

Jahkri Emmerson

SPECIES

Feline

BREED

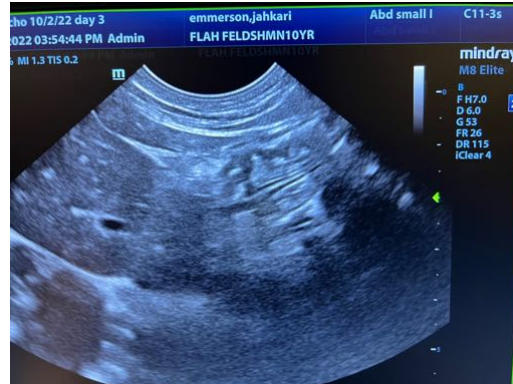Domestic Shorthair

SEX

Neutered male

AGE

10 years



The information and recommendations provided are based on the images presented by the referring veterinarian/sonographer. No evaluation can be communicated regarding pathology that was not visible in the image/video clips provided.

Thank you for this referral. If the clinical or image interpretation does not parallel your findings or if I can be of any further assistance please contact me.

INTERPRETED BY

Eric Lindquist, DMV
DABVP, Cert. IVUSS

Eric Lindquist, DMV, DABVP, Cert. IVUSS, CEO of SonoPath.com
Info@SonoPath.com

IMAGING PERFORMED BY

Eric Lindquist, DMV
DABVP, Cert. IVUSS

HOSPITAL NAME

Franklin Lakes AH

REFERRING VET

Dr. Hudson

INVOICE

40112

DATE

10/18/22