



**PATIENT**

Montaro Marshall

**SPECIES**

Canine

**BREED**

Boston Terrier

**SEX**

Intact male

**AGE**

1 year

**WEIGHT**

31 lbs

**INTERPRETED BY**

Eric Lindquist, DMV,  
DABVP, Cert. IVUSS,  
CEO of SonoPath.com

**IMAGING PERFORMED BY**

Kelly Vazquez, CVT

**HOSPITAL NAME**

Midland Park AH

**REFERRING VET**

Dr. Shokoff

**INVOICE**

42535

**DATE**

1/5/23

**PRESENTING CLINICAL SIGNS**

History: Patient presents for a history of persistently elevated ALT. Bile Acids test WNL (Pre & Post meal). R/O structural disease vs. open. No clinical issues. No current meds.

Abnormal PE/Chem/CBC/UA Results: ALT 183, ALT was 164 on 9/22.

**ULTRASONOGRAPHIC EXAMINATION OF THE ABDOMEN**

**Urinary System**

The **urinary bladder**, trigone, and pelvic urethra presented normal thicknesses and normal tone. The ureters were not visible which is normal. No uroliths or sediment were visualized and anechoic urine was present. No evidence of inflammatory or neoplastic changes was noted. Ureteral papillae were normal.

The testicles were imaged and found to be uniform with no evidence of pathology. The prostate was uniform and measured 1.6 cm.

The **kidneys** revealed normal size and structure, corticomedullary definition and ratio for this age. The cortices presented largely uniform texture with normal echogenic relationship to liver and spleen. Medullary structure differed distinctly from the cortex and no evidence of pelvic dilation was present.

The capsules were acceptably uniform without significant irregularities. The right kidney measured 5.45 cm. The left kidney measured 4.54 cm.

**Adrenal Glands**

Both **adrenal glands** were visualized and recognized as having normal shape, size, position and echogenicity for this breed. The phrenic vasculature, glandular echogenicity and detail were unremarkable. Capsule, cortex, and medullary definition were normal for this age patient. The right adrenal gland measured 1.52 x 1.06 cm at the cranial pole and 0.65 cm at the caudal pole. The left adrenal gland measured 2.17 x 0.46 cm at the caudal pole and 0.43 cm at the cranial pole.

**Spleen**

The **spleen** presented a smooth homogeneous parenchyma hyperechoic to liver and renal cortical parenchyma. The capsule was smooth without noticeable expansion or deviation from within the spleen or adjacent pathology. The splenic vasculature demonstrated normal volume without signs of congestion or thrombosis. No sonographic evidence of acute or chronic inflammatory, neoplastic, or infarctual changes was noted.

**Liver**

The **liver** was normal in size and contour with no evidence of intrahepatic or extrahepatic shunting. However, increased portal markings were noted. The portal vein to vena cava ratio was 1:1. The gallbladder presented acceptably thin walls with primarily anechoic content. The cystic and common bile ducts were normal. No pathological hepatic lymphadenopathy was evident. No overt structural evidence of inflammatory, infiltrative or regenerative pathology was evident.



**PATIENT**

**Gastrointestinal**

Montaro Marshall

Examination of the **gastrointestinal tract** revealed a stomach and intestine free of stasis, of normal wall thickness, acceptable curvilinear mural detail, and peristaltic activity. Small and large intestine demonstrated normal luminal chyme and stool consistency respectively. No obstructive or overt infiltrative disease was noted. No associated abnormal lymphatic activity was noted.

**SPECIES**

Canine

**BREED**

Boston Terrier

**Pancreas**

The base and limbs of the **pancreas** were observed to be largely isoechoic to surrounding omental fat. Pancreatic duct and capsular contour were acceptably normal and parenchyma respected normal curvilinear patterns. No overt evidence of active inflammatory or neoplastic disease was noted.

**SEX**

Intact male

**ULTRASONOGRAPHIC FINDINGS**

Non-specific low-grade inflammatory hepatopathy/likely reactive hepatopathy.

**AGE**

1 year

**INTERPRETATION OF THE FINDINGS & FURTHER RECOMMENDATIONS**

**WEIGHT**

31 lbs

FNA of the liver is indicated to assess inflammatory cell type, yet there was no evidence of neoplasia or portosystemic shunting.

**INTERPRETED BY**

Eric Lindquist, DMV, DABVP, Cert. IVUSS, CEO of SonoPath.com

The hepatic clinical sonographic presentation is most consistent with Reactive Hepatopathy which is the most common cause of liver enzyme elevation in dogs and cats. The presumption is that gut and other organ antigen stimuli may be causing a low-grade immune response through portal system with which the liver is reacting to causing low-grade enzyme elevations. US-guided FNA could be performed to assess if low grade lymphoplasmacytic inflammation is present that would support this theory. If FNA is performed, please ask the cytologist to emphasize the primary inflammatory cell type. Empirical treatment measures to address this issue can include diet change to hydrolyzed diet, probiotics, deworming, nutraceuticals (SAME, Actigall...), dental exam and cleaning, and potentially antibiotics such as Clavamox. Metronidazole and Tylosin have traditionally been utilized for this purpose but new studies show that both these antibiotics can disrupt the normal intestinal bacterial flora (intestinal dysbiosis) for weeks and up to 4-6 months. Therefore, Metronidazole and Tylosin should be utilized as a last resort if other efforts have not been effective and sonographic organ appearance remains benign.

**IMAGING PERFORMED BY**

Kelly Vazquez, CVT

**HOSPITAL NAME**

Midland Park AH

**REFERRING VET**

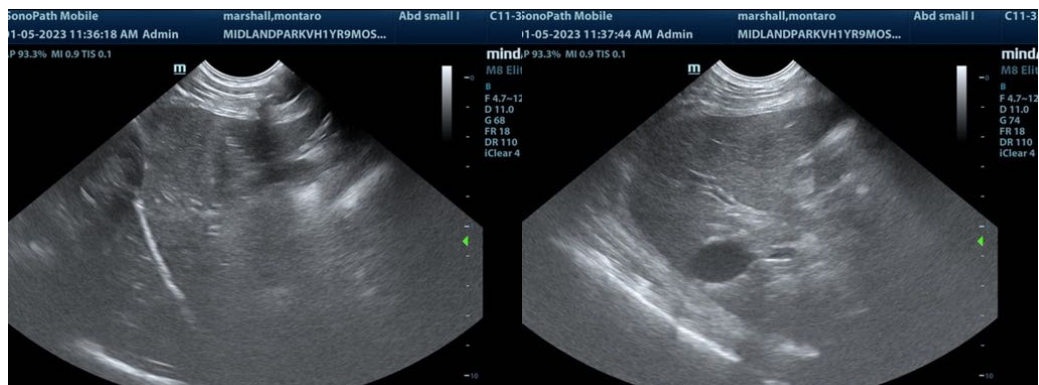
Dr. Shokoff

**INVOICE**

42535

**DATE**

1/5/23





**PATIENT**

Montaro Marshall

**SPECIES**

Canine

**BREED**

Boston Terrier

**SEX**

Intact male

**AGE**

1 year

**WEIGHT**

31 lbs

**INTERPRETED BY**

Eric Lindquist, DMV,  
DABVP, Cert. IVUSS,  
CEO of SonoPath.com

**IMAGING PERFORMED BY**

Kelly Vazquez, CVT

**HOSPITAL NAME**

Midland Park AH

**REFERRING VET**

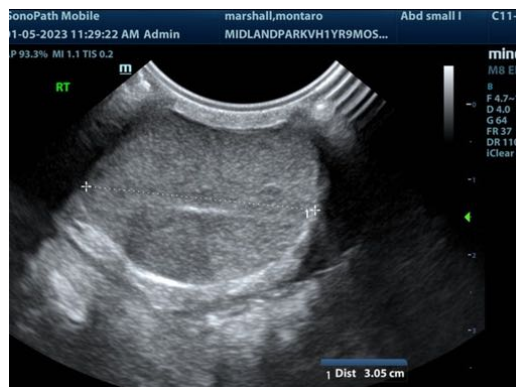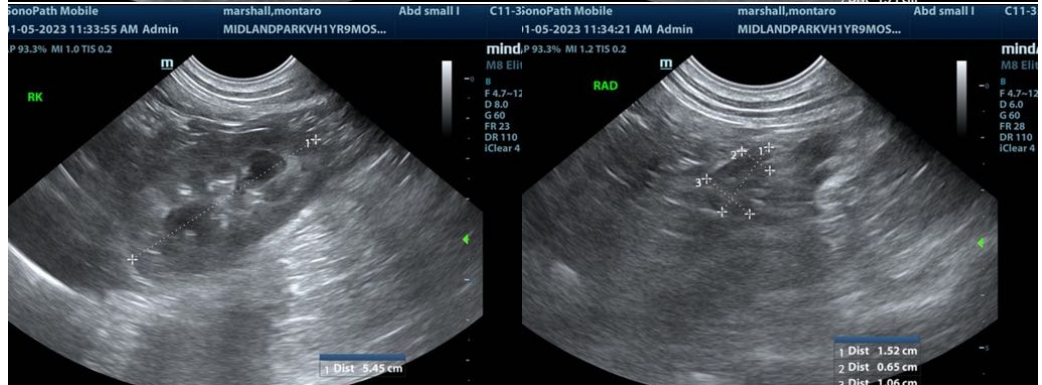
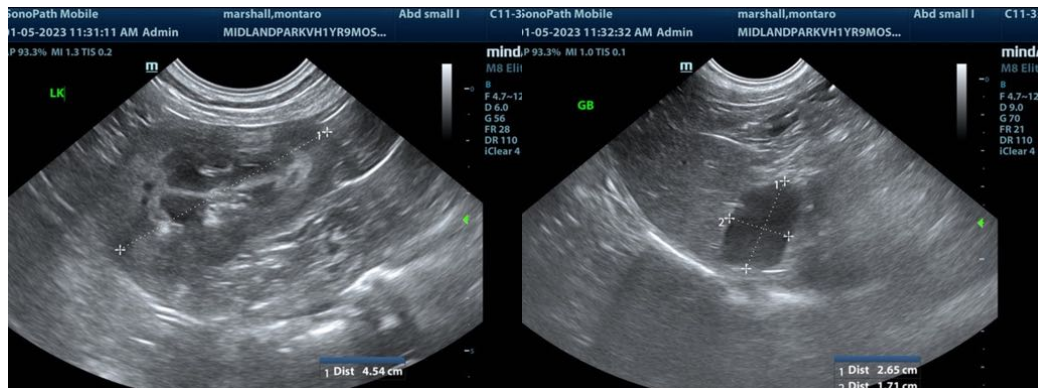
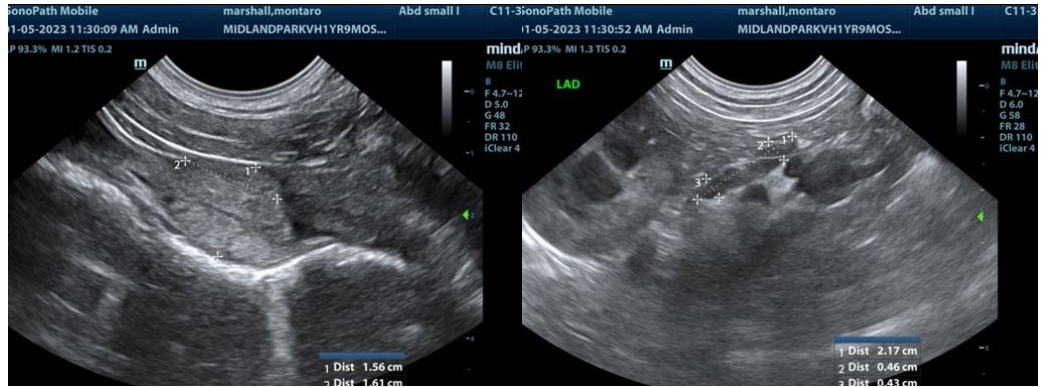
Dr. Shokoff

**INVOICE**

42535

**DATE**

1/5/23





**PATIENT**

Montaro Marshall

The information and recommendations provided are based on the images presented by the referring veterinarian/sonographer. No evaluation can be communicated regarding pathology that was not visible in the image/video clips provided.

**SPECIES**

Canine

Thank you for this referral. If the clinical or image interpretation does not parallel your findings or if I can be of any further assistance please contact me.

**BREED**

Boston Terrier

**Eric Lindquist**, DMV, DABVP, Cert. IVUSS, CEO of SonoPath.com

Info@SonoPath.com

**SEX**

Intact male

**AGE**

1 year

**WEIGHT**

31 lbs

**INTERPRETED BY**

**Eric Lindquist**, DMV,  
DABVP, Cert. IVUSS,  
CEO of SonoPath.com

**IMAGING  
PERFORMED BY**

Kelly Vazquez, CVT

**HOSPITAL NAME**

Midland Park AH

**REFERRING VET**

Dr. Shokoff

**INVOICE**

42535

**DATE**

1/5/23