



PATIENT

Lexi Alexander

SPECIES

Canine

BREED

Pomeranian

SEX

Spayed female

AGE

9 years

WEIGHT

10.5 lbs

INTERPRETED BY

Eric Lindquist, DMV,
DABVP, Cert. IVUSS,
CEO of SonoPath.com

IMAGING PERFORMED BY

Kelly Vazquez, CVT

HOSPITAL NAME

All Creatures AH
Denville

REFERRING VET

Dr. Mitrovic

PRESENTING CLINICAL SIGNS

History: Patient presents for anorexia, lethargy, and some vomiting. PE found bradycardia 52 BPM, with irregular heart beats. Radiographs show cardiomegaly. No reported current meds.

ULTRASONOGRAPHIC EXAMINATION OF THE HEART

The echocardiogram in this patient demonstrated normal **left atrial** size based on 3 separate methods of LA evaluation. Trivial **mitral** valve insufficiency was present, yet not clinically significant. The **left ventricle** presented normal thicknesses with linear contour and was not dilated nor restricted. The **myocardium** presented normal echogenicity without subjective evidence of significant fibrotic or ischemic disease. **Aortic outflow** velocity was excessive, yet likely compensatory owing to the arrhythmia. Significant bradyarrhythmia was noted with a bigeminy type pattern. Minor volume overload was noted in the **right atrium**. **Tricuspid** insufficiency was present. During systole the contractility appeared adequate. The **right ventricle** was of normal size (1/3 diameter of LV), chordae structure, myocardial echogenicity and thickness. Minor **pulmonic** insufficiency was also noted. No visible **pericardial** or free pleura fluid was noted. The cranial **mediastinum and pericardial and extra-cardiac regions** were free of masses in the visible window. The hepatic veins and vena cava were dilated in this patient. The vena cava measured 1.26 cm in width. The passive congestion is likely owing to bradyarrhythmia.

CANINE CARDIAC PARAMETERS	MR VMAX (m/s)	TR VMAX (m/s)	LA/AO (Boon method)	LA/AO (Heart Base)	FS (%)	EF (%)	EPSS (cm)
NORMAL PARAMETER	4.5-5.5	<2.7	1.3	<1.6	28-40	40-100	<0.6
PATIENT			1.3	1.6	58	96	NM
CANINE CARDIAC PARAMETERS	HR (BPM)	AV VMAX (m/s)	PV MAX (m/s)	BODY WEIGHT	LA (2D short axis Base view) (cm)	LVIDd (Avg; 2D and m-mode short axis) (cm)	LVIDs (Avg; 2D and m-mode short axis) (cm)
NORMAL PARAMETER	50-100	0.7-1.7	0.7-1.6	BELOW	BELOW	BELOW	BELOW
PATIENT		2.95	2.0	10.5 lbs	2.47 max	3.52	

ULTRASONOGRAPHIC FINDINGS

Severe bradyarrhythmia with mitral and tricuspid insufficiency.

INVOICE

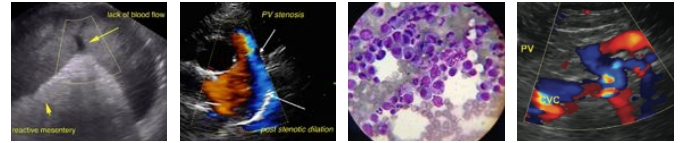
42541

DATE

1/5/23

INTERPRETATION OF THE FINDINGS & FURTHER RECOMMENDATIONS

STAT EKG is indicated. I suspect heart block. Depending upon EKG findings a pace maker may be



PATIENT

necessary in this patient.

Lexi Alexander

SPECIES

Canine

BREED

Pomeranian

SEX

Spayed female

AGE

9 years

WEIGHT

10.5 lbs

INTERPRETED BY

Eric Lindquist, DMV,
DABVP, Cert. IVUSS,
CEO of SonoPath.com

IMAGING PERFORMED BY

Kelly Vazquez, CVT

HOSPITAL NAME

All Creatures AH
Denville

REFERRING VET

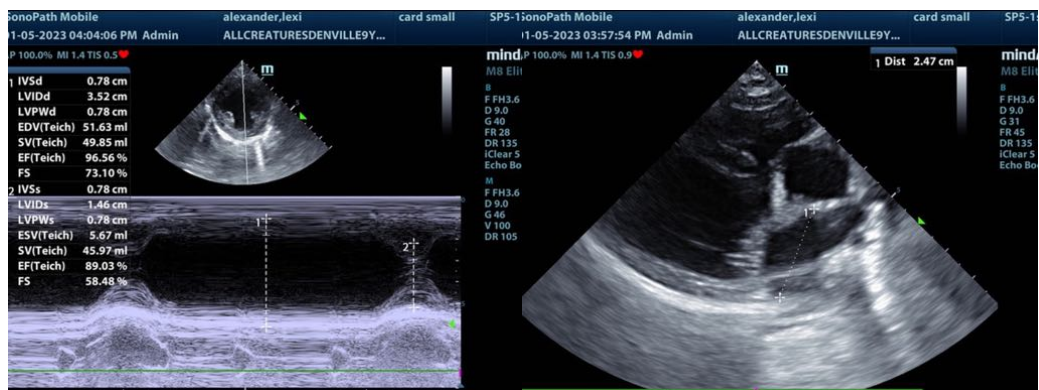
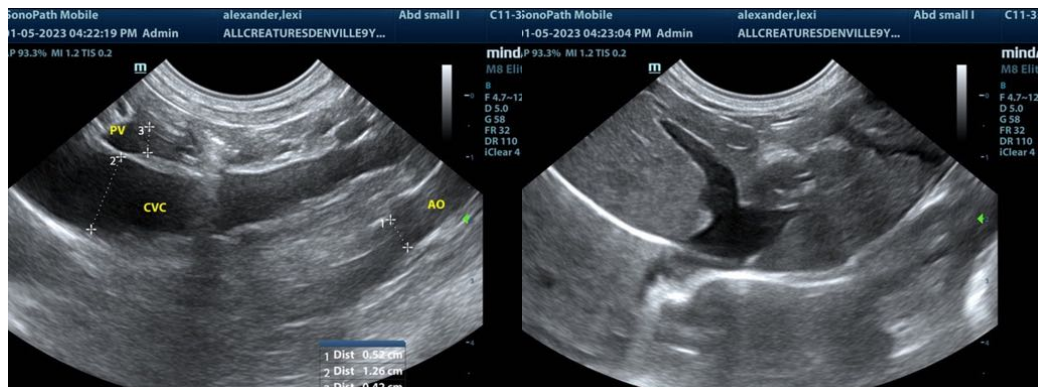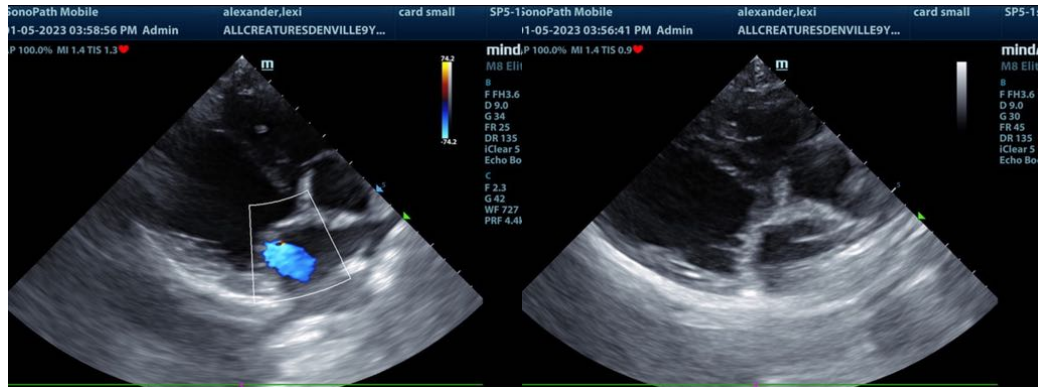
Dr. Mitrovic

INVOICE

42541

DATE

1/5/23





PATIENT

Lexi Alexander

SPECIES

Canine

BREED

Pomeranian

SEX

Spayed female

AGE

9 years

WEIGHT

10.5 lbs

INTERPRETED BY

Eric Lindquist, DMV,
DABVP, Cert. IVUSS,
CEO of SonoPath.com

IMAGING PERFORMED BY

Kelly Vazquez, CVT

HOSPITAL NAME

All Creatures AH
Denville

REFERRING VET

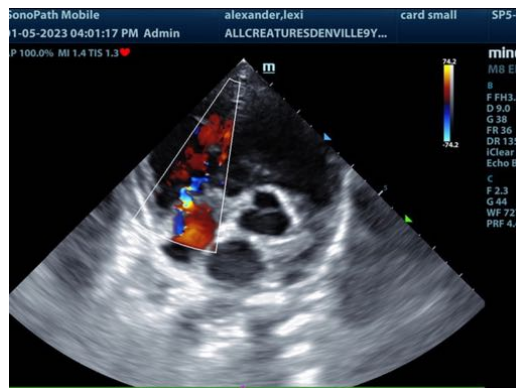
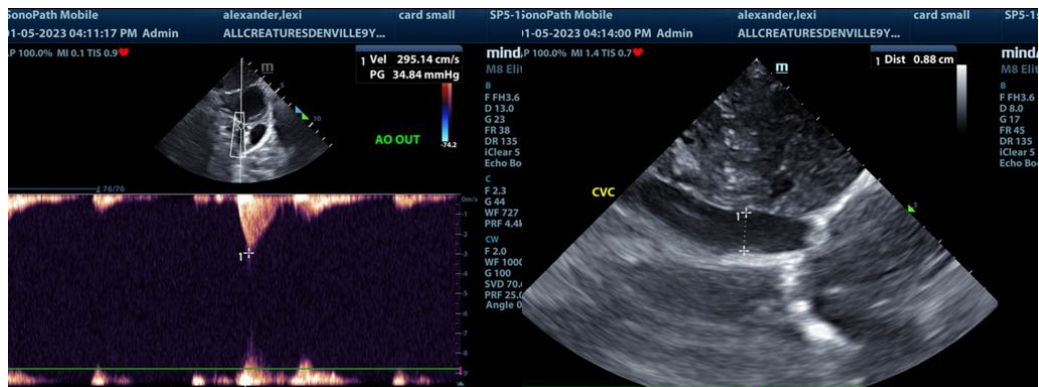
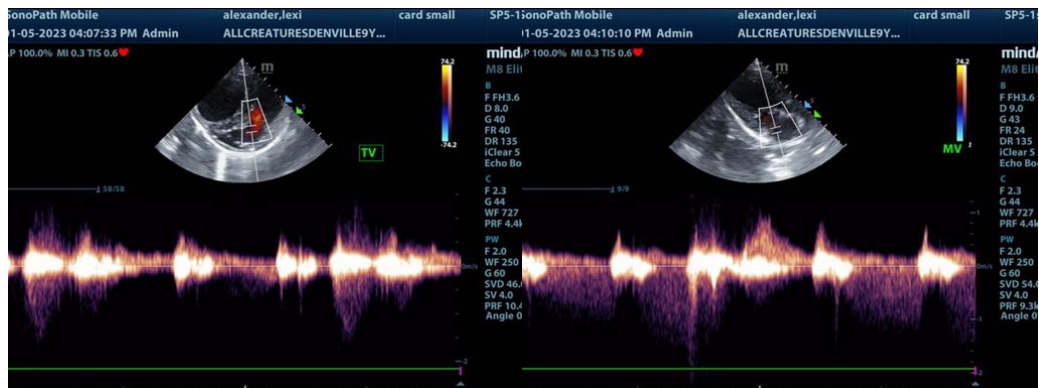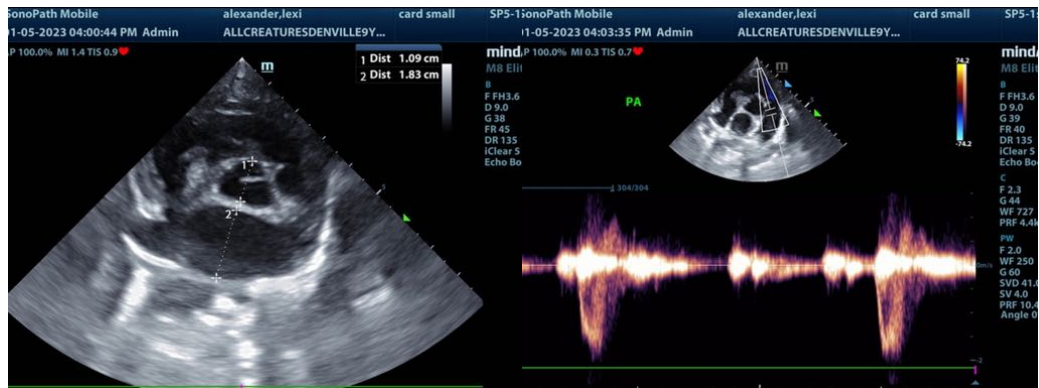
Dr. Mitrovic

INVOICE

42541

DATE

1/5/23





PATIENT

Lexi Alexander

The information and recommendations provided are based on the images presented by the referring veterinarian/sonographer. No evaluation can be communicated regarding pathology that was not visible in the image/video clips provided.

SPECIES

Canine

Thank you for this referral. If the clinical or image interpretation does not parallel your findings or if I can be of any further assistance please contact me.

Eric Lindquist, DMV, DABVP, Cert. IVUSS, CEO of SonoPath.com

BREED

Pomeranian

Info@SonoPath.com

SEX

Spayed female

AGE

9 years

WEIGHT

10.5 lbs

INTERPRETED BY

Eric Lindquist, DMV,
DABVP, Cert. IVUSS,
CEO of SonoPath.com

**IMAGING
PERFORMED BY**

Kelly Vazquez, CVT

HOSPITAL NAME

All Creatures AH
Denville

REFERRING VET

Dr. Mitrovic

INVOICE

42541

DATE

1/5/23