


PATIENT

Jax Vandervoort

PRESENTING CLINICAL SIGNS

History: Last echo performed on 8/22/22 - cardiomegaly - coughing more than usual. Current meds: Pimobendan & Benazepril.

SPECIES

Canine

ULTRASONOGRAPHIC EXAMINATION OF THE HEART
BREED

Border Collie

The cardiac presentation revealed mild improvement regarding approximately similar volume parameters to the prior echocardiogram. Contractility was adequate. The cranial and caudal mitral valve leaflets presented vegetative thickening consistent with endocardiosis. Doppler indicated measurable insufficiency. Mitral insufficiency was moderate to severe with complete filling of the left atrium. Prolapse of the anterior mitral valve leaflet was noted. Tricuspid insufficiency was also noted. There was no pericardial or pleural effusion or mass in the extracardiac space noted. However, residual left atrial and left ventricular dilation appeared to be present.

SEX

Neutered male

AGE

9 years

WEIGHT

63.1 lbs

CANINE CARDIAC PARAMETERS	MR VMAX (m/s)	TR VMAX (m/s)	LA/AO (Boon method)	LA/AO (Heart Base)	FS (%)	EF (%)	EPSS (cm)
NORMAL PARAMETER	4.5-5.5	<2.7	1.3	<1.6	28-40	40-100	<0.6
PATIENT	6.0	2.8	NM	1.8	30	58	0.36
CANINE CARDIAC PARAMETERS	HR (BPM)	AV VMAX (m/s)	PV MAX (m/s)	BODY WEIGHT	LA 2D short axis Base view (cm)	LVIDd Avg; 2D and m- mode short axis (cm)	LVIDs Avg; 2D and m- mode short axis (cm)
NORMAL PARAMETER	50-100	0.7-1.7	0.7-1.6	BELOW	BELOW	BELOW	BELOW
PATIENT	105	1.39	1.13	63.1 lbs	5.8 max	4.61	

INTERPRETED BY

 Eric Lindquist, DMV,
 DABVP, Cert. IVUSS,
 CEO of SonoPath.com

**IMAGING
PERFORMED BY**

Kelly Vazquez, CVT

HOSPITAL NAME

Legacy AH

ULTRASONOGRAPHIC FINDINGS

Mitral and tricuspid insufficiency.

Residual left atrial and left ventricular dilation was noted.

However, overall there was mild improvement since the prior sonogram.

REFERRING VET

Dr. Pontenzone

INVOICE

42538

DATE

1/5/23

INTERPRETATION OF THE FINDINGS & FURTHER RECOMMENDATIONS

Given the cough I recommend adding Spironolactone at 1-2 mg/kg b.i.d., Lasix at 1-2 mg/kg b.i.d. and reassessment of the clinical signs. Recheck echocardiogram is recommended in 3-6 months depending upon clinical progression or stabilization. Consideration to primary respiratory protocol may also be valid in this patient. An argument could be made that the cough may be owing to main stem bronchus impingement from left atrial enlargement; however, primary respiratory disease may also be playing a role depending upon radiographic findings. Bronchodilator and broad spectrum respiratory antibiotic



PATIENT

may be appropriate.

Jax Vandervoort

SPECIES

Canine

BREED

Border Collie

SEX

Neutered male

AGE

9 years

WEIGHT

63.1 lbs

INTERPRETED BY

Eric Lindquist, DMV,
DABVP, Cert. IVUSS,
CEO of SonoPath.com

IMAGING PERFORMED BY

Kelly Vazquez, CVT

HOSPITAL NAME

Legacy AH

REFERRING VET

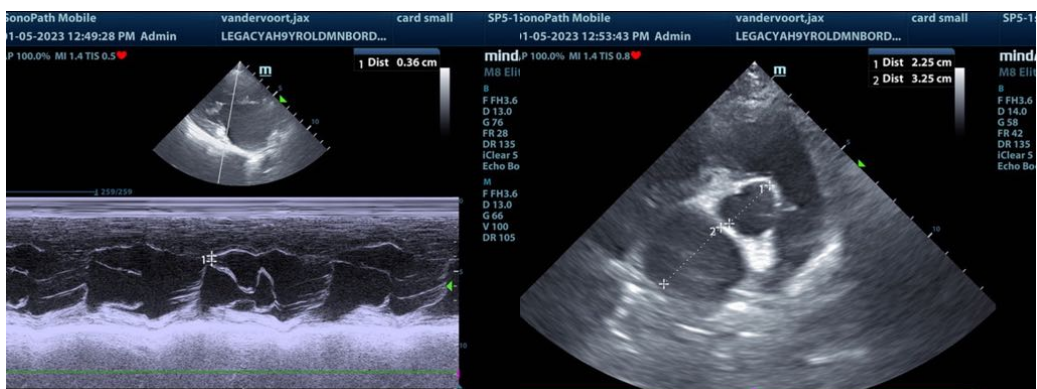
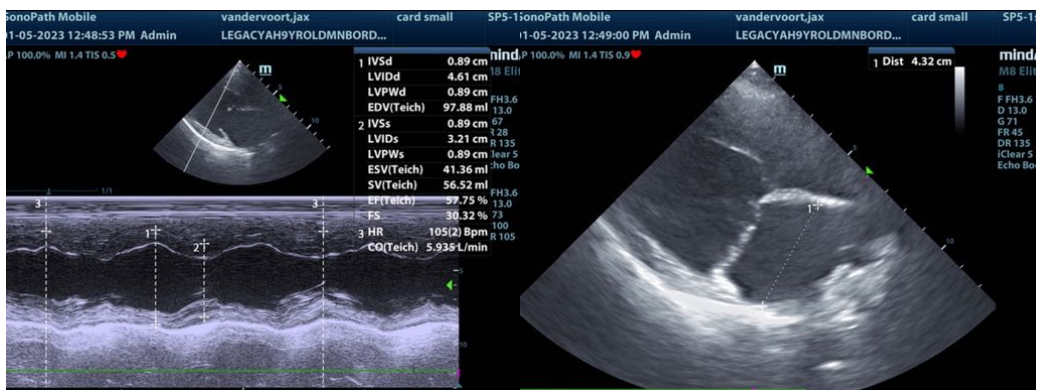
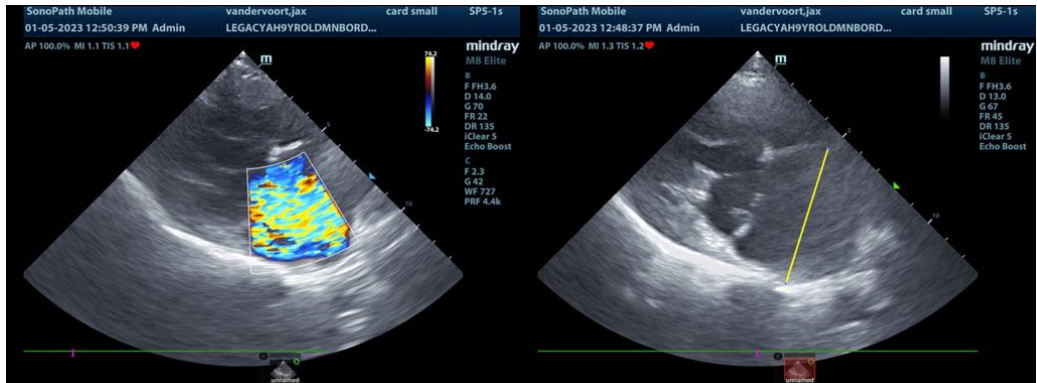
Dr. Pontenzone

INVOICE

42538

DATE

1/5/23





PATIENT

Jax Vandervoort

SPECIES

Canine

BREED

Border Collie

SEX

Neutered male

AGE

9 years

WEIGHT

63.1 lbs

INTERPRETED BY

Eric Lindquist, DMV,
DABVP, Cert. IVUSS,
CEO of SonoPath.com

IMAGING PERFORMED BY

Kelly Vazquez, CVT

HOSPITAL NAME

Legacy AH

REFERRING VET

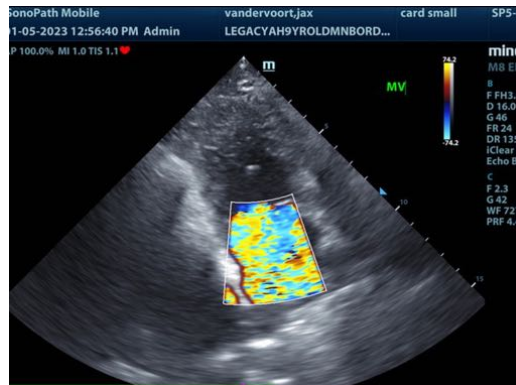
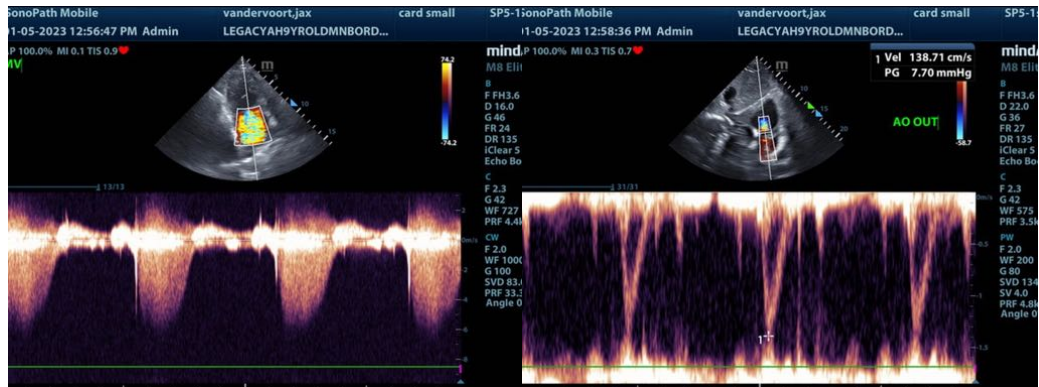
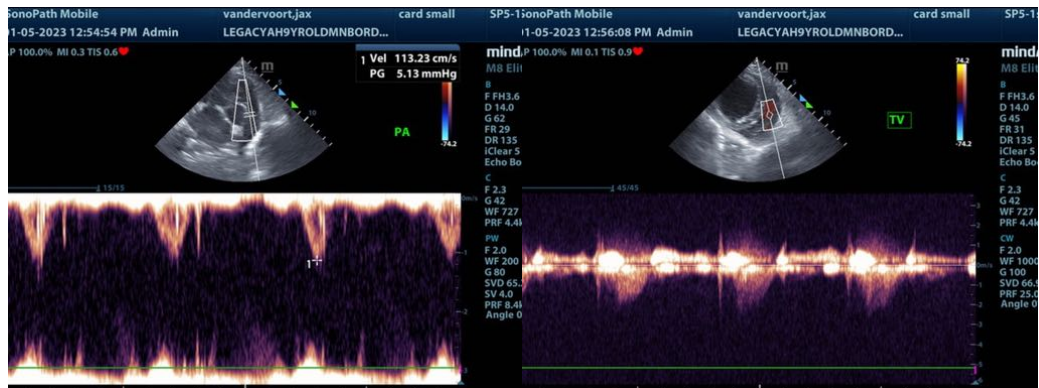
Dr. Pontenzone

INVOICE

42538

DATE

1/5/23



The information and recommendations provided are based on the images presented by the referring veterinarian/sonographer. No evaluation can be communicated regarding pathology that was not visible in the image/video clips provided.

Thank you for this referral. If the clinical or image interpretation does not parallel your findings or if I can be of any further assistance please contact me.

Eric Lindquist, DMV, DABVP, Cert. IVUSS, CEO of SonoPath.com

Info@SonoPath.com