



PATIENT

Gus Tanis

PRESENTING CLINICAL SIGNS

2History: Follow up echo, last one performed on 1/10/22. Checking for any progression of cardiac disease - coughing.

SPECIES

Canine

ULTRASONOGRAPHIC EXAMINATION OF THE HEART

BREED

Puggle

The echocardiogram in this patient demonstrated normal **left atrial** size based on 3 separate methods of LA evaluation. **Mitral** valve insufficiency was noted at 5.5 m/sec. The **left ventricle** presented normal thicknesses with linear contour and was not dilated nor restricted. The **myocardium** presented normal echogenicity without subjective evidence of significant fibrotic or ischemic disease. **Contractility** of the ventricular walls was adequate and in normal range for this patient evidenced by the fractional shortening measurement and subjective evaluation of the different regions of the myocardium. The **left ventricular outflow** tract demonstrated normal laminar flow and subjective structural integrity. The **right atrium** and auricle revealed normal size, structure and content. No evidence of masses was noted. **Tricuspid** valvular assessment demonstrated adequate linear morphology and kinesis. The **right ventricle** was of normal size (1/3 diameter of LV), chordae structure, myocardial echogenicity and thickness. **Pulmonary outflow** tract assessment revealed normal valve structure, laminar flow, and diameter (approx.1:1 pa/ao ratio). No visible **pericardial** or free pleura fluid was noted. The cranial **mediastinum and pericardial and extra-cardiac regions** were free of masses in the visible window.

SEX

Neutered male

AGE

12 years

WEIGHT

61.8 lbs

INTERPRETED BY

Eric Lindquist, DMV, DABVP, Cert. IVUSS, CEO of SonoPath.com

IMAGING PERFORMED BY

Kelly Vazquez, CVT

HOSPITAL NAME

Legacy AH

REFERRING VET

Dr. Pontenzone

INVOICE

42537

DATE

1/5/23

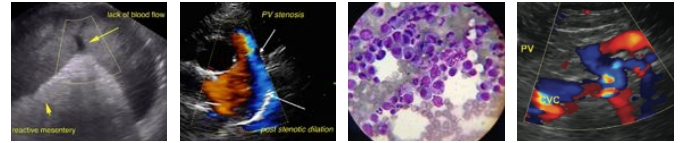
CANINE CARDIAC PARAMETERS	MR VMAX (m/s)	TR VMAX (m/s)	LA/AO (Boon method)	LA/AO (Heart Base; Swe)	FS (%)	EF (%)	EPSS (cm)
NORMAL PARAMETER	4.5-5.5	<2.7	1.3	<1.6	28-40	40-100	<0.6
PATIENT	5.5		1.1	1.3	26	53	NM
CANINE CARDIAC PARAMETERS	HR (BPM)	AV VMAX (m/s)	PV MAX (m/s)	BODY WEIGHT	LA (2D short axis Base view) (cm)	LVIDd (Avg; 2D and m-mode short axis) (cm)	LVIDs (Avg; 2D and m-mode short axis) (cm)
NORMAL PARAMETER	50-100	0.7-1.7	0.7-1.6	BELOW	BELOW	BELOW	BELOW
PATIENT	126	1.3	1.21	61.8 lbs	3.27	2.64	

ULTRASONOGRAPHIC FINDINGS

Stage B1 valvular disease. The mitral insufficiency was fairly mild with an eccentric jet.

INTERPRETATION OF THE FINDINGS & FURTHER RECOMMENDATIONS

The cough is non-cardiogenic in this patient.



PATIENT

Gus Tanis

The heart is stable without clinical disease. No overt contraindication for anesthesia of brief to moderate duration. I suggest Torbutrol premed, Propofol induction, Isoflor maintenance or similar protocol if anesthesia is desired. Blood pressure recommended if not already performed and target white coat negative systolic pressure of < 160 mmHg. If higher than this ACE-inhibitor is suggested to reach this level. Recheck echocardiogram is recommended in 6 months, earlier if murmur grade increases or clinical signs initiate.

SPECIES

Canine

BREED

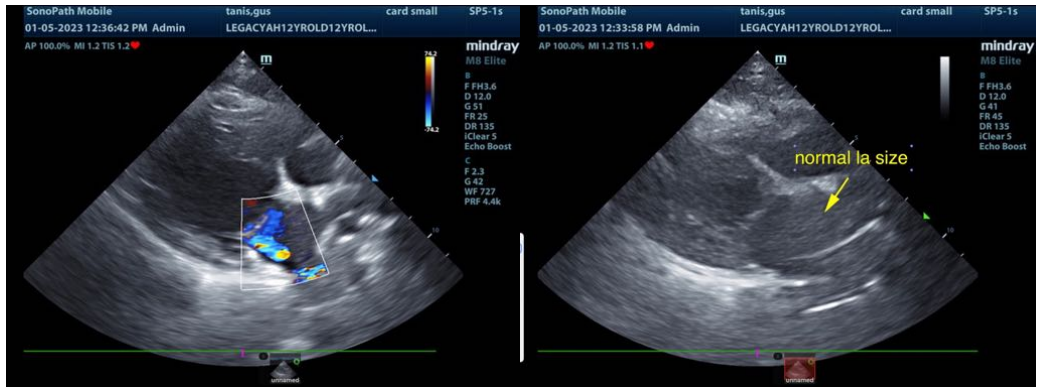
Puggle

SEX

Neutered male

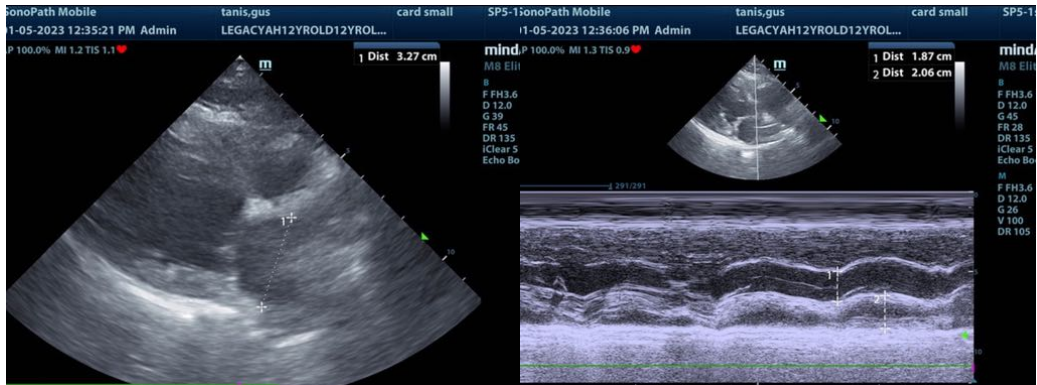
AGE

12 years



WEIGHT

61.8 lbs



INTERPRETED BY

Eric Lindquist, DMV,
DABVP, Cert. IVUSS,
CEO of SonoPath.com

IMAGING PERFORMED BY

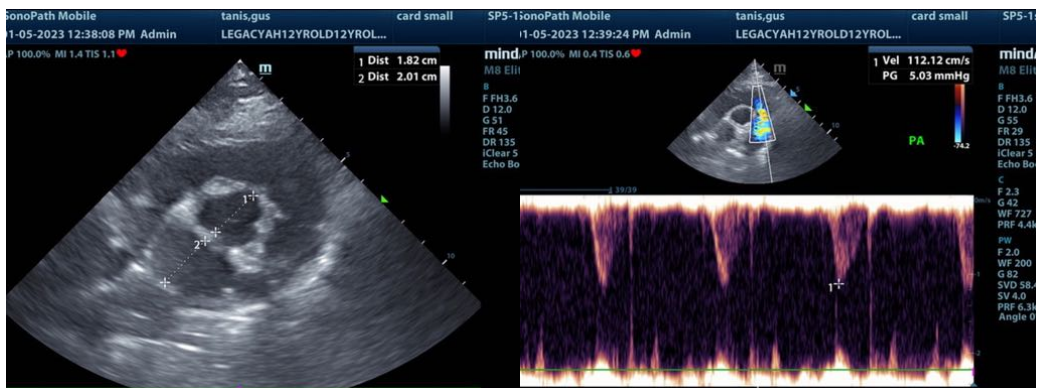
Kelly Vazquez, CVT

HOSPITAL NAME

Legacy AH

REFERRING VET

Dr. Pontenzone



INVOICE

42537

DATE

1/5/23



PATIENT

Gus Tanis

SPECIES

Canine

BREED

Puggle

SEX

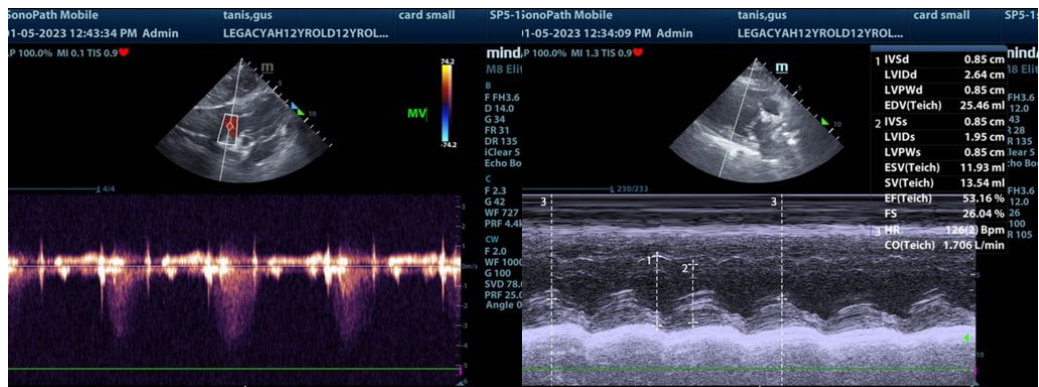
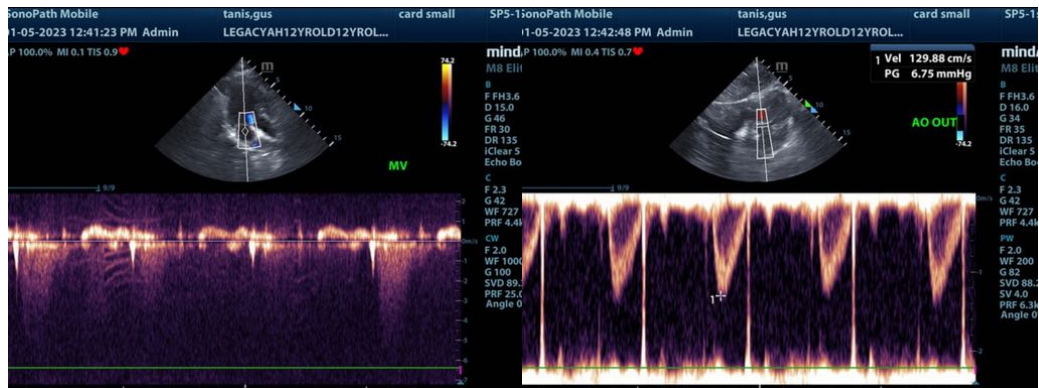
Neutered male

AGE

12 years

WEIGHT

61.8 lbs



INTERPRETED BY

Eric Lindquist, DMV,
DABVP, Cert. IVUSS,
CEO of SonoPath.com

IMAGING PERFORMED BY

Kelly Vazquez, CVT

HOSPITAL NAME

Legacy AH

REFERRING VET

Dr. Pontenzone

INVOICE

42537

DATE

1/5/23

The information and recommendations provided are based on the images presented by the referring veterinarian/sonographer. No evaluation can be communicated regarding pathology that was not visible in the image/video clips provided.

Thank you for this referral. If the clinical or image interpretation does not parallel your findings or if I can be of any further assistance please contact me.

Eric Lindquist, DMV, DABVP, Cert. IVUSS, CEO of SonoPath.com

Info@SonoPath.com