



**PATIENT PRESENTING CLINICAL SIGNS**

Jake Moore

History: Possible severely dilated myocardium, decreased contractility, cardiomegaly on ultrasound.  
Current meds: Vetmedin, Furosemide, Enalapril, Pimobendan.

**SPECIES**

Canine

**ULTRASONOGRAPHIC EXAMINATION OF THE HEART**

**BREED**

Labrador Retriever

The **left** heart appeared subjectively volume contracted. The **mitral** valve revealed trivial insufficiency. The **left ventricular outflow** tract demonstrated normal laminar flow and subjective structural integrity. The **right atrium** and auricle revealed normal size, structure and content. No evidence of masses was noted. **Tricuspid** insufficiency was noted. The **right ventricle** was of normal size (1/3 diameter of LV), chordae structure, myocardial echogenicity and thickness. Slight **pulmonic insufficiency** was noted at 1.14 m/sec. No visible **pericardial** or free pleura fluid was noted. The cranial **mediastinum and pericardial and extra-cardiac regions** were free of masses in the visible window.

**SEX**

Neutered male

**AGE**

10 years

**WEIGHT**

80.4 lbs

**INTERPRETED BY**

Eric Lindquist, DMV  
DABVP, Cert. IVUSS

**IMAGING PERFORMED BY**

Shari Reffi, CVT

**HOSPITAL NAME**

North Warren AH

**REFERRING VET**

Dr. Corrado/Bociulus

CANINE CARDIAC PARAMETERS	MR VMAX (m/s)	TR VMAX (m/s)	LA/AO (Boon method)	LA/AO (Heart Base; Swe)	FS (%)	EF (%)	EPSS (cm)
NORMAL PARAMETER	4.5-5.5	<2.7	1.3	<1.6	28-40	40-100	<0.6
PATIENT			0.97	1.0	36	65	0.42
CANINE CARDIAC PARAMETERS	HR (BPM)	AV VMAX (m/s)	PV MAX (m/s)	BODY WEIGHT	LA (2D short axis Base view) (cm)	LVIDd (Avg; 2D and m-mode short axis) (cm)	LVIDs (Avg; 2D and m-mode short axis) (cm)
NORMAL PARAMETER	50-100	0.7-1.7	0.7-1.6	BELOW	BELOW	BELOW	BELOW
PATIENT	103	1.5	1.5	80.4 lbs	4.5 max	4.43	

**ULTRASONOGRAPHIC FINDINGS**

Minor tricuspid insufficiency.

Volume contracted left heart.

Trivial mitral insufficiency.

**INVOICE**

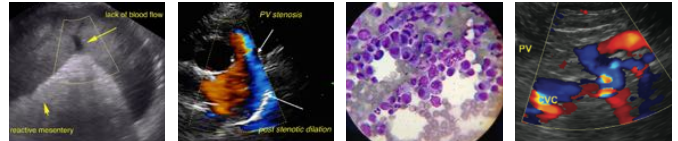
42476

**DATE**

1/3/23

**INTERPRETATION OF THE FINDINGS & FURTHER RECOMMENDATIONS**

If a prior echocardiogram was performed in this patient the pathology appears completely compensated. The mitral and tricuspid insufficiency is minor and not likely causing significant disease. I recommend weaning off the current protocol starting with reduction of Lasix, Pimobendan and Enalapril. If congestive heart failure was diagnosed on prior echocardiogram, then it may have been a temporary issue such as myocarditis as currently the heart appears well compensated, in fact volume contracted and the mitral and tricuspid insufficiency is minimal. After medications have been eliminated



**PATIENT**

Jake Moore

a recheck echocardiogram is warranted in approximately 2-3 weeks after stopping medications. I recommend to monitoring patient demeanor, sleeping respiratory rate and any evidence of exercise intolerance.

**SPECIES**

Canine

**BREED**

Labrador Retriever

**SEX**

Neutered male

**AGE**

10 years

**WEIGHT**

80.4 lbs

**INTERPRETED BY**

Eric Lindquist, DMV  
DABVP, Cert. IVUSS

**IMAGING PERFORMED BY**

Shari Reffi, CVT

**HOSPITAL NAME**

North Warren AH

**REFERRING VET**

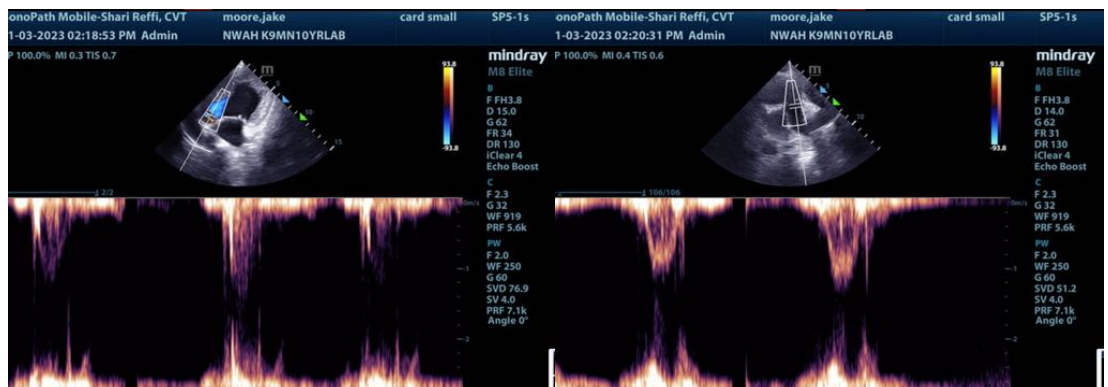
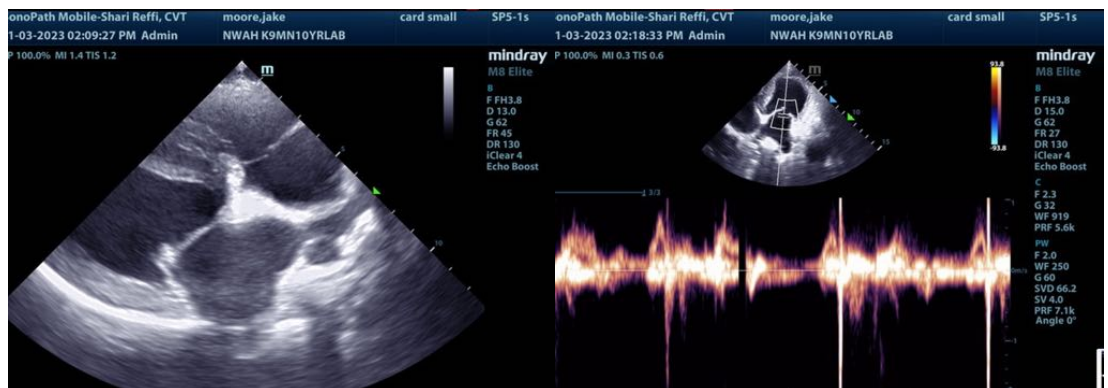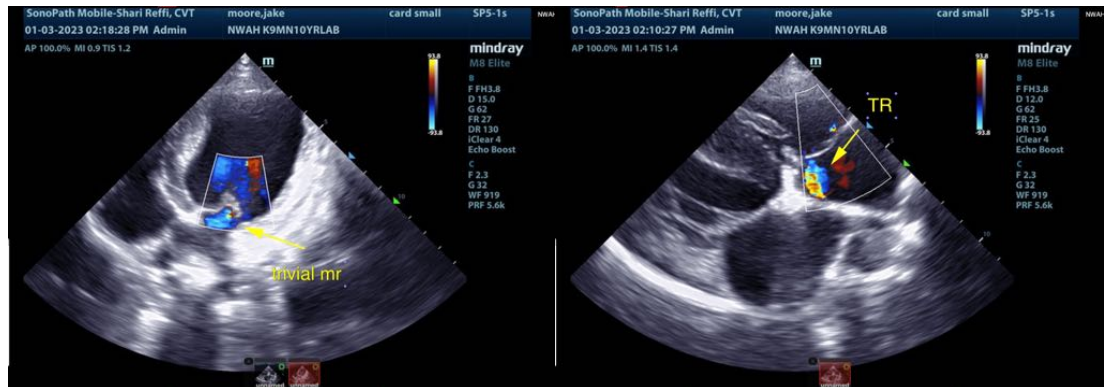
Dr. Corrado/Bociulus

**INVOICE**

42476

**DATE**

1/3/23





**PATIENT**

Jake Moore

**SPECIES**

Canine

**BREED**

Labrador Retriever

**SEX**

Neutered male

**AGE**

10 years

**WEIGHT**

80.4 lbs

**INTERPRETED BY**

Eric Lindquist, DMV  
DABVP, Cert. IVUSS

**IMAGING PERFORMED BY**

Shari Reffi, CVT

**HOSPITAL NAME**

North Warren AH

**REFERRING VET**

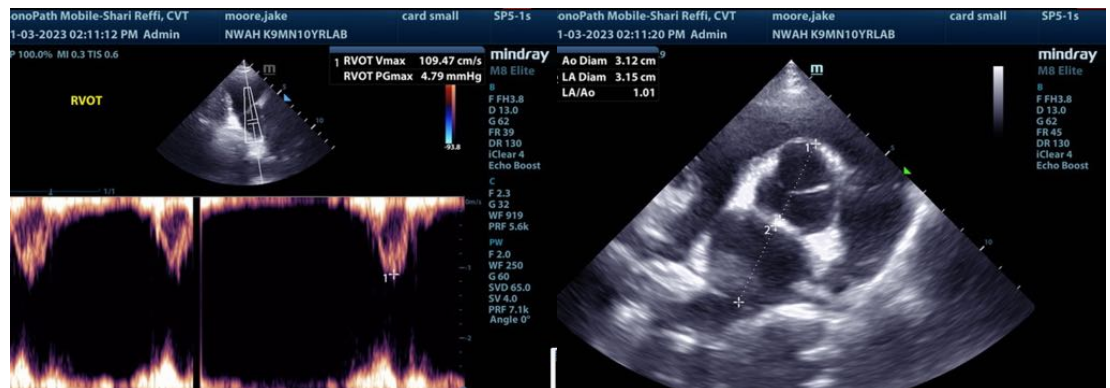
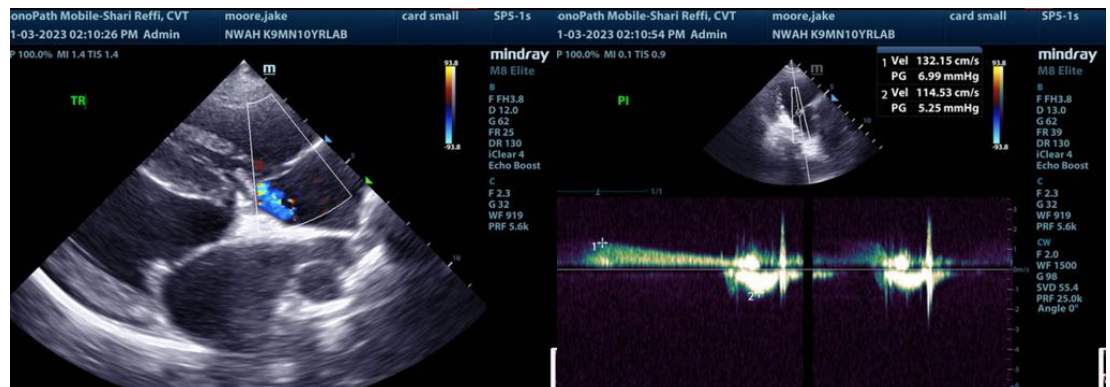
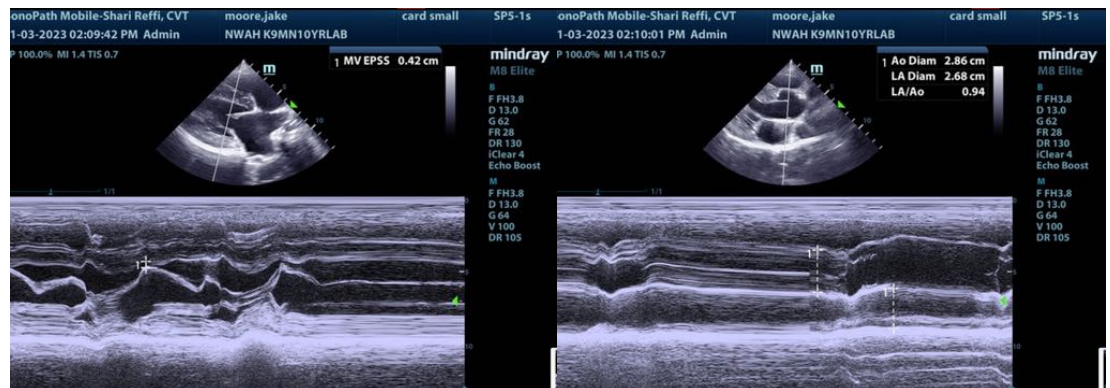
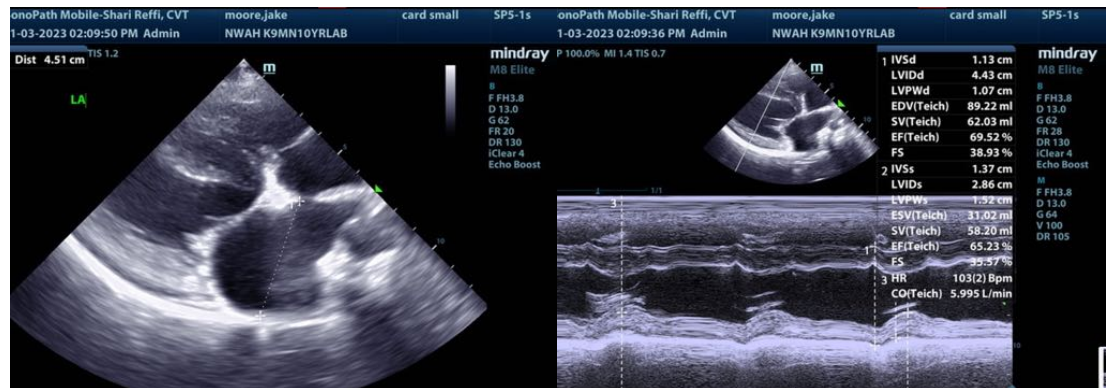
Dr. Corrado/Bociulus

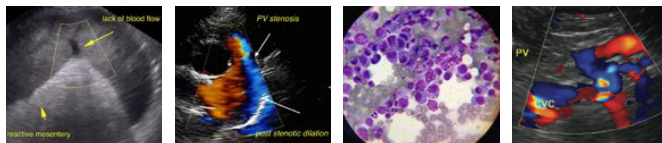
**INVOICE**

42476

**DATE**

1/3/23





**PATIENT**

Jake Moore

The information and recommendations provided are based on the images presented by the referring veterinarian/sonographer. No evaluation can be communicated regarding pathology that was not visible in the image/video clips provided.

**SPECIES**

Canine

Thank you for this referral. If the clinical or image interpretation does not parallel your findings or if I can be of any further assistance please contact me.

**BREED**

Labrador Retriever

**Eric Lindquist**, DMV, DABVP, Cert. IVUSS, CEO of SonoPath.com  
Info@SonoPath.com

**SEX**

Neutered male

**AGE**

10 years

**WEIGHT**

80.4 lbs

**INTERPRETED BY**

Eric Lindquist, DMV  
DABVP, Cert. IVUSS

**IMAGING  
PERFORMED BY**

Shari Reffi, CVT

**HOSPITAL NAME**

North Warren AH

**REFERRING VET**

Dr. Corrado/Bociulus

**INVOICE**

42476

**DATE**

1/3/23