



PATIENT PRESENTING CLINICAL SIGNS

Gunner Haag History: Markedly decreased cardiac contractility, possible cyanosis episodes with exercise. Current meds: Hydroxazine, Tamaril P (taper)
SPECIES Abnormal PE/Chem/CBC/UA Results: BNP 2698.7

Canine

ULTRASONOGRAPHIC EXAMINATION OF THE HEART

BREED The echocardiogram in this patient demonstrated normal **left atrial** size based on 3 separate methods of LA evaluation. The cranial and caudal **mitral** valve leaflets presented normal linear structure, extension in systole, and union in diastole with normal kinesis. The **left ventricle** presented normal thicknesses with linear contour and was not dilated nor restricted. The **myocardium** presented normal echogenicity without subjective evidence of significant fibrotic or ischemic disease. **Contractility** of the ventricular walls was adequate and in normal range for this patient evidenced by the fractional shortening measurement and subjective evaluation of the different regions of the myocardium. The **left ventricular outflow** tract demonstrated normal laminar flow and subjective structural integrity. The **right atrium** and auricle revealed normal size, structure and content. No evidence of masses was noted. **Tricuspid** insufficiency was noted and measured 2.29 m/sec. The **right ventricle** was of normal size (1/3 diameter of LV), chordae structure, myocardial echogenicity and thickness. **Pulmonary outflow** tract assessment revealed normal valve structure, laminar flow, and diameter (approx.1:1 pa/ao ratio). No visible **pericardial** or free pleura fluid was noted. The cranial **mediastinum and pericardial and extra-cardiac regions** were free of masses in the visible window.

SEX Intact male

AGE 3 years

WEIGHT 66 lbs

INTERPRETED BY

Eric Lindquist, DMV
DABVP, Cert. IVUSS

IMAGING PERFORMED BY

Shari Reffi, CVT

HOSPITAL NAME

North Warren AH

REFERRING VET

Dr. Corrado/Bociulus

CANINE CARDIAC PARAMETERS	MR VMAX (m/s)	TR VMAX (m/s)	LA/AO (Boon method)	LA/AO (Heart Base; Swe)	FS (%)	EF (%)	EPSS (cm)
NORMAL PARAMETER	4.5-5.5	<2.7	1.3	<1.6	28-40	40-100	<0.6
PATIENT		2.29	1.15	1.4	30	57	0.3
CANINE CARDIAC PARAMETERS	HR (BPM)	AV VMAX (m/s)	PV MAX (m/s)	BODY WEIGHT	LA (2D short axis Base view) (cm)	LVIDd (Avg; 2D and m-mode short axis) (cm)	LVIDs (Avg; 2D and m-mode short axis) (cm)
NORMAL PARAMETER	50-100	0.7-1.7	0.7-1.6	BELOW	BELOW	BELOW	BELOW
PATIENT		1.5	1.27	66 lbs	4.0 max	4.15	

INVOICE

42477

DATE

1/3/23

ULTRASONOGRAPHIC FINDINGS

Trivial tricuspid insufficiency. This is largely physiological in this breed.



PATIENT

Gunner Haag

SPECIES

Canine

BREED

German Shepherd

SEX

Intact male

AGE

3 years

WEIGHT

66 lbs

INTERPRETED BY

Eric Lindquist, DMV
DABVP, Cert. IVUSS

IMAGING PERFORMED BY

Shari Reffi, CVT

HOSPITAL NAME

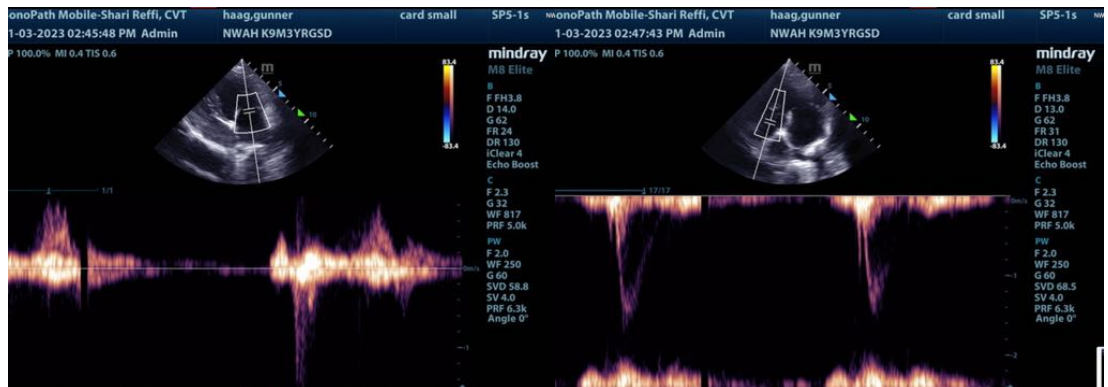
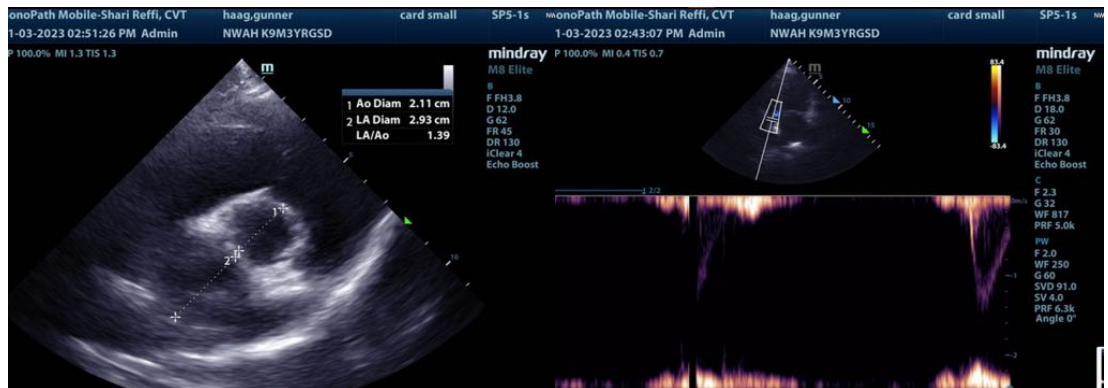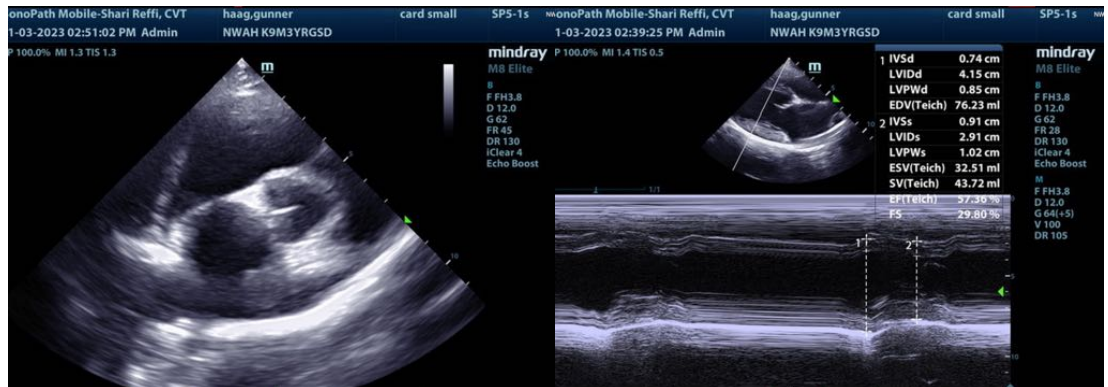
North Warren AH

REFERRING VET

Dr. Corrado/Bociulus

INTERPRETATION OF THE FINDINGS & FURTHER RECOMMENDATIONS

Structurally and functionally normal heart otherwise. There was no evidence of pathology. The cause of BNP elevation is not evident. Systemic disease or false positive results should be considered.



INVOICE

42477

DATE

1/3/23



PATIENT

Gunner Haag

SPECIES

Canine

BREED

German Shepherd

SEX

Intact male

AGE

3 years

WEIGHT

66 lbs

INTERPRETED BY

Eric Lindquist, DMV
DABVP, Cert. IVUSS

IMAGING PERFORMED BY

Shari Reffi, CVT

HOSPITAL NAME

North Warren AH

REFERRING VET

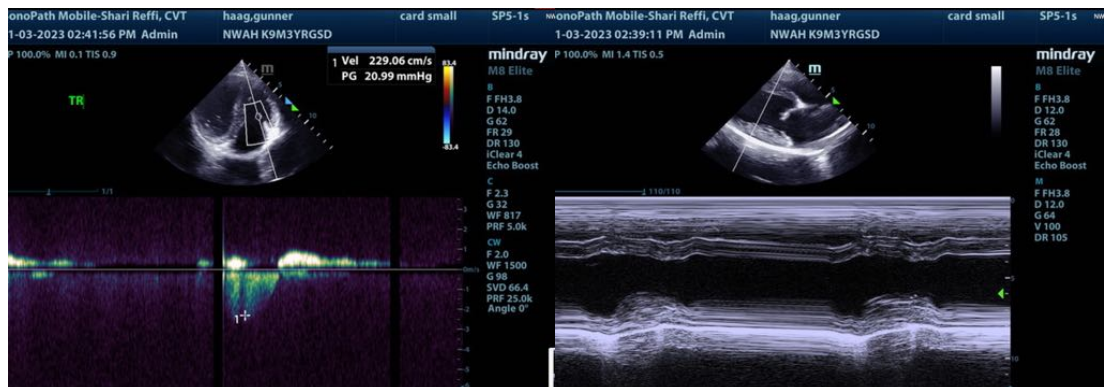
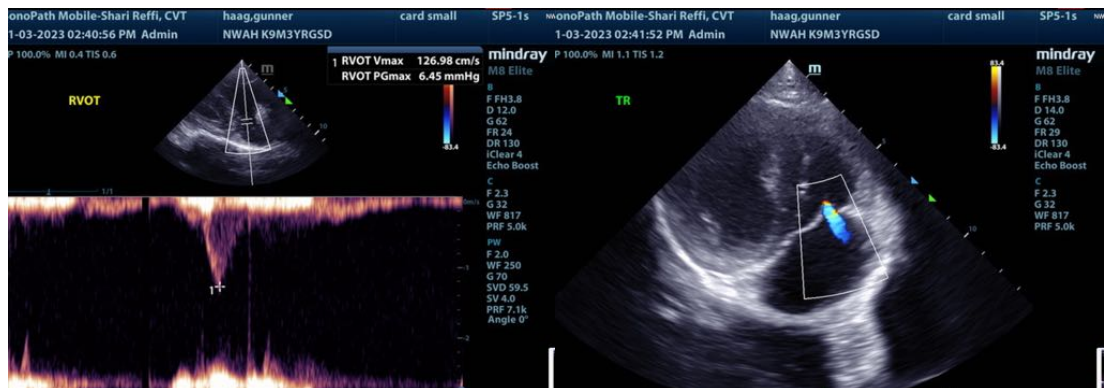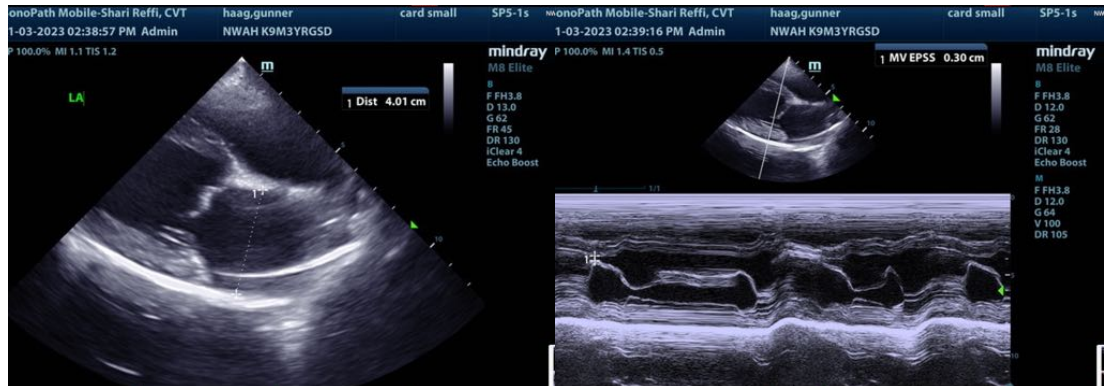
Dr. Corrado/Bociulus

INVOICE

42477

DATE

1/3/23



The information and recommendations provided are based on the images presented by the referring veterinarian/sonographer. No evaluation can be communicated regarding pathology that was not visible in the image/video clips provided.

Thank you for this referral. If the clinical or image interpretation does not parallel your findings or if I can be of any further assistance please contact me.

Eric Lindquist, DMV, DABVP, Cert. IVUSS, CEO of SonoPath.com
Info@SonoPath.com