

PATIENT

Remi Villari

PRESENTING CLINICAL SIGNS

History: inappetence, significant acute wt loss
Abnormal PE/Chem/CBC/UA Results: pending

SPECIES

Feline

BREED

Domestic Shorthair

SEX

Spayed female

AGE

14 years

WEIGHT

8 lbs

INTERPRETED BY

Eric Lindquist, DMV
DABVP, Cert. IVUSS

IMAGING PERFORMED BY

Diane McFadden, RVT

HOSPITAL NAME

Animal Care Center of
Landing

REFERRING VET

Dr. Villari

INVOICE

42293

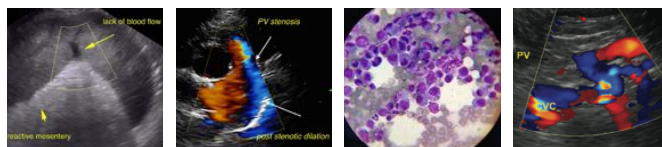
DATE

1/24/23

ULTRASONOGRAPHIC EXAMINATION OF THE HEART

The echocardiogram in this patient demonstrated normal **left atrial** size based on 3 separate LA measurements. The cranial and caudal **mitral** valve leaflets presented normal linear structure and kinetics. The **left ventricle** presented normal thicknesses with linear contour and was not dilated nor restricted. The **myocardium** presented normal echogenicity without subjective evidence of significant fibrotic or ischemic disease. **Contractility** of the ventricular walls was adequate and in normal range for this patient evidenced by the fractional shortening measurement and subjective evaluation of the different regions and angles of the myocardium. Minor aortic insufficiency was noted. The **right atrium** and auricle revealed normal size, structure and content. No evidence of masses was noted or chamber overload. Trivial **tricuspid** insufficiency is noted, yet not clinically significant. The **right ventricle** was of normal size (1/3 diameter of LV), chordae structure, myocardial echogenicity and thickness. **Pulmonic** tract assessment revealed normal valve structure, laminar flow, and diameter (approx. 1:1 pa/ao ratio). No visible **pericardial** or free pleura fluid was noted or extra cardiac pathology in the visible planes. The cranial **mediastinum and pericardial regions** were free of masses in the visible window. Tachycardia was present.

FELINE CARDIAC PARAMETERS	BODY WEIGHT	HR (BPM)	IVSd (cm)	LVIDd (cm)	LVWd (cm)	FS (%)	EF (%)
NORMAL PARAMETER	-----	150-240	0.3-0.6	1.0-2.1	0.25-0.6	35-67	80-100
PATIENT	8 lbs	259	0.35	1.4	0.53	31	64
FELINE CARDIAC PARAMETERS	LA/AO (Boon)	LA/AO HEART BASE (Sisson)	LA 2D 4-chamber long axis AS to FW (Sisson) (cm)	LVOT VEL. (m/s)	RVOT VEL. (m/s)	IVRT (m/)	
NORMAL PARAMETER	<1.5	0.88-1.79	0.7-1.7	<1.6	<1.3	40-60	
PATIENT	1.11	1.17	1.3	1.0		NM	
Adapted from June Boon, Veterinary Echocardiography, 1998 Sisson D et al. JVIM 1991; 5: 232, Jacobs et al. Am J Vet Res 1985; 46:1705							



PATIENT

Remi Villari

SPECIES

Feline

BREED

Domestic Shorthair

SEX

Spayed female

AGE

14 years

WEIGHT

8 lbs

INTERPRETED BY

Eric Lindquist, DMV
DABVP, Cert. IVUSS

**IMAGING
PERFORMED BY**

Diane McFadden, RVT

HOSPITAL NAME

Animal Care Center of
Landing

REFERRING VET

Dr. Villari

INVOICE

42293

DATE

1/24/23

ULTRASONOGRAPHIC EXAMINATION OF THE ABDOMEN

Urinary System

The **urinary bladder**, trigone, and pelvic urethra presented normal thicknesses and normal tone. The ureters were not visible which is normal. No uroliths or sediment were visualized and anechoic urine was present. No evidence of inflammatory or neoplastic changes was noted. Ureteral papillae were normal.

The **kidneys** were slightly irregular in contour. Both kidneys measured 3.66 cm. Blood flow appeared adequate.

Adrenal Glands

Both **adrenal glands** were visualized and recognized as having normal shape, size, position and echogenicity for this breed. The phrenic vasculature, glandular echogenicity and detail were unremarkable. Capsule, cortex, and medullary definition were normal for this age patient.

Spleen

The **spleen** in this patient was uniform, yet volume contracted. Hydration status should be assessed.

Liver

The **liver** was slightly enlarged and mildly hypoechoic to the surrounding parenchyma. Slight scalloping contour was noted. The gallbladder and common bile duct were unremarkable.

Gastrointestinal

The **gastrointestinal tract** revealed minor variable thickening and echogenic submucosal changes most consistent with low grade end result of chronic GI disease such as IBD and may be related to malassimilation of nutrients if any weight loss is present. No obvious neoplastic patterns were noted and luminal content as unremarkable.

Pancreas

The base and limbs of the **pancreas** were observed to be largely isoechoic to surrounding omental fat. Pancreatic duct and capsular contour were acceptably normal and parenchyma respected normal curvilinear patterns. No overt evidence of active inflammatory or neoplastic disease was noted.



PATIENT ULTRASONOGRAPHIC FINDINGS

Remi Villari Normal echocardiogram with tachycardia. Trivial tricuspid insufficiency.

Geriatric abdomen.

SPECIES

Slightly irregular kidneys and liver.

Feline

BREED

INTERPRETATION OF THE FINDINGS & FURTHER RECOMMENDATIONS

Domestic Shorthair

EKG and blood pressure measurements are recommended.

SEX

There was no evidence of significant disease; however, I cannot rule out occult neoplasia. Screening FNA of the liver and kidneys could be considered after coagulation panel in this patient to rule out occult emerging lymphoma or similar pathology, yet the changes may be normal variants for the age and species.

Spayed female

AGE

14 years

WEIGHT

8 lbs

INTERPRETED BY

Eric Lindquist, DMV
DABVP, Cert. IVUSS

IMAGING PERFORMED BY

Diane McFadden, RVT

HOSPITAL NAME

Animal Care Center of
Landing

REFERRING VET

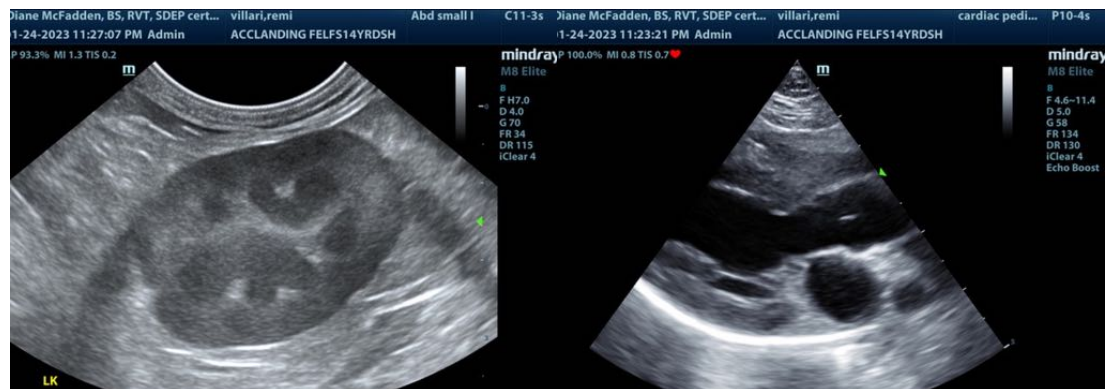
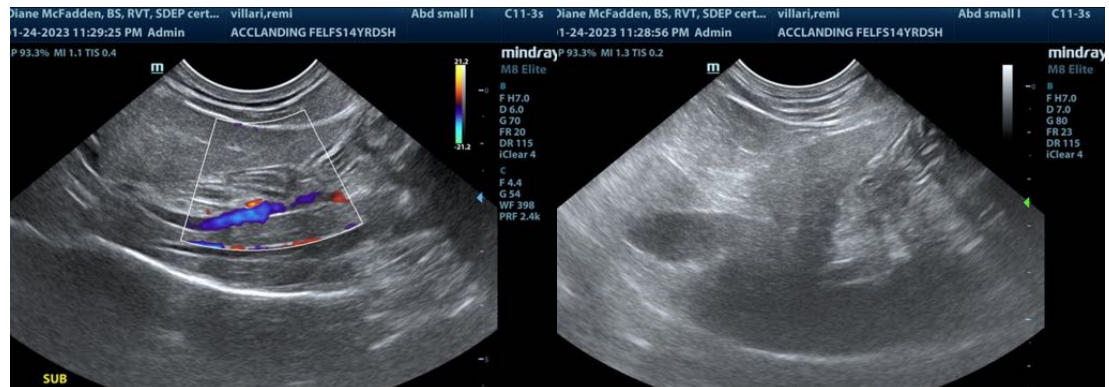
Dr. Villari

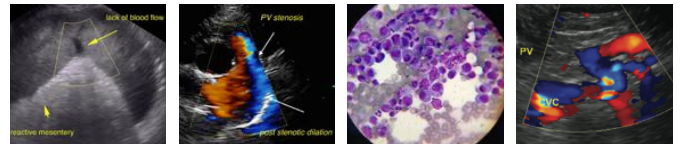
INVOICE

42293

DATE

1/24/23





PATIENT

Remi Villari

SPECIES

Feline

BREED

Domestic Shorthair

SEX

Spayed female

AGE

14 years

WEIGHT

8 lbs

INTERPRETED BY

Eric Lindquist, DMV
DABVP, Cert. IVUSS

IMAGING PERFORMED BY

Diane McFadden, RVT

HOSPITAL NAME

Animal Care Center of
Landing

REFERRING VET

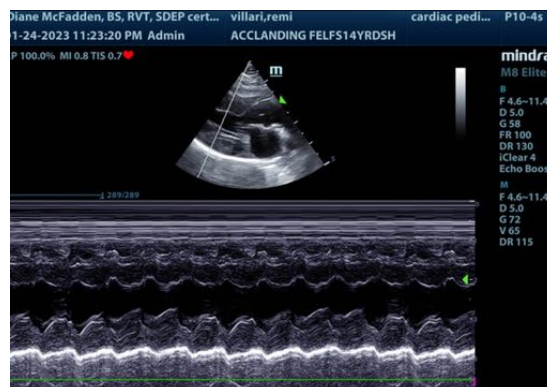
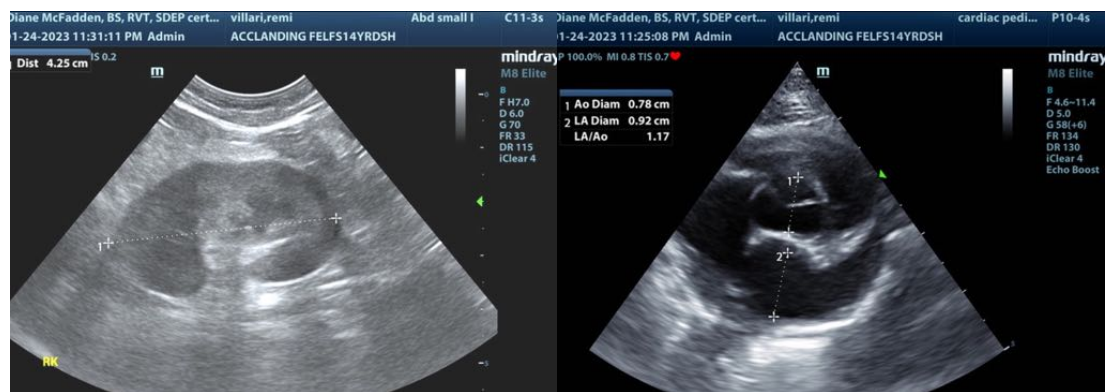
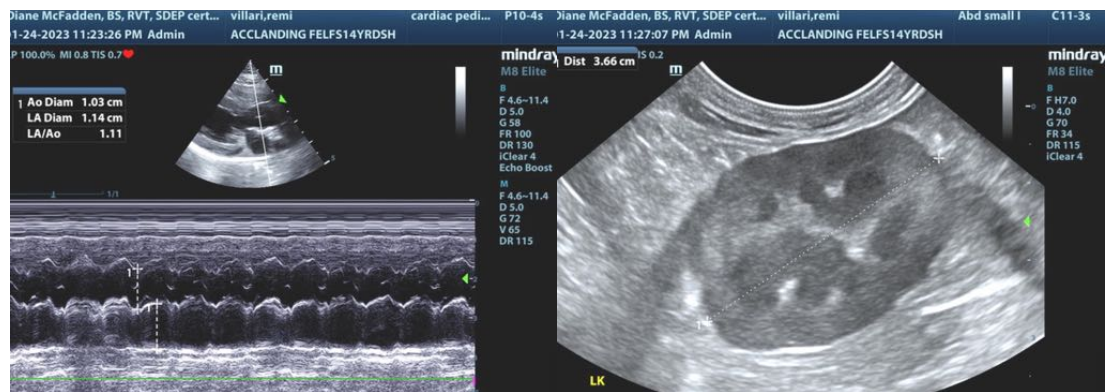
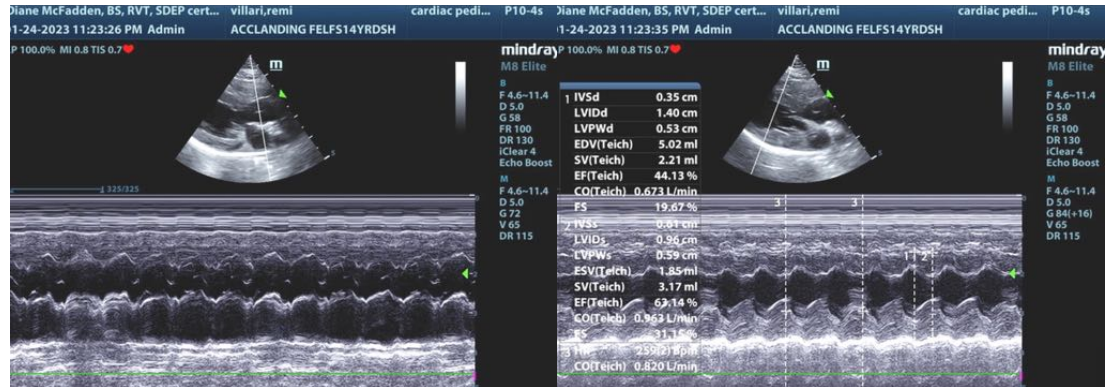
Dr. Villari

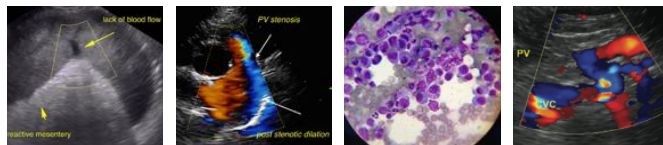
INVOICE

42293

DATE

1/24/23





PATIENT

Remi Villari

The information and recommendations provided are based on the images presented by the referring veterinarian/sonographer. No evaluation can be communicated regarding pathology that was not visible in the image/video clips provided.

SPECIES

Feline

Thank you for this referral. If the clinical or image interpretation does not parallel your findings or if I can be of any further assistance please contact me.

BREED

Domestic Shorthair

Eric Lindquist, DMV, DABVP, Cert. IVUSS, CEO of SonoPath.com
Info@SonoPath.com

SEX

Spayed female

AGE

14 years

WEIGHT

8 lbs

INTERPRETED BY

Eric Lindquist, DMV
DABVP, Cert. IVUSS

**IMAGING
PERFORMED BY**

Diane McFadden, RVT

HOSPITAL NAME

Animal Care Center of
Landing

REFERRING VET

Dr. Villari

INVOICE

42293

DATE

1/24/23