

PATIENT

Enzo Estra

SPECIES

Canine

BREED

Labradoodle

SEX

Neutered male

AGE

2 years

WEIGHT

45.5 lbs

INTERPRETED BY

Eric Lindquist, DMV,
DABVP, Cert. IVUSS,
CEO of SonoPath.com

IMAGING PERFORMED BY

Kelly Vazquez, CVT

HOSPITAL NAME

New Bridge VH

REFERRING VET

Dr. Glennon

INVOICE

42266

DATE

1/25/23

PRESENTING CLINICAL SIGNS

History: Inappetence, licking lips, vomited several times. Currently on IVFs and Cerenia.
Abnormal PE/Chem/CBC/UA Results: Bloods WNL. Mildly elevated liver enzymes.

ULTRASONOGRAPHIC EXAMINATION OF THE ABDOMEN

Urinary System

The **urinary bladder**, trigone, and pelvic urethra presented normal thicknesses and normal tone. The ureters were not visible which is normal. No uroliths or sediment were visualized and anechoic urine was present. No evidence of inflammatory or neoplastic changes was noted. Ureteral papillae were normal.

The residual prostate measured 0.84 cm.

The **kidneys** revealed normal size and structure, corticomedullary definition and ratio for this age. The cortices presented largely uniform texture with normal echogenic relationship to liver and spleen. Medullary structure differed distinctly from the cortex and no evidence of pelvic dilation was present. The capsules were acceptably uniform without significant irregularities. The left kidney measured 6.24 cm.

Adrenal Glands

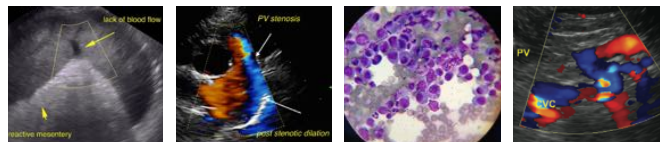
Both **adrenal glands** were visualized and recognized as having normal shape, size, position and echogenicity for this breed. The phrenic vasculature, glandular echogenicity and detail were unremarkable. Capsule, cortex, and medullary definition were normal for this age patient. The left adrenal gland measured 2.54 x 0.32 cm at the caudal pole and 0.54 cm at the cranial pole. The right adrenal gland measured 1.79 x 0.35 cm at the caudal pole and 0.57 cm at the cranial pole

Spleen

The **spleen** presented a smooth homogeneous parenchyma hyperechoic to liver and renal cortical parenchyma. The capsule was smooth without noticeable expansion or deviation from within the spleen or adjacent pathology. The splenic vasculature demonstrated normal volume without signs of congestion or thrombosis. No sonographic evidence of acute or chronic inflammatory, neoplastic, or infarctual changes was noted.

Liver

The **liver** images submitted revealed subjectively normal liver size, contour, and structure. Parenchymal echogenicity was naturally coarse and hypoechoic to the spleen. Vascular and biliary tracts were of normal volume with no evidence of congestion. The gallbladder presented acceptably thin walls with primarily anechoic content. The cystic and common bile ducts were normal. No pathological hepatic lymphadenopathy was evident. No overt structural evidence of inflammatory, infiltrative or regenerative pathology was evident.



PATIENT

Gastrointestinal

Enzo Estra

The **stomach** revealed an empty lumen. Gastric mucosal remodeling was noted without evidence of foreign body or neoplasia. This is most consistent with gastritis. Some enhanced mesentery was noted.

SPECIES

Canine

The intestines were free of stasis, of normal wall thickness, acceptable curvilinear mural detail, and peristaltic activity. Small and large intestine demonstrated normal luminal chyme and stool consistency respectively. No obstructive or overt infiltrative disease was noted. No associated abnormal lymphatic activity was noted.

BREED

Labradoodle

Pancreas

SEX

Neutered male

The base and limbs of the **pancreas** were observed to be largely isoechoic to surrounding omental fat. Pancreatic duct and capsular contour were acceptably normal and parenchyma respected normal curvilinear patterns. No overt evidence of active inflammatory or neoplastic disease was noted.

AGE

2 years

ULTRASONOGRAPHIC FINDINGS

Non-specific gastritis present.

Minor reactive hepatopathy.

WEIGHT

45.5 lbs

INTERPRETATION OF THE FINDINGS & FURTHER RECOMMENDATIONS

A clinical trial of the following may prove effective. Otherwise, endoscopy is indicated if clinical signs persist despite empirical measures. Screening for Addison's is indicated as the adrenal glands are at the low normal in measurement.

A clinical trial of **Zithromax** (**Dogs:** 5-10 mg/kg p.o. q24h. May increase dosing interval to q48h after 3-5 days of treatment), **Metronidazole** (10-20 mg/kg p.o. b.i.d.), **Pepcid** (0.5-1 mg/kg s.i.d.) and **Sucralfate** (0.5-2 g/dog PO) or **Omeprazole** (1 mg/kg p.o. s.i.d.) over the next 3 weeks along with a **novel-protein or hydrolyzed diet** with slurry feeding b.i.d./t.i.d. over the next 2-4 days and then increase to canned diet bid. Dry food should be avoided over the next 4 weeks. A recheck sonogram to assess GI improvement or progression would be ideal in 4 weeks.

INTERPRETED BY

Eric Lindquist, DMV,
DABVP, Cert. IVUSS,
CEO of SonoPath.com

IMAGING PERFORMED BY

Kelly Vazquez, CVT

HOSPITAL NAME

New Bridge VH

REFERRING VET

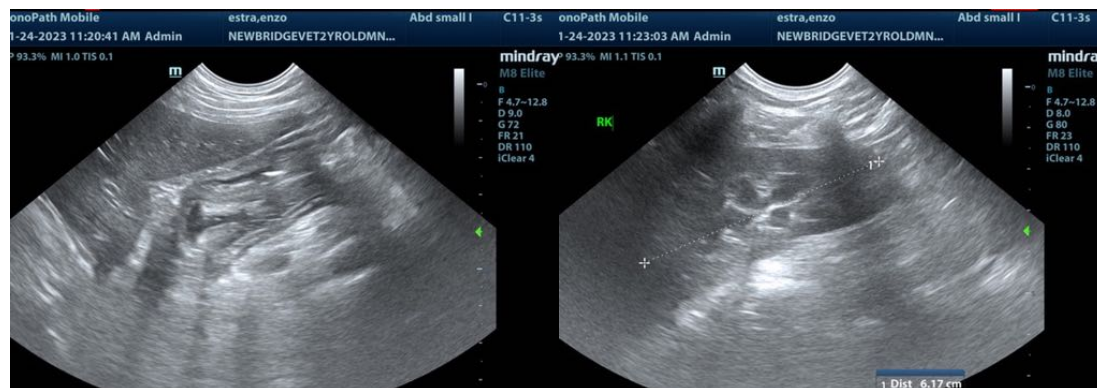
Dr. Glennon

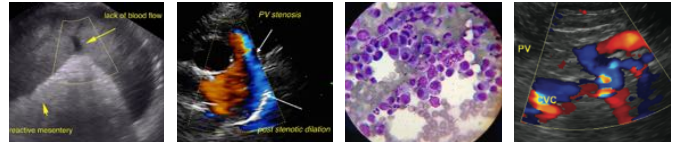
INVOICE

42266

DATE

1/25/23





PATIENT

Enzo Estra

SPECIES

Canine

BREED

Labradoodle

SEX

Neutered male

AGE

2 years

WEIGHT

45.5 lbs

INTERPRETED BY

Eric Lindquist, DMV,
DABVP, Cert. IVUSS,
CEO of SonoPath.com

IMAGING PERFORMED BY

Kelly Vazquez, CVT

HOSPITAL NAME

New Bridge VH

REFERRING VET

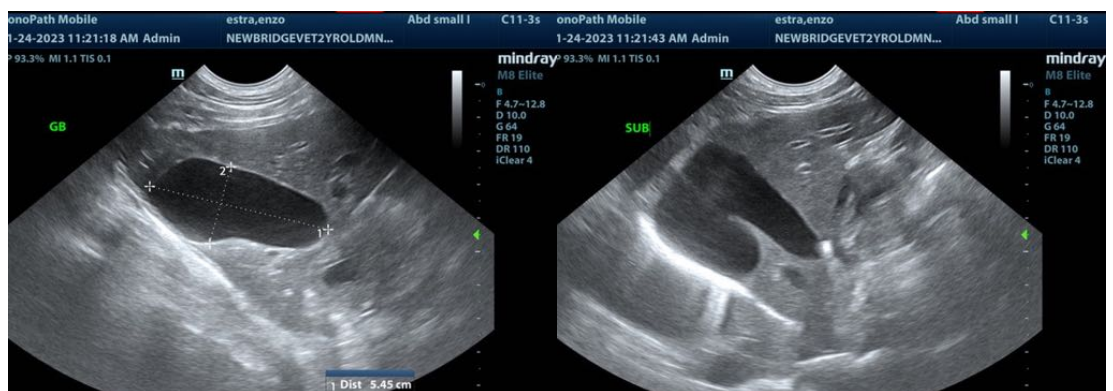
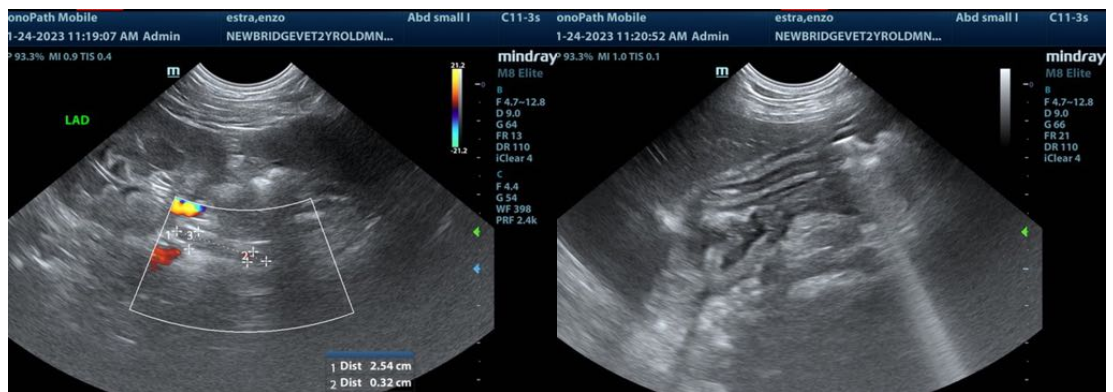
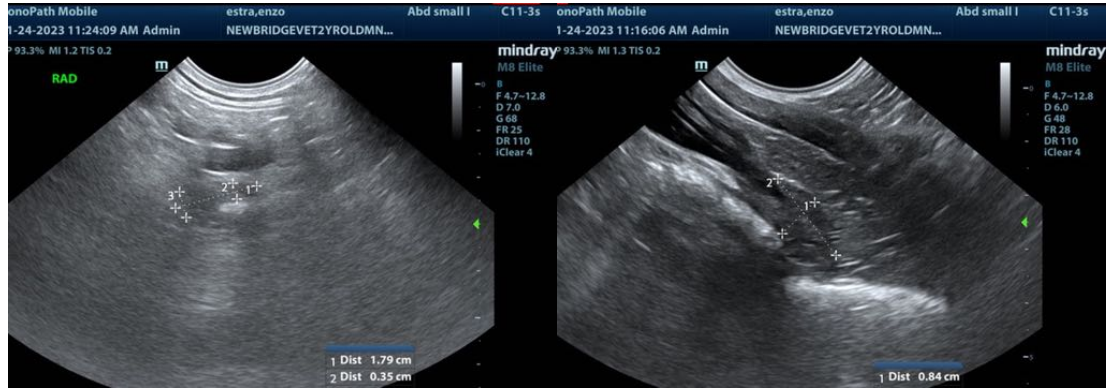
Dr. Glennon

INVOICE

42266

DATE

1/25/23

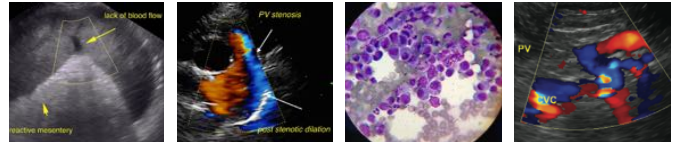


The information and recommendations provided are based on the images presented by the referring veterinarian/sonographer. No evaluation can be communicated regarding pathology that was not visible in the image/video clips provided.

Thank you for this referral. If the clinical or image interpretation does not parallel your findings or if I can be of any further assistance please contact me.

Eric Lindquist, DMV, DABVP, Cert. IVUSS, CEO of SonoPath.com

Info@SonoPath.com



PATIENT

Enzo Estra

SPECIES

Canine

BREED

Labradoodle

SEX

Neutered male

AGE

2 years

WEIGHT

45.5 lbs

INTERPRETED BY

Eric Lindquist, DMV,
DABVP, Cert. IVUSS,
CEO of SonoPath.com

**IMAGING
PERFORMED BY**

Kelly Vazquez, CVT

HOSPITAL NAME

New Bridge VH

REFERRING VET

Dr. Glennon

INVOICE

42266

DATE

1/25/23