

PATIENT

Amber Falco

SPECIES

Canine

BREED

Cavachon

SEX

Spayed female

AGE

12 years

WEIGHT

28 lbs

INTERPRETED BY

Eric Lindquist, DMV, DABVP, Cert. IVUSS, CEO of SonoPath.com

IMAGING PERFORMED BY

Kelly Vazquez, CVT

HOSPITAL NAME

Ramapo Valley AH

REFERRING VET

Dr. Katara

INVOICE

42292

DATE

1/24/23

PRESENTING CLINICAL SIGNS

History: History of CHF, hepatitis, grade 4/6 systolic murmur. Current meds: Denamarin, Tussigon 5 mgs TID, Furosemide 12.5 mgs 1 and 1/2 tab BID, Benazapril 5 mgs 1/2 BID, Pimobendan 2.5 mgs. Abnormal PE/Chem/CBC/UA Results: 12/9/22: ALT 159, ALP 1789. U/A: protein 3+ (as of 12/9/22), USG 1.041.

ULTRASONOGRAPHIC EXAMINATION OF THE HEART

The echocardiogram in this patient presented mild improvement of the left atrial and left ventricular volume with maintained contractility. There was prolapse to anterior mitral valve leaflet noted. There was mitral and tricuspid insufficiency. There is mild volume overload of the right atrium.

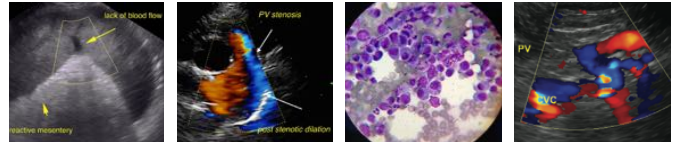
| CANINE CARDIAC PARAMETERS | MR VMAX (m/s) | TR VMAX (m/s) | LA/AO (Boon method) | LA/AO (Heart Base) | FS (%) | EF (%) | EPSS (cm) |
|---------------------------|---------------|---------------|---------------------|--------------------|-----------------------------------|--|--|
| NORMAL PARAMETER | 4.5-5.5 | <2.7 | 1.3 | <1.6 | 28-40 | 40-100 | <0.6 |
| PATIENT | 6.0 | 2.0 | 2.0 | 1.8 | 31 | 58 | NM |
| CANINE CARDIAC PARAMETERS | HR (BPM) | AV VMAX (m/s) | PV MAX (m/s) | BODY WEIGHT | LA (2D short axis Base view) (cm) | LVIDd (Avg; 2D and m-mode short axis) (cm) | LVIDs (Avg; 2D and m-mode short axis) (cm) |
| NORMAL PARAMETER | 50-100 | 0.7-1.7 | 0.7-1.6 | BELOW | BELOW | BELOW | BELOW |
| PATIENT | 95 | 1.63 | 1.28 | 28 lbs | 4.93 | 3.98 | |

ULTRASONOGRAPHIC FINDINGS

Improved cardiac function, yet still has volume overload.

INTERPRETATION OF THE FINDINGS & FURTHER RECOMMENDATIONS

Despite the improvement there is still volume overload. If BUN, creatinine and urine specific gravity are maintained then I recommend adding Spironolactone at 1-2 mg/kg b.i.d. Recheck echocardiogram is recommended in 6 months or earlier if the murmur grade increases. Blood pressure measurements are recommended and sleeping respiratory rate should be less than 25 bpm.



PATIENT

Amber Falco

SPECIES

Canine

BREED

Cavachon

SEX

Spayed female

AGE

12 years

WEIGHT

28 lbs

INTERPRETED BY

Eric Lindquist, DMV,
DABVP, Cert. IVUSS,
CEO of SonoPath.com

IMAGING PERFORMED BY

Kelly Vazquez, CVT

HOSPITAL NAME

Ramapo Valley AH

REFERRING VET

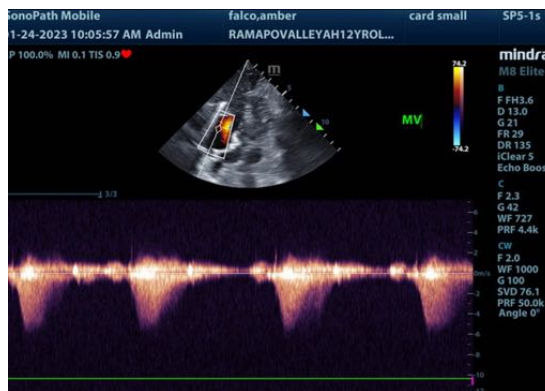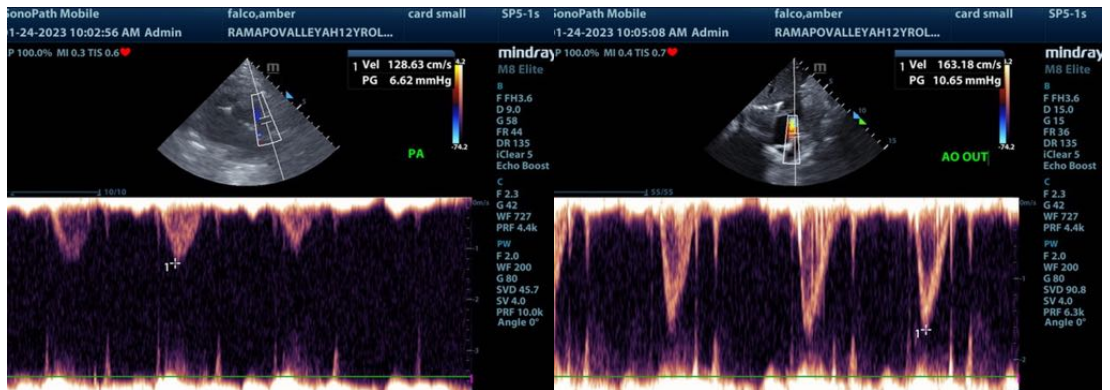
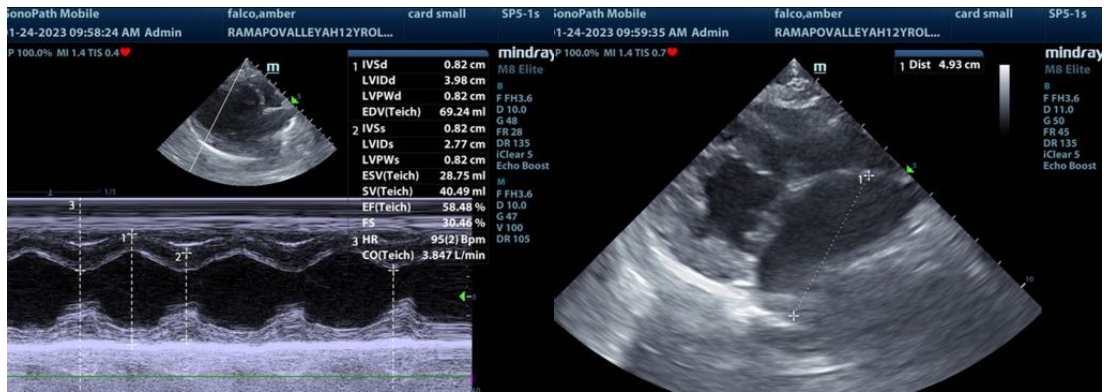
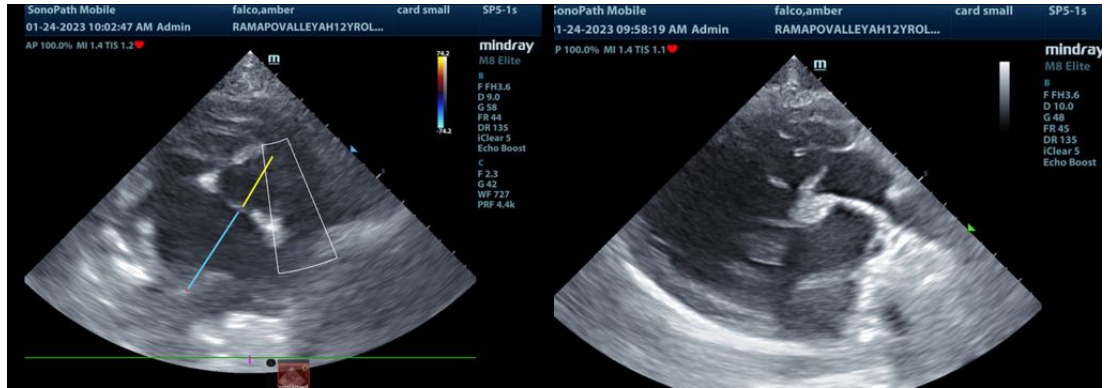Dr. Katara

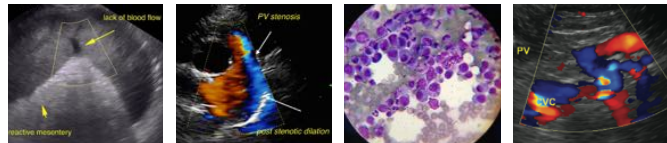
INVOICE

42292

DATE

1/24/23





PATIENT

Amber Falco

SPECIES

Canine

The information and recommendations provided are based on the images presented by the referring veterinarian/sonographer. No evaluation can be communicated regarding pathology that was not visible in the image/video clips provided.

BREED

Cavachon

Thank you for this referral. If the clinical or image interpretation does not parallel your findings or if I can be of any further assistance please contact me.

Eric Lindquist, DMV, DABVP, Cert. IVUSS, CEO of SonoPath.com

SEX

Spayed female

Info@SonoPath.com

AGE

12 years

WEIGHT

28 lbs

INTERPRETED BY

Eric Lindquist, DMV,
DABVP, Cert. IVUSS,
CEO of SonoPath.com

**IMAGING
PERFORMED BY**

Kelly Vazquez , CVT

HOSPITAL NAME

Ramapo Valley AH

REFERRING VET

Dr. Katara

INVOICE

42292

DATE

1/24/23