SonoPath
Clinical Sonography & Telecytology

EDUCATIONAL TELECONSULTATION SERVICES™

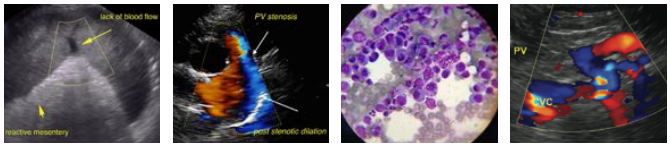

SonoPath.com™
1-800-838-4268 info@sonopath.com

PATIENT

Charlie Shapiro

SPECIES

Canine

BREED

Cockapoo

SEX

Neutered male

AGE

8 years

WEIGHT

NA

INTERPRETED BY

Eric Lindquist, DMV
DABVP, Cert. IVUSS

IMAGING PERFORMED BY

Jessica Miller, RDMS

HOSPITAL NAME

Basking Ridge AH

REFERRING VET

Dr. Hollo

INVOICE

42216

DATE

1/18/23

PRESENTING CLINICAL SIGNS

History: Diarrhea. On prednisone, cervical spinal mass at c4. Enlarged thoracic lymph nodes. PARR test pending on LN aspirate. Current meds: Prednisone, Gabapentin, cerenia
Abnormal PE/Chem/CBC/UA Results: normal on 1/11/23

ULTRASONOGRAPHIC EXAMINATION OF THE ABDOMEN

Urinary System

The **urinary bladder**, trigone, and pelvic urethra presented normal thicknesses and normal tone. The ureters were not visible which is normal. No uroliths or sediment were visualized and anechoic urine was present. No evidence of inflammatory or neoplastic changes was noted. Ureteral papillae were normal.

The **kidneys** revealed normal size and structure, corticomedullary definition and ratio for this age. The cortices presented largely uniform texture with normal echogenic relationship to liver and spleen. Medullary structure differed distinctly from the cortex and no evidence of pelvic dilation was present. The capsules were acceptably uniform without significant irregularities. The right kidney measured 5.44 cm with slight capsular swelling at the dorsal cortex with adjacent free fluid. This area was moderately vascular and measured 1.5 x 1.3 cm. The left kidney measured 5.56 cm.

Adrenal Glands

Both **adrenal glands** were visualized and recognized as having normal shape, size, position and echogenicity for this breed. The phrenic vasculature, glandular echogenicity and detail were unremarkable. Capsule, cortex, and medullary definition were normal for this age patient. The left adrenal gland measured 2.15 x 0.39 cm at the caudal pole and 0.34 cm at the cranial pole. The right adrenal gland measured 2.04 x 1.09 cm at the cranial pole and 0.46 cm at the caudal pole.

Spleen

The **spleen** presented a smooth homogeneous parenchyma hyperechoic to liver and renal cortical parenchyma. The capsule was smooth without noticeable expansion or deviation from within the spleen or adjacent pathology. The splenic vasculature demonstrated normal volume without signs of congestion or thrombosis. No sonographic evidence of acute or chronic inflammatory, neoplastic, or infarctual changes was noted.

Liver

The left medial **liver** revealed 1.8 cm echogenic cyst. The liver was otherwise uniform. The gallbladder presented acceptably thin walls with primarily anechoic content. The cystic and common bile ducts were normal. No pathological hepatic lymphadenopathy was evident.

Gastrointestinal

There was some residual chyme and gas was noted in the **stomach**, yet not pathological. This is consistent with end post prandial presentation. Transit of chyme into the small intestine was normal. Curvilinear patterns were maintained throughout the GI tract. No evidence of pathology. Small and large intestine demonstrated normal luminal chyme and stool consistency respectively. Soft stool was noted in the colon. Reactive mesentery was noted associated with the small intestine.

SonoPath
Clinical Sonography & Telecytology

EDUCATIONAL TELECONSULTATION SERVICES™

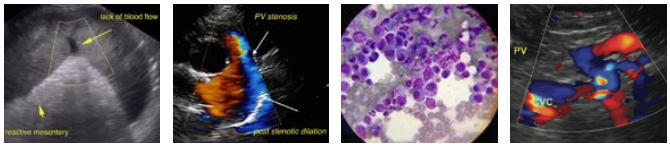

SonoPath.com™
1-800-838-4268 info@sonopath.com

PATIENT

Charlie Shapiro

SPECIES

Canine

BREED

Cockapoo

SEX

Neutered male

AGE

8 years

WEIGHT

NA

INTERPRETED BY

Eric Lindquist, DMV
DABVP, Cert. IVUSS

IMAGING PERFORMED BY

Jessica Miller, RDMS

HOSPITAL NAME

Basking Ridge AH

REFERRING VET

Dr. Hollo

INVOICE

42216

DATE

1/18/23

Pancreas

The base and limbs of the **pancreas** were observed to be largely isoechoic to surrounding omental fat. Some parenchymal remodeling, however, with mild deviation from curvilinear normalcy was observed. Pancreatic duct and capsular irregularities were present consistent with age related changes. If pain upon imaging (+ Murphy sign) was present or if the patient is focally painful in subxiphoid palpation then low-grade smoldering chronic pancreatitis should be suspected.

ULTRASONOGRAPHIC FINDINGS

Right renal nodule with right renal capsular swelling and adjacent free fluid. Differentials include metastatic or primary neoplasia, nodular hyperplasia or resolving abscess.
Hepatic cyst.
Partially full stomach.
Age related pancreatic changes.

INTERPRETATION OF THE FINDINGS & FURTHER RECOMMENDATIONS

The Prednisone is likely suppressing a more significant presentation. However, the reactive mesentery associated with the small intestine and right renal nodule is concerning for signs of partial suppression of a Prednisone responsive process. Ultrasound-guided FNA of the nodule in the right kidney can be considered; however, the region is moderately vascular and may be challenging to access, yet may be attempted. Ultrasound-guided drainage and culture of the cystic structure in the left medial liver would also be appropriate.

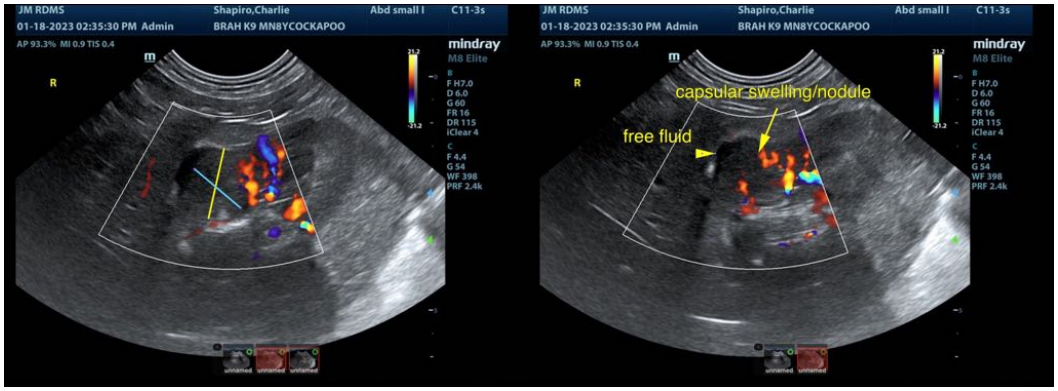

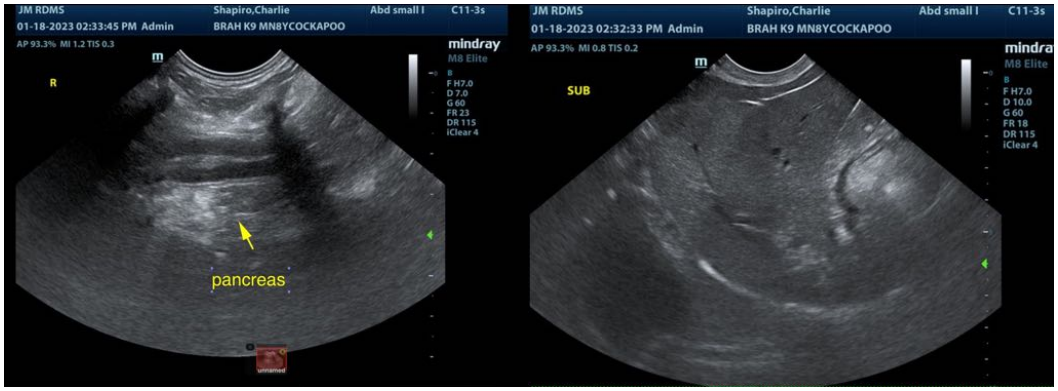

SonoPath

Clinical Sonography & Telecytology

EDUCATIONAL TELECONSULTATION SERVICES™

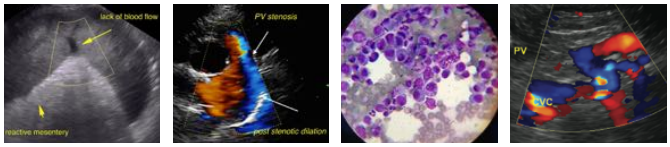

SonoPath.com™
1-800-838-4268 info@sonopath.com

PATIENT

Charlie Shapiro

SPECIES

Canine

BREED

Cockapoo

SEX

Neutered male

AGE

8 years

WEIGHT

NA

INTERPRETED BY

Eric Lindquist, DMV
DABVP, Cert. IVUSS

IMAGING PERFORMED BY

Jessica Miller, RDMS

HOSPITAL NAME

Basking Ridge AH

REFERRING VET

Dr. Hollo

INVOICE

42216

DATE

1/18/23

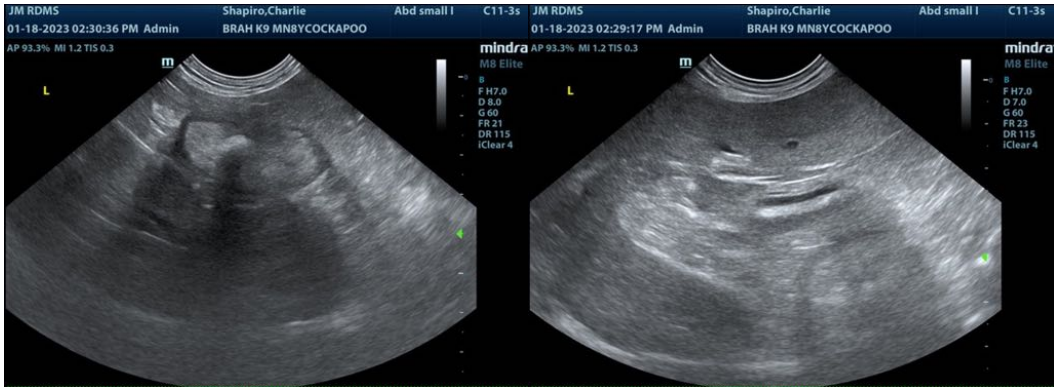

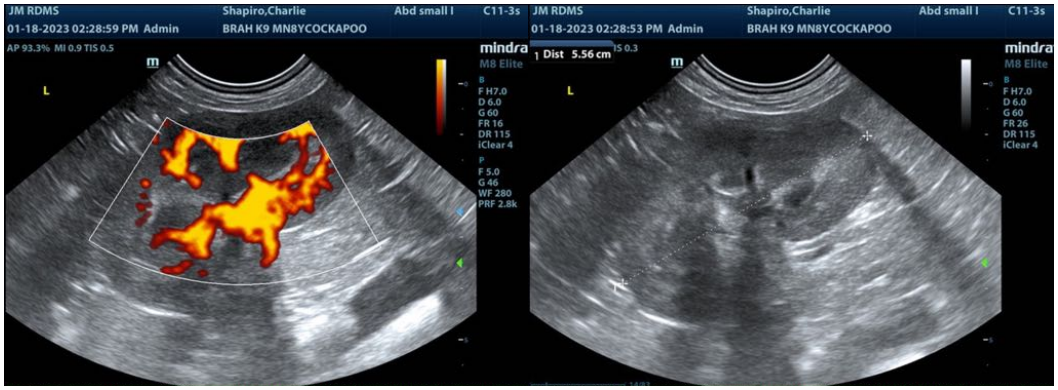

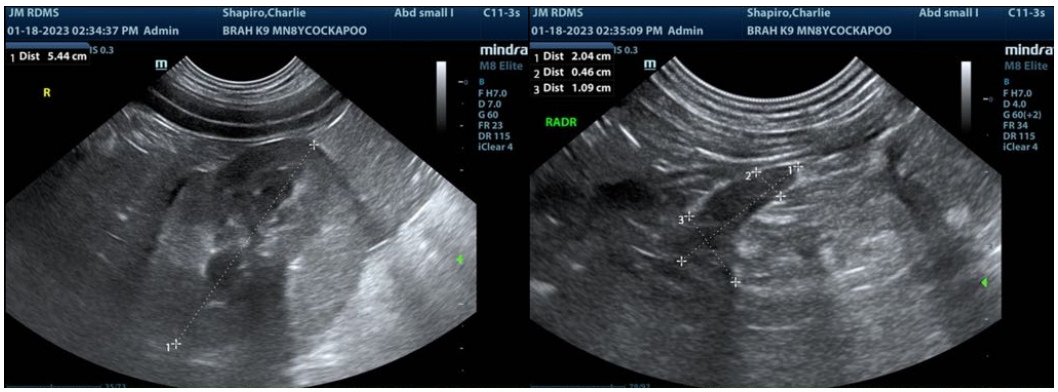

SonoPath
Clinical Sonography & Telecytology

EDUCATIONAL TELECONSULTATION SERVICES™

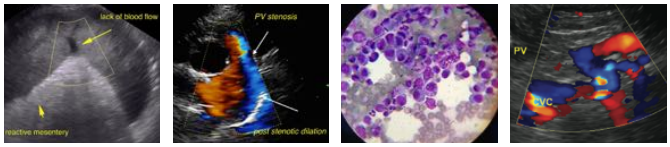

SonoPath.com™
1-800-838-4268 info@sonopath.com

PATIENT

Charlie Shapiro

SPECIES

Canine

BREED

Cockapoo

SEX

Neutered male

AGE

8 years

WEIGHT

NA

INTERPRETED BY

Eric Lindquist, DMV
DABVP, Cert. IVUSS

IMAGING PERFORMED BY

Jessica Miller, RDMS

HOSPITAL NAME

Basking Ridge AH

REFERRING VET

Dr. Hollo

INVOICE

42216

DATE

1/18/23

The information and recommendations provided are based on the images presented by the referring veterinarian/sonographer. No evaluation can be communicated regarding pathology that was not visible in the image/video clips provided.

Thank you for this referral. If the clinical or image interpretation does not parallel your findings or if I can be of any further assistance please contact me.

Eric Lindquist, DMV, DABVP, Cert. IVUSS, CEO of SonoPath.com
info@SonoPath.com