



**PATIENT**

Lucy Kountry Kennels

**PRESENTING CLINICAL SIGNS**

History: Found as stray, pregnancy check.

**SPECIES**

Canine

**ULTRASONOGRAPHIC EXAMINATION OF THE ABDOMEN**

The left ovary was uniform and measured 0.88 cm. The right ovary was uniform and measured 0.22 cm. The uterus was uniform and measured 0.4 cm. A trace amount of fluid was noted in the uterine body.

**BREED**

Beagle

The **kidneys** revealed normal size and structure, corticomedullary definition and ratio for this age. The cortices presented largely uniform texture with normal echogenic relationship to liver and spleen. Medullary structure differed distinctly from the cortex and no evidence of pelvic dilation was present. The capsules were acceptably uniform without significant irregularities.

**SEX**

Female

Both **adrenal glands** were visualized and recognized as having normal shape, size, position and echogenicity for this breed. The phrenic vasculature, glandular echogenicity and detail were unremarkable. Capsule, cortex, and medullary definition were normal for this age patient.

**AGE**

3 years

**ULTRASONOGRAPHIC FINDINGS**

Essentially normal reproductive tract with slight uterine fluid.

**WEIGHT**

**INTERPRETATION OF THE FINDINGS & FURTHER RECOMMENDATIONS**

I cannot rule out emerging metritis or active heat cycle. However, there was no evidence of pathology. If the patient is not destined for reproductive activity ovariohysterectomy is recommended.

**INTERPRETED BY**

Eric Lindquist, DMV  
DABVP, Cert. IVUSS

**IMAGING PERFORMED BY**

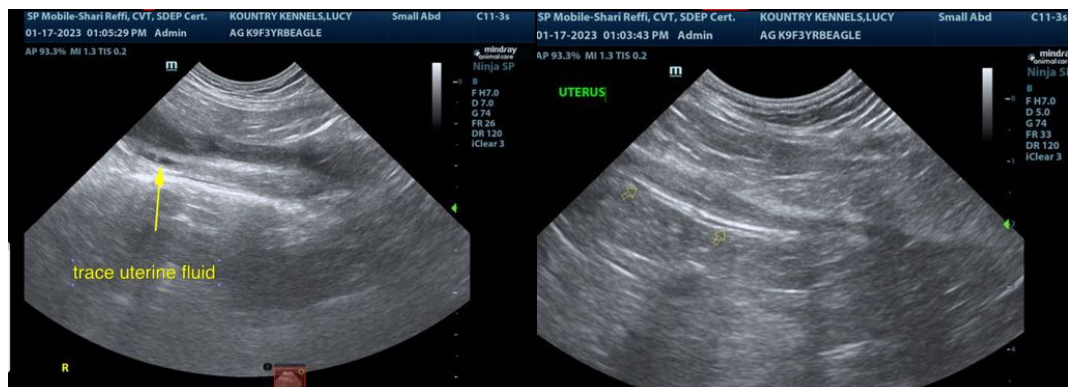
Shari Reffi, CVT

**HOSPITAL NAME**

Animal General  
Augusta

**REFERRING VET**

Dr. Castimore



**INVOICE**

42189

**DATE**

1/17/23



**PATIENT**

Lucy Kountry Kennels

**SPECIES**

Canine

**BREED**

Beagle

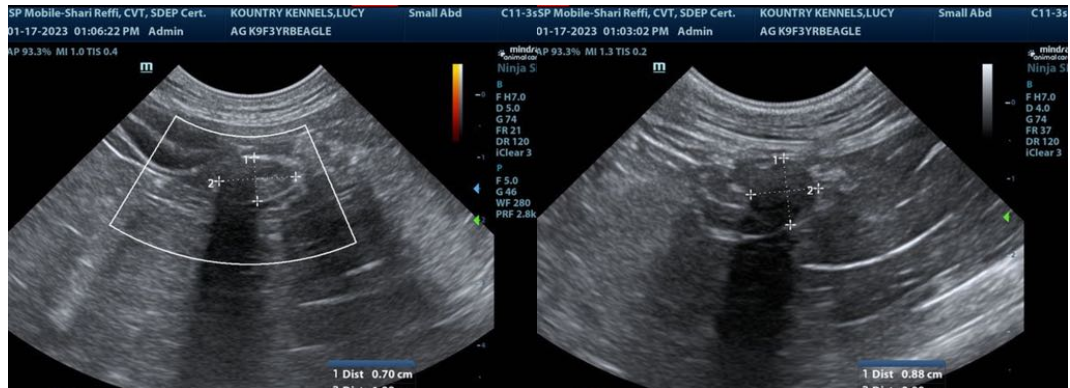
**SEX**

Female

**AGE**

3 years

**WEIGHT**



The information and recommendations provided are based on the images presented by the referring veterinarian/sonographer. No evaluation can be communicated regarding pathology that was not visible in the image/video clips provided.

Thank you for this referral. If the clinical or image interpretation does not parallel your findings or if I can be of any further assistance please contact me.

**Eric Lindquist**, DMV, DABVP, Cert. IVUSS, CEO of SonoPath.com  
Info@SonoPath.com

**INTERPRETED BY**

Eric Lindquist, DMV  
DABVP, Cert. IVUSS

**IMAGING PERFORMED BY**

Shari Reffi, CVT

**HOSPITAL NAME**

Animal General  
Augusta

**REFERRING VET**

Dr. Castimore

**INVOICE**

42189

**DATE**

1/17/23