


**PATIENT**

Blue O'Shaughnessy

**PRESENTING CLINICAL SIGNS**

Mitral valve disease, congenital defect.

**SPECIES**

Canine

**ULTRASONOGRAPHIC EXAMINATION OF THE HEART**

The echocardiogram in this patient presented normal left atrial and left ventricular volumes. Persistent club anterior mitral valve leaflet with elongated papillaries and a somewhat tethered septal leaflet. Severe mitral insufficiency was noted, yet was contained at this time and adequately compensated. The left ventricular outflow velocity was mildly excessive and likely compensatory. The contractility in all four chambers was normal. There was no pericardial or pleural effusion noted. There was no evidence of volume overload.

**BREED**

Goldendoodle

**SEX**

Male

**AGE**

3 years

<b>CANINE CARDIAC PARAMETERS</b>	<b>MR VMAX (m/s)</b>	<b>TR VMAX (m/s)</b>	<b>LA/AO (Boon method)</b>	<b>LA/AO (Heart Base; Swe)</b>	<b>FS (%)</b>	<b>EF (%)</b>	<b>EPSS (cm)</b>
<b>NORMAL PARAMETER</b>	4.5-5.5	<2.7	1.3	<1.6	28-40	40-100	<0.6
<b>PATIENT</b>	6.22		1.1	1.5	41	73	0.4
<b>CANINE CARDIAC PARAMETERS</b>	<b>HR (BPM)</b>	<b>AV VMAX (m/s)</b>	<b>PV MAX (m/s)</b>	<b>BODY WEIGHT (kg)</b>	<b>LA 2D short axis Base view (cm)</b>	<b>LVIDd Avg; 2D and m- mode short axis (cm)</b>	<b>LVIDs Avg; 2D and m- mode short axis (cm)</b>
<b>NORMAL PARAMETER</b>	50-100	0.7-1.7	0.7-1.6	BELOW	BELOW	BELOW	BELOW
<b>PATIENT</b>	131	2.02	0.99		4.44	4.2	

**INTERPRETED BY**

 Eric Lindquist, DMV  
 DABVP, Cert. IVUSS

**IMAGING  
PERFORMED BY**

 Eric Lindquist, DMV  
 DABVP, Cert. IVUSS

**HOSPITAL NAME**

Franklin Lakes AH

**ULTRASONOGRAPHIC FINDINGS**

Compensated mitral valve dysplasia.

**REFERRING VET**

Dr. Greenhut

**INTERPRETATION OF THE FINDINGS & FURTHER RECOMMENDATIONS**

No treatment is recommended at this time. Interventional cardiologist evaluation can be considered in this patient in case any surgical intervention can be considered. However, at this time no medical therapy is recommended. A recheck echocardiogram is recommended in 6-12 months.

**INVOICE**

42070

**DATE**

1/12/23



**PATIENT**

Blue O'Shaughnessy

**SPECIES**

Canine

**BREED**

Goldendoodle

**SEX**

Male

**AGE**

3 years

**INTERPRETED BY**

Eric Lindquist, DMV  
DABVP, Cert. IVUSS

**IMAGING PERFORMED BY**

Eric Lindquist, DMV  
DABVP, Cert. IVUSS

**HOSPITAL NAME**

Franklin Lakes AH

**REFERRING VET**

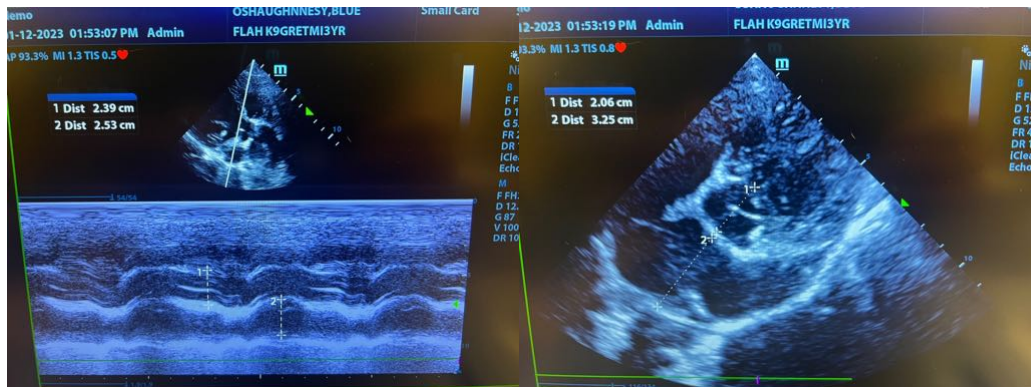
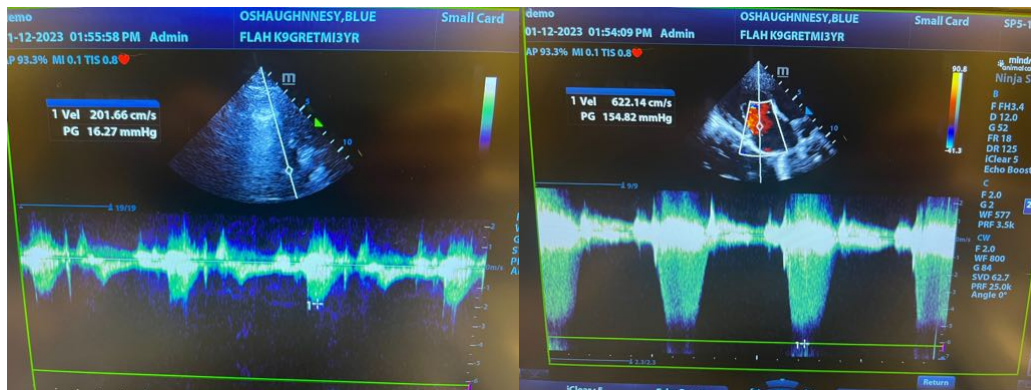
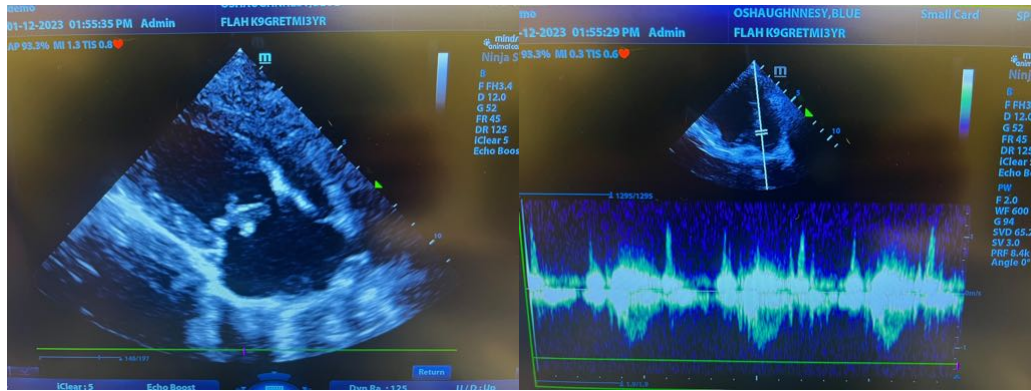
Dr. Greenhut

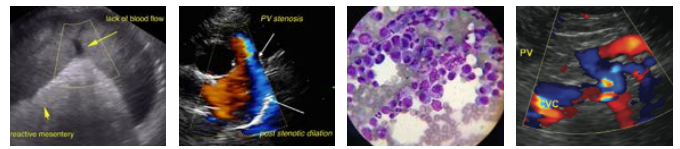
**INVOICE**

42070

**DATE**

1/12/23





**PATIENT**

Blue O'Shaughnessy

**SPECIES**

Canine

**BREED**

Goldendoodle

**SEX**

Male

**AGE**

3 years

**INTERPRETED BY**

Eric Lindquist, DMV  
DABVP, Cert. IVUSS

**IMAGING PERFORMED BY**

Eric Lindquist, DMV  
DABVP, Cert. IVUSS

**HOSPITAL NAME**

Franklin Lakes AH

**REFERRING VET**

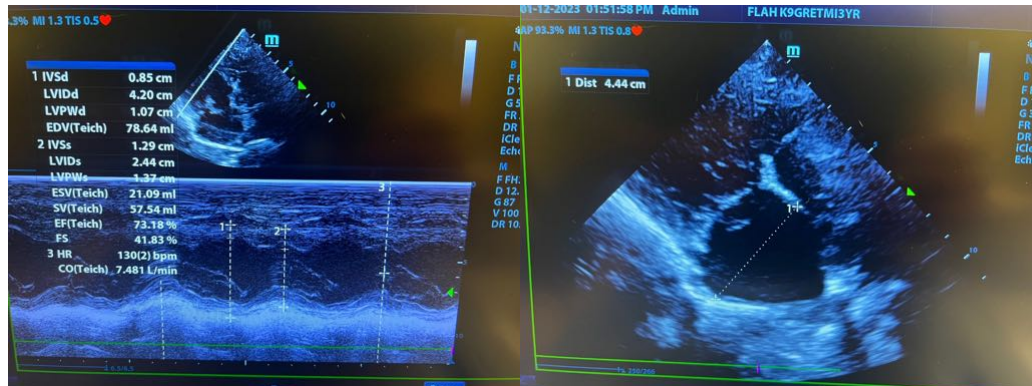
Dr. Greenhut

**INVOICE**

42070

**DATE**

1/12/23



The information and recommendations provided are based on the images presented by the referring veterinarian/sonographer. No evaluation can be communicated regarding pathology that was not visible in the image/video clips provided.

Thank you for this referral. If the clinical or image interpretation does not parallel your findings or if I can be of any further assistance please contact me.

**Eric Lindquist, DMV, DABVP, Cert. IVUSS, CEO of SonoPath.com**  
Info@SonoPath.com