



PATIENT

Dala Vancheri

SPECIES

Canine

BREED

Chihuahua

SEX

Spayed female

AGE

10 years

WEIGHT

17 lbs

INTERPRETED BY

Eric Lindquist, DMV,
DABVP (CFM), Cert.
IVUSS, CEO of
SonoPath.com

IMAGING PERFORMED BY

Kerri Becker

HOSPITAL NAME

Legacy AH

REFERRING VET

Dr. Pontenzone

INVOICE

78258

DATE

6/2/26

PRESENTING CLINICAL SIGNS

History: Last echo 11/7/2025. Recheck heart status
Pimo5mg 1/4 bid. Taurin/COQ10

ULTRASONOGRAPHIC EXAMINATION OF THE HEART

The echocardiogram in this patient demonstrated upper limits of normal **left atrial** size. Chamber volumes and echogenicity were normal. The cranial and caudal **mitral** valve leaflets presented vegetative thickening consistent with endocardiosis. Prolapse of the anterior mitral valve leaflet was noted. Doppler indicated measurable insufficiency. The **left ventricle** presented normal thicknesses with linear contour and was not dilated nor restricted. The **myocardium** presented normal echogenicity without subjective evidence of significant fibrotic or ischemic disease. **Contractility** of the ventricular walls was adequate and in normal range for this patient evidenced by the fractional shortening measurement and subjective evaluation of the different regions of the myocardium. The **left ventricular outflow** tract demonstrated normal laminar flow and subjective structural integrity. The **right atrium** and auricle revealed normal size, structure and content. No evidence of masses was noted or chamber overload. **Tricuspid** valvular assessment demonstrated adequate linear morphology. The **right ventricle** was of normal size (1/3 diameter of LV), chordae structure, myocardial echogenicity and thickness. **Pulmonic** tract assessment revealed normal valve structure, laminar flow, and diameter (approx. 1:1 pa/ao ratio). No visible **pericardial** or free pleura fluid was noted. No echographically detectable evidence of infiltrative disease was visible. The cranial **mediastinum and pericardial regions** were free of masses in the visible window. Arrhythmogenic activity is noted.

CANINE CARDIAC PARAMETERS	MR VMAX (m/s)	TR VMAX (m/s)	LA/AO	LA/AO (Heart Base)	FS (%)	EF (%)	EPSS (cm)
NORMAL PARAMETER	4.5-5.5	<2.7	1.3	<1.6	28-40	40-100	<0.6
PATIENT	6.0		1.44	1.4	41	74	NM
CANINE CARDIAC PARAMETERS	HR (BPM)	AV VMAX (m/s)	PV MAX (m/s)	BODY WEIGHT	LA 2D short axis Base view (cm)	LVIDd Avg; 2D and m-mode short axis (cm)	LVIDs Avg; 2D and m-mode short axis (cm)
NORMAL PARAMETER	50-100	0.7-1.7	0.7-1.6	BELOW	BELOW	BELOW	BELOW
PATIENT	169	1.8	1.2	17 lbs	2.9	2.84	

ULTRASONOGRAPHIC FINDINGS

Compensated stage B2 valvular disease.



PATIENT

Dala Vancheri

SPECIES

Canine

BREED

Chihuahua

SEX

Spayed female

AGE

10 years

WEIGHT

17 lbs

INTERPRETED BY

Eric Lindquist, DMV,
 DABVP (CFM), Cert.
 IVUSS, CEO of
 SonoPath.com

IMAGING PERFORMED BY

Kerri Becker

HOSPITAL NAME

Legacy AH

REFERRING VET

Dr. Pontenzone

INVOICE

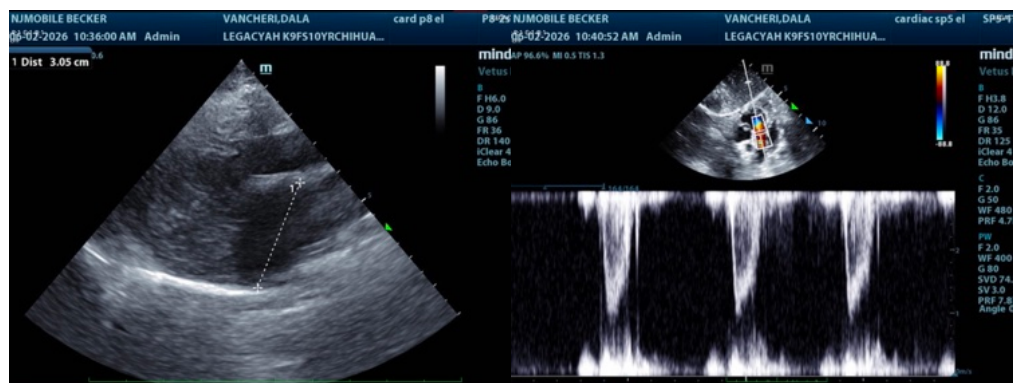
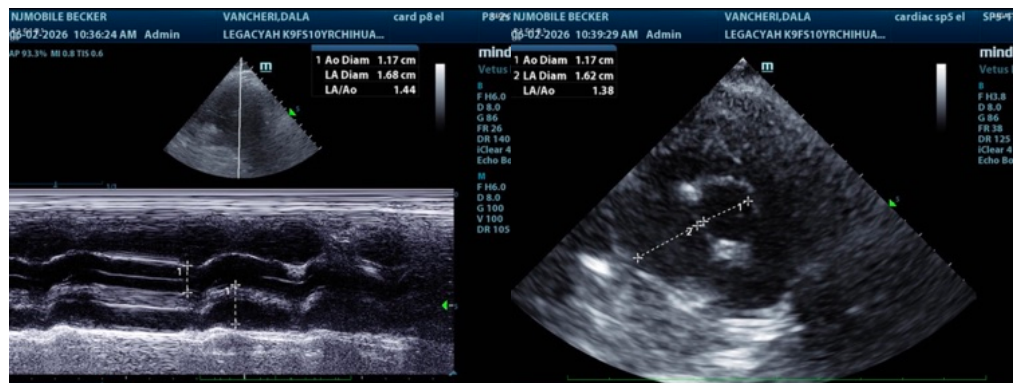
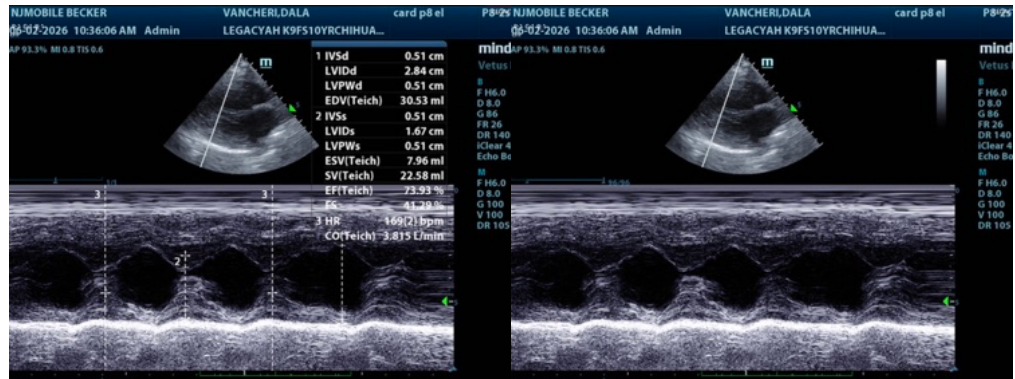
78258

DATE

6/2/26

INTERPRETATION OF THE FINDINGS & FURTHER RECOMMENDATIONS

EKG is indicated to ensure that this is a benign sinus arrhythmia. Blood pressure measurements are indicated. I recommend continuation of the current protocol. Recheck echocardiogram is recommended in 6-12 months or earlier if murmur grade increases. Blood pressure and EKG are indicated if not already performed.





PATIENT

Dala Vancheri

SPECIES

Canine

BREED

Chihuahua

SEX

Spayed female

AGE

10 years

WEIGHT

17 lbs

INTERPRETED BY

Eric Lindquist, DMV,
 DABVP (CFM), Cert.
 IVUSS, CEO of
 SonoPath.com

IMAGING PERFORMED BY

Kerri Becker

HOSPITAL NAME

Legacy AH

REFERRING VET

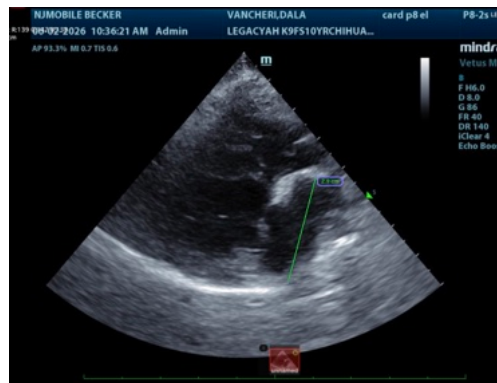
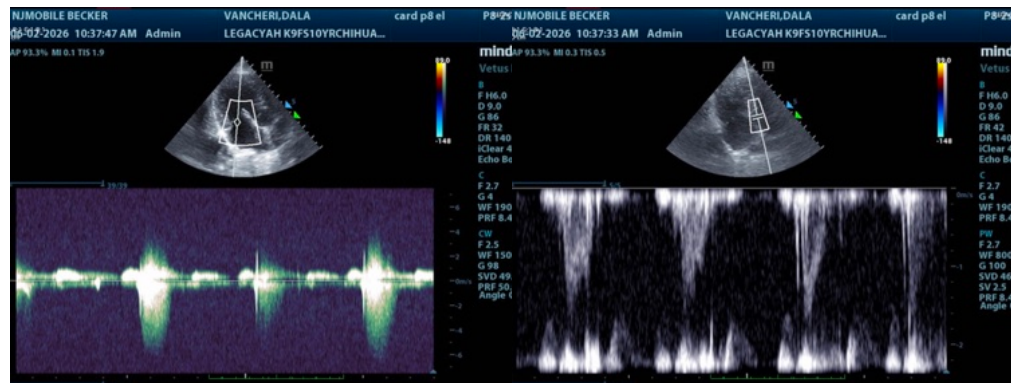
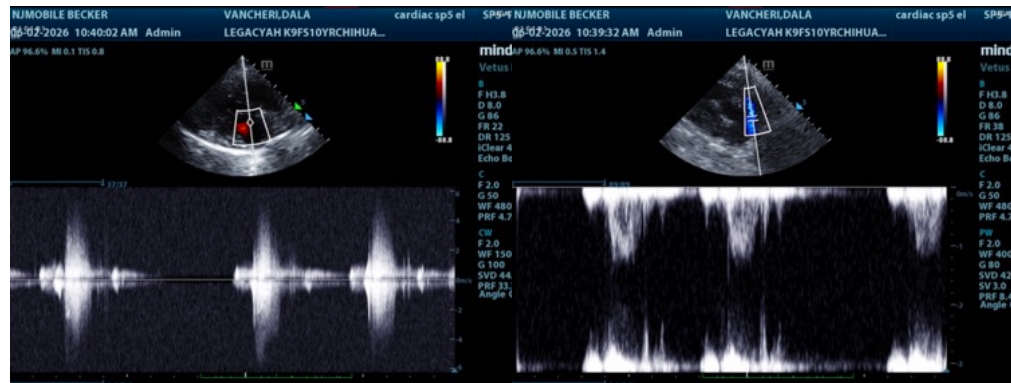
Dr. Pontenzone

INVOICE

78258

DATE

6/2/26



The information and recommendations provided are based on the images presented by the referring veterinarian/sonographer. No evaluation can be communicated regarding pathology that was not visible in the image/video clips provided.

Thank you for this referral. If the clinical or image interpretation does not parallel your findings or if I can be of any further assistance please contact me.

Eric Lindquist, DMV, DABVP (CFM), Cert. IVUSS, CEO of SonoPath.com

Info@SonoPath.com