



PATIENT

Pepper Gensinger

SPECIES

Feline

BREED

Domestic Shorthair

SEX

Neutered male

AGE

6 years

WEIGHT

11 lbs

INTERPRETED BY

Eric Lindquist, DMV
DABVP, Cert. IVUSS

IMAGING PERFORMED BY

Dr. Ken Leal

HOSPITAL NAME

VCA Blairstown AH

REFERRING VET

Dr. Clegg

INVOICE

78038

DATE

5/18/26

PRESENTING CLINICAL SIGNS

History: Concern for HCM. Seen on ER , cardiomegaly on X-rays from ER vet Cat is healthy otherwise on physical exam.

No current medications.

Abnormal PE/Chem/CBC/UA Results: Lab work WNL

ULTRASONOGRAPHIC EXAMINATION OF THE HEART

The echocardiogram in this patient demonstrated normal **left atrial** size based on 3 separate LA measurements. The cranial and caudal **mitral** valve leaflets presented normal linear structure and kinetics.. The **left ventricle** presented normal thicknesses with linear contour and was not dilated nor restricted. The **myocardium** presented normal echogenicity without subjective evidence of significant fibrotic or ischemic disease. **Contractility** of the ventricular walls was adequate and in normal range for this patient evidenced by the fractional shortening measurement and subjective evaluation of the different regions and angles of the myocardium. The **left ventricular outflow** tract demonstrated normal laminar flow and subjective structural integrity. The **right atrium** and auricle revealed normal size, structure and content. No evidence of masses was noted or chamber overload. Trivial **tricuspid** insufficiency was noted in this patient. The **right ventricle** was of normal size (1/3 diameter of LV), chordae structure, myocardial echogenicity and thickness. **Pulmonic** tract assessment revealed normal valve structure, laminar flow, and diameter (approx. 1:1 pa/ao ratio). No visible **pericardial** or free pleura fluid was noted or extra cardiac pathology in the visible planes. The cranial **mediastinum and pericardial regions** were free of masses in the visible window.

E Wave Velocity 1.2 m/sec.

FELINE CARDIAC PARAMETERS	BODY WEIGHT	HR (BPM)	IVSd (cm)	LVIDd (cm)	LVWd (cm)	FS (%)	EF (%)
NORMAL PARAMETER	-----	150-240	0.3-0.6	1.0-2.1	0.25-0.6	35-67	80-100
PATIENT	11 lbs	165	0.44	1.69	0.38	56	89
FELINE CARDIAC PARAMETERS	LA/AO (M-mode)	LA/AO HEART BASE (Sisson)	LAD LA MAX 4 Chamber		LVOT VEL. (m/s)	RVOT VEL. (m/s)	IVRT (m/)
NORMAL PARAMETER	<1.5	1.6	0.7-1.7		<1.6	<1.3	40-60
PATIENT		1.3	1.3		1.56	1.31	NM

Adapted from June Boon, Veterinary Echocardiography, 1998
Sisson D et al. JVIM 1991; 5: 232, Jacobs et al. Am J Vet Res 1985; 46:1705

ULTRASONOGRAPHIC FINDINGS

- Normal echocardiogram.



PATIENT

Pepper Gensinger

SPECIES

Feline

BREED

Domestic Shorthair

SEX

Neutered male

AGE

6 years

WEIGHT

11 lbs

INTERPRETED BY

Eric Lindquist, DMV
 DABVP, Cert. IVUSS

IMAGING PERFORMED BY

Dr. Ken Leal

HOSPITAL NAME

VCA Blairstown AH

REFERRING VET

Dr. Clegg

INVOICE

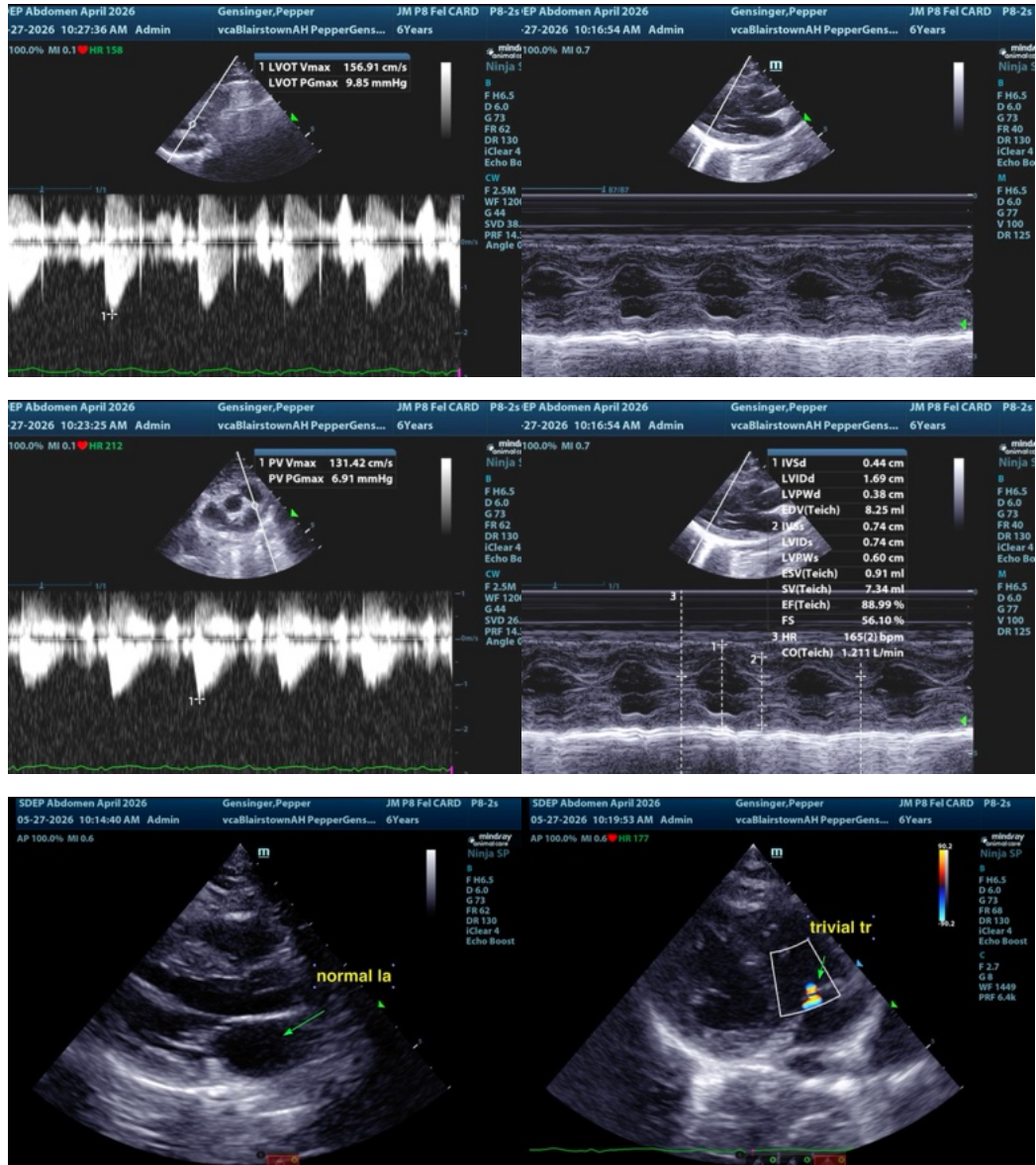
78038

DATE

5/18/26

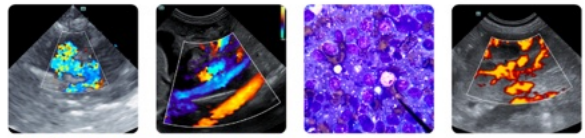
INTERPRETATION OF THE FINDINGS & FURTHER RECOMMENDATIONS

There was no evidence of volume overload or pressure overload.



The information and recommendations provided are based on the images presented by the referring veterinarian/sonographer. No evaluation can be communicated regarding pathology that was not visible in the image/video clips provided.

Thank you for this referral. If the clinical or image interpretation does not parallel your findings or if I can be of any further assistance please contact me.



PATIENT

Pepper Gensinger

Eric Lindquist, DMV, DABVP, Cert. IVUSS, CEO of SonoPath.com

info@SonoPath.com

SPECIES

Feline

BREED

Domestic Shorthair

SEX

Neutered male

AGE

6 years

WEIGHT

11 lbs

INTERPRETED BY

Eric Lindquist, DMV
DABVP, Cert. IVUSS

**IMAGING
PERFORMED BY**

Dr. Ken Leal

HOSPITAL NAME

VCA Blirstown AH

REFERRING VET

Dr. Clegg

INVOICE

78038

DATE

5/18/26