



PATIENT

Roky Baysan

SPECIES

Canine

BREED

Yorkie

SEX

Neutered male

AGE

14 years

WEIGHT

9 lbs

INTERPRETED BY

Eric Lindquist, DMV
DABVP, Cert. IVUSS

IMAGING PERFORMED BY

Rebecca Hamilton

HOSPITAL NAME

All Creatures Great
and Small

REFERRING VET

Dr. Ashmore

INVOICE

77969

DATE

5/26/26

PRESENTING CLINICAL SIGNS

History: 3 possible syncope episodes in 2 days. Heart murmur grade 4/6

ULTRASONOGRAPHIC EXAMINATION OF THE HEART

The echocardiogram in this patient demonstrated severely enlarged **left atrial** size based on 3 different LA measurement methods. Chamber volumes and echogenicity were normal. The cranial and caudal **mitral** valve leaflets presented vegetative thickening consistent with endocardiosis. Prolapse of the anterior mitral valve leaflet was noted. Doppler indicated measurable insufficiency. Ruptured chordae tendineae is evident. The **left ventricle** presented normal thicknesses with linear contour and was not dilated nor restricted. The **myocardium** presented normal echogenicity without subjective evidence of significant fibrotic or ischemic disease. **Contractility** of the ventricular walls was adequate and in normal range for this patient evidenced by the fractional shortening measurement and subjective evaluation of the different regions of the myocardium. The **left ventricular outflow** tract demonstrated normal laminar flow and subjective structural integrity. The **right atrium** and auricle revealed normal size, structure and content. No evidence of masses was noted or chamber overload. **Tricuspid** valvular assessment demonstrated adequate linear morphology. The **right ventricle** was of normal size (1/3 diameter of LV), chordae structure, myocardial echogenicity and thickness. **Pulmonic** tract assessment revealed normal valve structure, laminar flow, and diameter (approx. 1:1 pa/ao ratio). No visible **pericardial** or free pleura fluid was noted. No echographically detectable evidence of infiltrative disease was visible. The cranial **mediastinum and pericardial regions** were free of masses in the visible window.

CANINE CARDIAC PARAMETERS	MR VMAX (m/s)	TR VMAX (m/s)	LA/AO	LA/AO (Heart Base)	FS (%)	EF (%)	EPSS (cm)
NORMAL PARAMETER	4.5-5.5	<2.7	1.3	<1.6	28-40	40-100	<0.6
PATIENT	5.5	-	2.0	2.02	56	88	NM
CANINE CARDIAC PARAMETERS	HR (BPM)	AV VMAX (m/s)	PV MAX (m/s)	BODY WEIGHT	LA 2D short axis Base view (cm)	LVIDd Avg; 2D and m-mode short axis (cm)	LVIDs Avg; 2D and m-mode short axis (cm)
NORMAL PARAMETER	50-100	0.7-1.7	0.7-1.6	BELOW	BELOW	BELOW	BELOW
PATIENT	179	1.0	0.62	9 lbs	3.3	2.92	-

ULTRASONOGRAPHIC FINDINGS

Ruptured chordae tendineae
Stage C1 valvular disease.



PATIENT

Roky Baysan

SPECIES

Canine

BREED

Yorkie

SEX

Neutered male

AGE

14 years

WEIGHT

9 lbs

INTERPRETED BY

Eric Lindquist, DMV
 DABVP, Cert. IVUSS

IMAGING PERFORMED BY

Rebecca Hamilton

HOSPITAL NAME

All Creatures Great
 and Small

REFERRING VET

Dr. Ashmore

INVOICE

77969

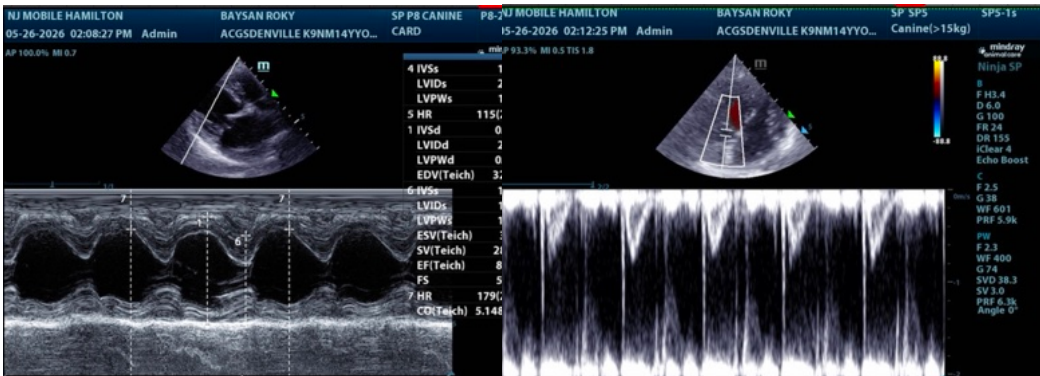
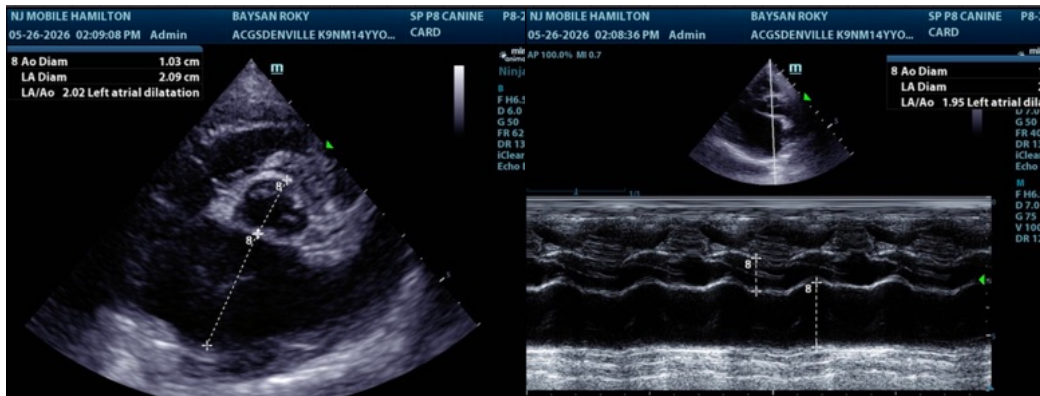
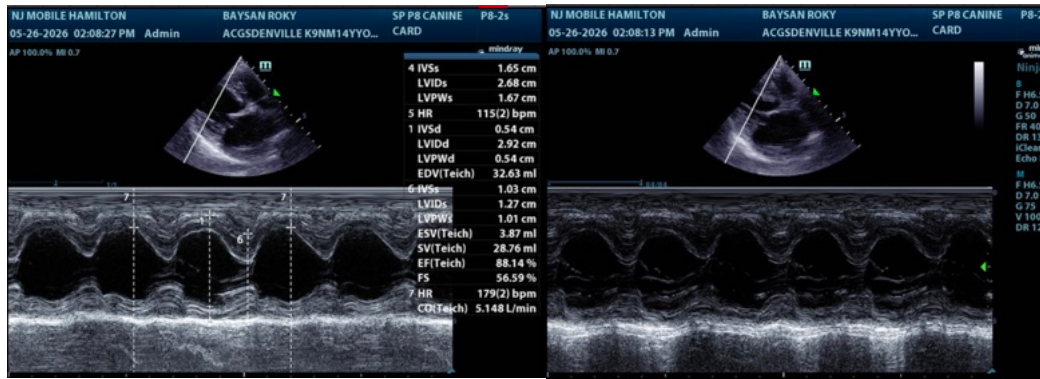
DATE

5/26/26

INTERPRETATION OF THE FINDINGS & FURTHER RECOMMENDATIONS

Pimobendan is indicated at 0.3 mg/kg b.i.d. Ace inhibitor is recommended at 0.5 mg/kg s.i.d. progressing to b.i.d. and Lasix at 2-3 mg/kg b.i.d., Spironolactone at 1-2 mg/kg s.i.d. Prognosis is guarded.

The heart is in a somewhat precarious state with volume overload and a heart that is working to compensate for the valvular insufficiency. Target respiratory rate is < 20 resp/minute after therapy. After initiating therapy, I recommend recheck on the clinical exam, BUN, Creatinine, USG, Chest radiographs & Blood pressure in 5-7 days. Recheck echo in 1 month. Earlier if clinical decompensation is occurring. I do not recommend anesthesia at this time until stabilization has occurred on the recommended medications. Repeat preanesthetic echo is ideal if anesthesia is eventually necessary.





PATIENT

Roky Baysan

SPECIES

Canine

BREED

Yorkie

SEX

Neutered male

AGE

14 years

WEIGHT

9 lbs

INTERPRETED BY

Eric Lindquist, DMV
 DABVP, Cert. IVUSS

IMAGING PERFORMED BY

Rebecca Hamilton

HOSPITAL NAME

All Creatures Great
 and Small

REFERRING VET

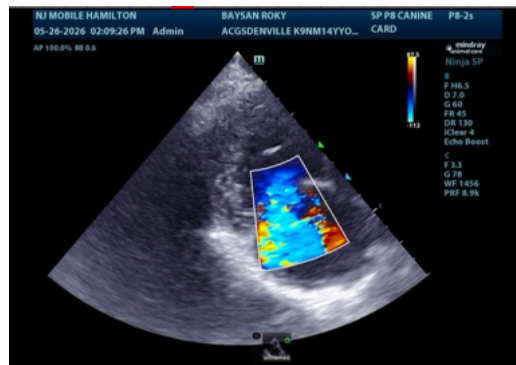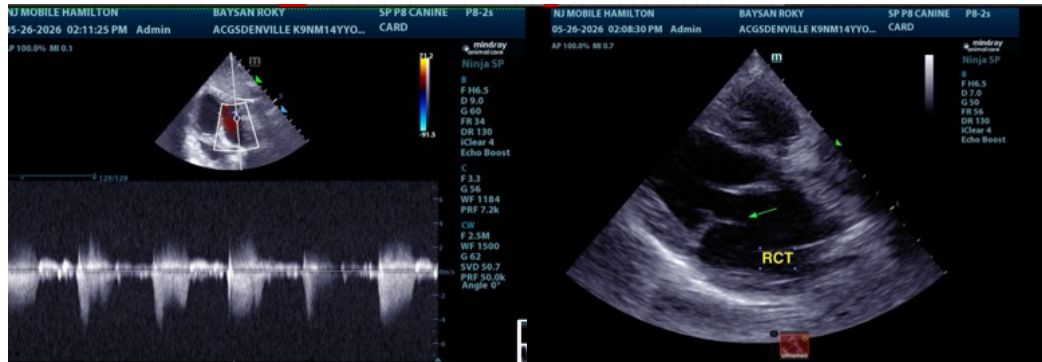
Dr. Ashmore

INVOICE

77969

DATE

5/26/26



The information and recommendations provided are based on the images presented by the referring veterinarian/sonographer. No evaluation can be communicated regarding pathology that was not visible in the image/video clips provided.

Thank you for this referral. If the clinical or image interpretation does not parallel your findings or if I can be of any further assistance please contact me.

Eric Lindquist, DMV, DABVP, Cert. IVUSS, CEO of SonoPath.com

info@SonoPath.com