



PATIENT

Max Fonseca

SPECIES

Canine

BREED

GoldenRetriever

SEX

Intact male

AGE

11 year

WEIGHT

51 lbs

INTERPRETED BY

Eric Lindquist, DMV
 DABVP, Cert. IVUSS

IMAGING PERFORMED BY

Rebecca Hamilton

HOSPITAL NAME

All Creatures Great
 and Small Denville

REFERRING VET

Dr. Ashmore

INVOICE

77970

DATE

5/26/26

PRESENTING CLINICAL SIGNS

History: Routine echo and abdomen u/s pre surgery. possible left testicle mass vs. orchitis. Meds: Clavamox

ULTRASONOGRAPHIC EXAMINATION OF THE HEART

The echocardiogram in this patient demonstrated normal **left atrial** size based on 3 separate methods of LA evaluation. The cranial and caudal **mitral** valve leaflets presented normal linear structure, extension in systole, and union in diastole with normal kinesis. The **left ventricle** presented thicknesses with linear contour and was not dilated nor restricted. The **myocardium** presented normal echogenicity without subjective evidence of significant fibrotic or ischemic disease. **Contractility** of the ventricular walls was adequate and in normal range for this patient evidenced by the fractional shortening measurement and subjective evaluation of the different regions of the myocardium. The **left ventricular outflow** tract demonstrated normal laminar flow and subjective structural integrity. The **right atrium** and auricle revealed normal size, structure and content. No evidence of masses was noted. **Tricuspid** valvular assessment demonstrated adequate linear morphology and kinesis. The **right ventricle** was of normal size (1/3 diameter of LV), chordae structure, myocardial echogenicity and thickness. **Pulmonary outflow** tract assessment revealed normal valve structure, laminar flow, and diameter (approx.1:1 pa/ao ratio). No visible **pericardial** or free pleura fluid was noted. The cranial **mediastinum and pericardial and extra-cardiac regions** were free of masses in the visible window.

CANINE CARDIAC PARAMETERS	MR VMAX (m/s)	TR VMAX (m/s)	LA/AO	LA/AO (Heart Base)	FS (%)	EF (%)	EPSS (cm)
NORMAL PARAMETER	4.5-5.5	<2.7	1.3	<1.6	28-40	40-100	<0.6
PATIENT	-	-	1.2	1.4	23	47	0.1
CANINE CARDIAC PARAMETERS	HR (BPM)	AV VMAX (m/s)	PV MAX (m/s)	BODY WEIGHT	LA 2D short axis Base view (cm)	LVIDd Avg; 2D and m-mode short axis (cm)	LVIDs Avg; 2D and m-mode short axis (cm)
NORMAL PARAMETER	50-100	0.7-1.7	0.7-1.6	BELOW	BELOW	BELOW	BELOW
PATIENT	80	1.3	1.0	51 lbs	3.9	4.05	



PATIENT

Max Fonseca

SPECIES

Canine

BREED

GoldenRetriever

SEX

Intact male

AGE

11 year

WEIGHT

51 lbs

INTERPRETED BY

Eric Lindquist, DMV
DABVP, Cert. IVUSS

IMAGING PERFORMED BY

Rebecca Hamilton

HOSPITAL NAME

All Creatures Great
and Small Denville

REFERRING VET

Dr. Ashmore

INVOICE

77970

DATE

5/26/26

ULTRASONOGRAPHIC EXAMINATION OF THE ABDOMEN

Urinary System

The **urinary bladder**, trigone, and pelvic urethra presented normal thicknesses and normal tone. The ureters were not visible which is normal. No uroliths or sediment were visualized and anechoic urine was present. No evidence of inflammatory or neoplastic changes was noted. Ureteral papillae were normal.

The **kidneys** revealed largely normal size and structure, corticomedullary definition and ratio (cortex 1/3 of medulla) were essentially maintained with some age-related loss of curvilinear patterns regarding the capsule and C/M junction. The cortices presented largely uniform texture with some increased echogenicity expected for this age patient. Medullary structure differed distinctly from that of the cortex and no evidence of pelvic dilation was present. The right kidney measured 6.7 cm. The left kidney measured 7.1 cm.

The **prostate** was uniformly enlarged with lobar swelling appeared to impinge upon the urethra and mildly deviate the descending colon. The prostatic tissue was hyperechoic containing focal areas of decreased echogenicity. These changes are suggestive of either chronic inflammatory episodes, benign cystic pathology or both. Underlying neoplasia cannot be completely ruled-out but is lower on the differential list. This presentation is most consistent with benign prostatic hyperplasia with possible active prostatitis. Neutering or off-label Finasteride (Propecia) (0.1-0.5 mg/kg Sid) treatment is indicated +/- FNA or prostatic wash cytology and culture. The prostate measured 3.8 cm.

The left testicle revealed a complete tumor transformation measuring 0.9 cm. The right testicle was unremarkable and uniform.

Adrenal Glands

Both **adrenal glands** were visualized and recognized as having normal shape, size, position and echogenicity for this breed. The phrenic vasculature, glandular echogenicity and detail were unremarkable. Capsule, cortex, and medullary definition were normal for this age patient. The right adrenal gland measured 2.4 x 0.8 cm at the cranial pole and 0.4 cm at the caudal pole. The left adrenal gland measured 1.83 x 0.35 cm at the caudal pole and 0.29 cm at the cranial pole.

Spleen

The **spleen** revealed a focal, hyperechoic nodule at the caudal aspect of the spleen measuring 0.9 cm. This is most consistent with lipid plaque, but should be monitored.

Liver

The **liver** images from right and left intercostal as well as subcostal views revealed subjectively normal liver size, contour, and structure. Some age-related parenchymal remodeling was noted but likely not clinically significant at this time. Vascular and biliary tracts were of normal volume and no evidence of congestion was noted. The gallbladder presented some dependent debris with essentially normal contour. The cystic and common bile ducts were normal. No overt evidence of active inflammatory,



PATIENT

Max Fonseca

SPECIES

Canine

BREED

GoldenRetriever

SEX

Intact male

AGE

11 year

WEIGHT

51 lbs

INTERPRETED BY

Eric Lindquist, DMV
DABVP, Cert. IVUSS

IMAGING PERFORMED BY

Rebecca Hamilton

HOSPITAL NAME

All Creatures Great
and Small Denville

REFERRING VET

Dr. Ashmore

INVOICE

77970

DATE

5/26/26

infiltrative or regenerative pathology was noted but should be paired with current or past LE elevations regarding any clinical significance to this presentation. The hepatic lymph nodes were unremarkable.

Gastrointestinal

Examination of the **gastrointestinal tract** revealed a stomach and intestine free of stasis, of normal wall thickness, acceptable curvilinear mural detail, and peristaltic activity. Small and large intestine demonstrated normal luminal chyme and stool consistency respectively. No obstructive or overt infiltrative disease was noted. No associated abnormal lymphatic activity was noted.

Pancreas

The base and limbs of the **pancreas** were observed to be largely isoechoic to surrounding omental fat. Pancreatic duct and capsular contour were acceptably normal and parenchyma respected normal curvilinear patterns. No overt evidence of active inflammatory or neoplastic disease was noted.

ULTRASONOGRAPHIC FINDINGS

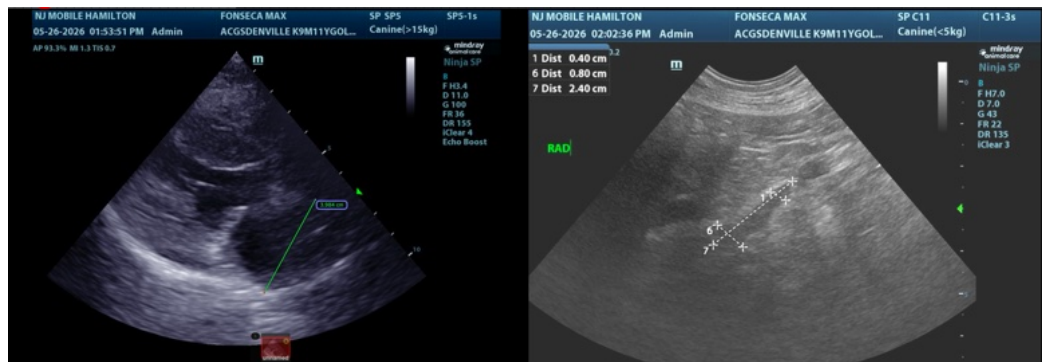
Normal echocardiogram, no evidence of pathology.

Normal geriatric abdomen, mild BPH prostate.

Left testicular tumor. Ledig cell tumor, Sertoli cell tumor possible, round cell tumor is unlikely.

INTERPRETATION OF THE FINDINGS & FURTHER RECOMMENDATIONS

There is no contraindication to anesthetic procedure. Neutering is indicated. A recheck sonogram of the spleen is recommended in 4-6 weeks.





PATIENT

Max Fonseca

SPECIES

Canine

BREED

GoldenRetriever

SEX

Intact male

AGE

11 year

WEIGHT

51 lbs

INTERPRETED BY

Eric Lindquist, DMV
 DABVP, Cert. IVUSS

IMAGING PERFORMED BY

Rebecca Hamilton

HOSPITAL NAME

All Creatures Great
 and Small Denville

REFERRING VET

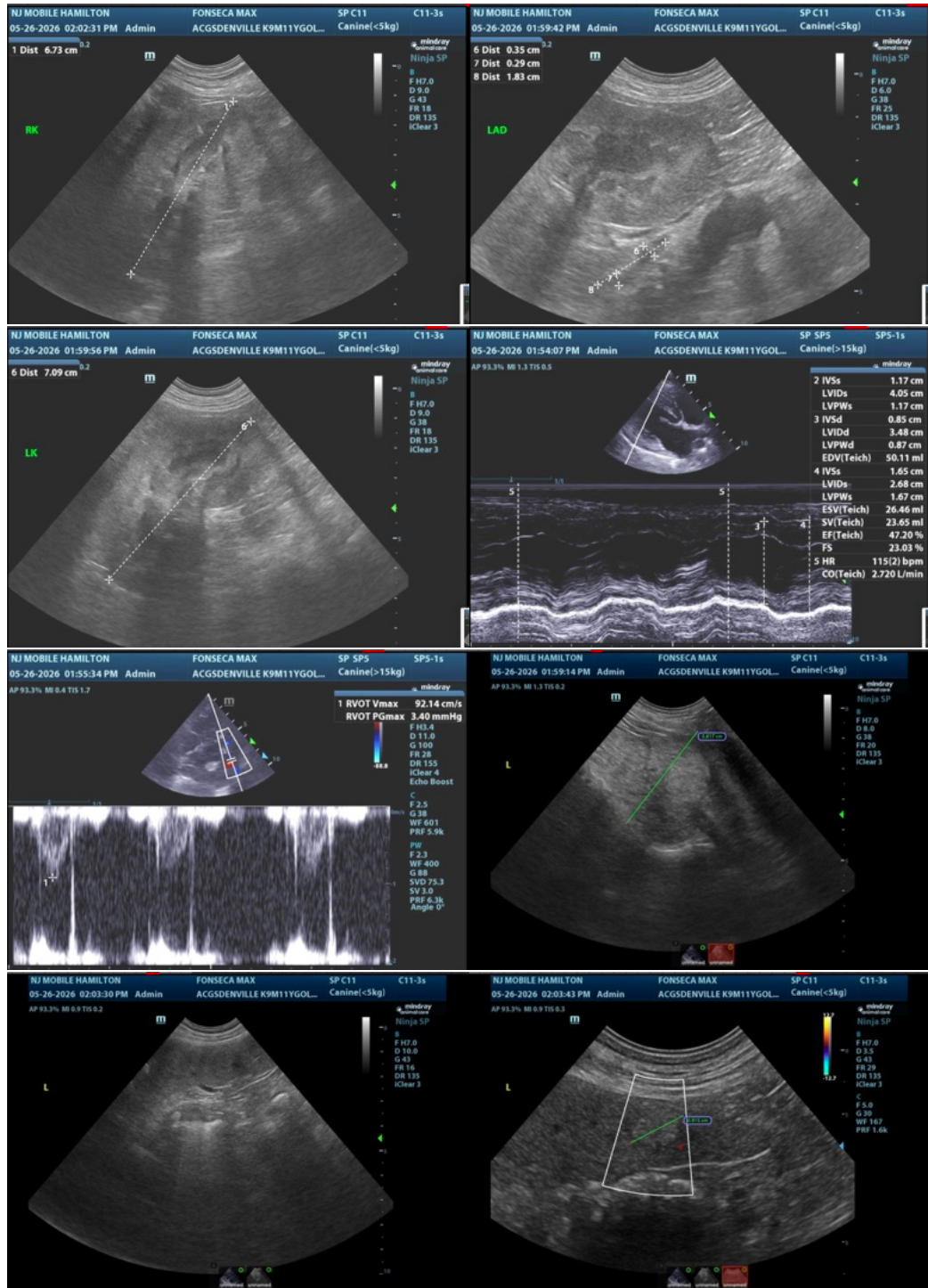
Dr. Ashmore

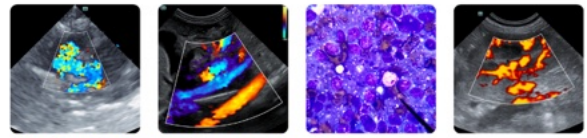
INVOICE

77970

DATE

5/26/26





PATIENT

Max Fonseca

SPECIES

Canine

BREED

GoldenRetriever

SEX

Intact male

AGE

11 year

WEIGHT

51 lbs

INTERPRETED BY

Eric Lindquist, DMV
DABVP, Cert. IVUSS

**IMAGING
PERFORMED BY**

Rebecca Hamilton

HOSPITAL NAME

All Creatures Great
and Small Denville

REFERRING VET

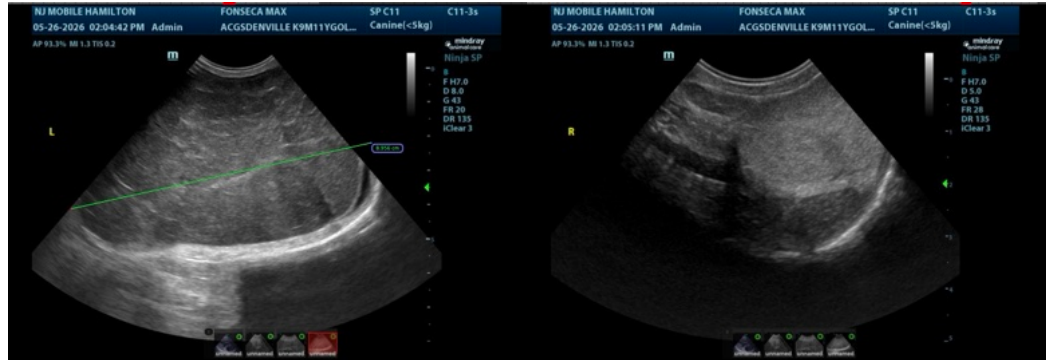
Dr. Ashmore

INVOICE

77970

DATE

5/26/26



The information and recommendations provided are based on the images presented by the referring veterinarian/sonographer. No evaluation can be communicated regarding pathology that was not visible in the image/video clips provided.

Thank you for this referral. If the clinical or image interpretation does not parallel your findings or if I can be of any further assistance please contact me.

Eric Lindquist, DMV, DABVP, Cert. IVUSS, CEO of SonoPath.com

info@SonoPath.com