

**PATIENT**

Nelson Robinson

**SPECIES**

Canine

**BREED**

Pomeranian

**SEX**

Neutered male

**AGE**

13 years

**WEIGHT**

13.6 lbs

**INTERPRETED BY**

Eric Lindquist, DMV  
DABVP, Cert. IVUSS

**IMAGING PERFORMED BY**

Dr. Ken Leal

**HOSPITAL NAME**

Warren AH

**REFERRING VET**

Dr. Zacchio

**INVOICE**

77645

**DATE**

5/18/26

**PRESENTING CLINICAL SIGNS**

History: Sibling had murmur and passed away. Owner concerned.  
Medications: Thyroid tabs, Triheart, bravest

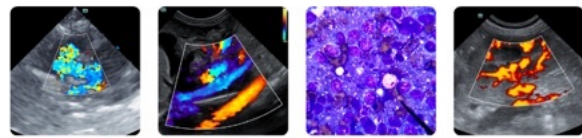
**ULTRASONOGRAPHIC EXAMINATION OF THE HEART**

The echocardiogram in this patient demonstrated normal **left atrial** size based on 3 different LA measurement methods. Chamber volumes and echogenicity were normal. The cranial and caudal **mitral** valve leaflets presented vegetative thickening consistent with endocardiosis. Doppler indicated measurable centralized insufficiency. The **left ventricle** presented thicknesses with linear contour and was not dilated nor restricted. The **myocardium** presented normal echogenicity without subjective evidence of significant fibrotic or ischemic disease. **Contractility** of the ventricular walls was adequate and in normal range for this patient evidenced by the fractional shortening measurement and subjective evaluation of the different regions of the myocardium. The **left ventricular outflow** tract demonstrated normal laminar flow and subjective structural integrity. The **right atrium** and auricle revealed normal size, structure and content. No evidence of masses was noted or chamber overload. Minor **tricuspid** insufficiency was noted. The **right ventricle** was of normal size (1/3 diameter of LV), chordae structure, myocardial echogenicity and thickness. **Pulmonic** tract assessment revealed normal valve structure, laminar flow, and diameter (approx. 1:1 pa/ao ratio). No visible **pericardial** or free pleura fluid was noted. No echographically detectable evidence of infiltrative disease was visible. The cranial **mediastinum and pericardial regions** were free of masses in the visible window.

CANINE CARDIAC PARAMETERS	MR VMAX (m/s)	TR VMAX (m/s)	LA/AO	LA/AO (Heart Base)	FS (%)	EF (%)	EPSS (cm)
NORMAL PARAMETER	4.5-5.5	<2.7	1.3	<1.6	28-40	40-100	<0.6
PATIENT	-	2.0	1.3	1.4	45	80	0.1
CANINE CARDIAC PARAMETERS	HR (BPM)	AV VMAX (m/s)	PV MAX (m/s)	BODY WEIGHT	LA 2D short axis Base view (cm)	LVIDd Avg; 2D and m-mode short axis (cm)	LVIDs Avg; 2D and m-mode short axis (cm)
NORMAL PARAMETER	50-100	0.7-1.7	0.7-1.6	BELOW	BELOW	BELOW	BELOW
PATIENT	90	1.9	0.9	13.6 lbs	2.6	2.2	

**ULTRASONOGRAPHIC FINDINGS**

- Stage B1 valvular disease, minor mitral and tricuspid insufficiency.



**PATIENT**

Nelson Robinson

**SPECIES**

Canine

**BREED**

Pomeranian

**SEX**

Neutered male

**AGE**

13 years

**WEIGHT**

13.6 lbs

**INTERPRETED BY**

Eric Lindquist, DMV  
 DABVP, Cert. IVUSS

**IMAGING PERFORMED BY**

Dr. Ken Leal

**HOSPITAL NAME**

Warren AH

**REFERRING VET**

Dr. Zacchio

**INVOICE**

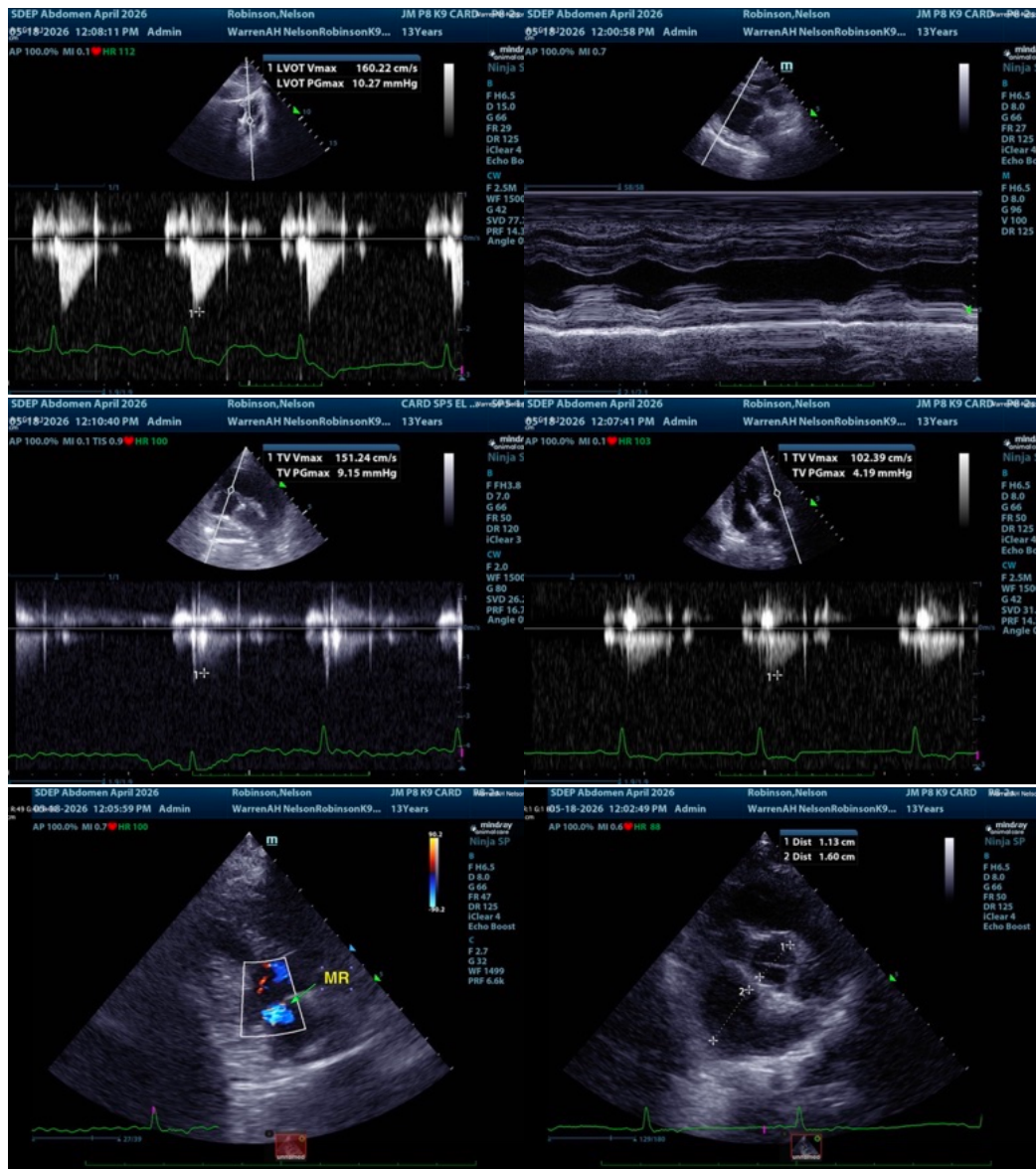
77645

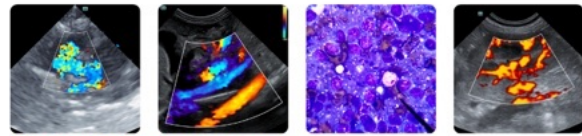
**DATE**

5/18/26

**INTERPRETATION OF THE FINDINGS & FURTHER RECOMMENDATIONS**

The heart is stable without clinical disease. No overt contraindication for anesthesia of brief to moderate duration. I suggest Torbutrol premed, Propofol induction, Isoflo maintenance or similar protocol if anesthesia is desired. Blood pressure recommended if not already performed and target white coat negative systolic pressure of < 160 mmHg. If higher than this ACE-inhibitor is suggested to reach this level. Recheck echocardiogram is recommended in 6 months, earlier if murmur grade increases or clinical signs initiate.





**PATIENT**

Nelson Robinson

**SPECIES**

Canine

**BREED**

Pomeranian

**SEX**

Neutered male

**AGE**

13 years

**WEIGHT**

13.6 lbs

**INTERPRETED BY**

Eric Lindquist, DMV  
 DABVP, Cert. IVUSS

**IMAGING PERFORMED BY**

Dr. Ken Leal

**HOSPITAL NAME**

Warren AH

**REFERRING VET**

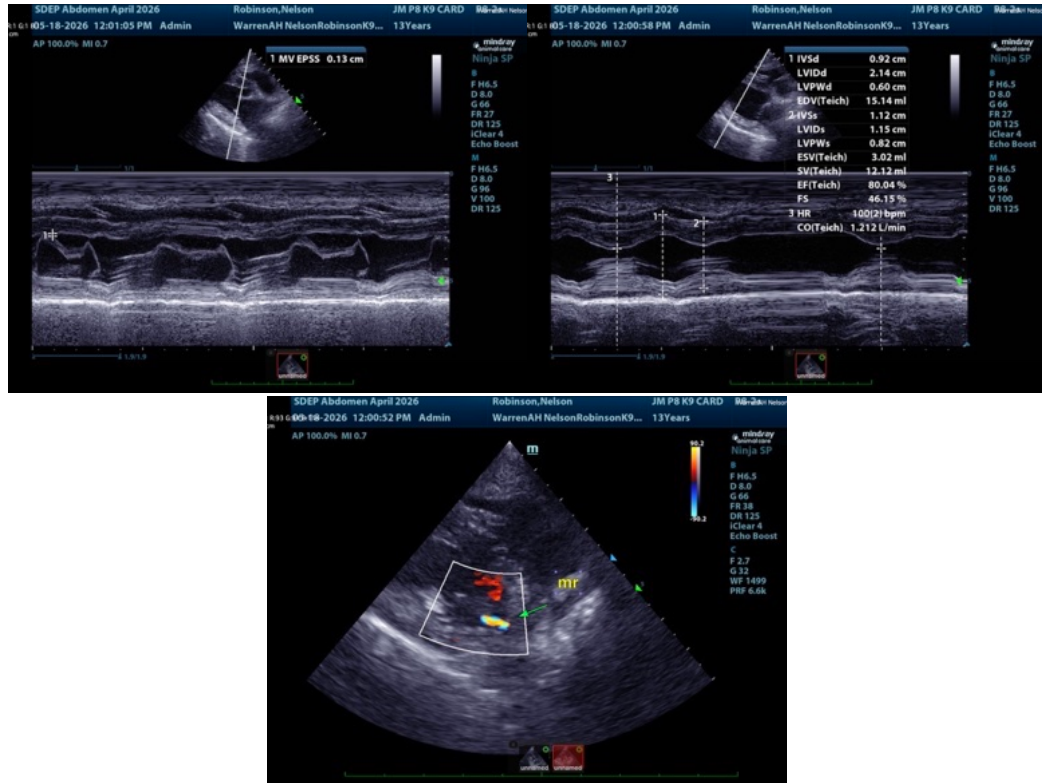
Dr. Zacchio

**INVOICE**

77645

**DATE**

5/18/26



The information and recommendations provided are based on the images presented by the referring veterinarian/sonographer. No evaluation can be communicated regarding pathology that was not visible in the image/video clips provided.

Thank you for this referral. If the clinical or image interpretation does not parallel your findings or if I can be of any further assistance please contact me.

**Eric Lindquist**, DMV, DABVP, Cert. IVUSS, CEO of SonoPath.com

[info@SonoPath.com](mailto:info@SonoPath.com)