



PATIENT

Miso Arevalo

SPECIES

Feline

BREED

Domestic Shorthair

SEX

Spayed female

AGE

15 years

WEIGHT

7.3 lbs

PRESENTING CLINICAL SIGNS

History: Heart murmur, kidney disease. Pt has hx of kidney dz and V. Recently not eating. Grade I/VI HM. Current medications - Forti Flora. Wants to know if Cardiac meds needed and if safe to start Subcutaneous fluids for kidneys.
 Abnormal PE/Chem/CBC/UA Results: BUN 106, Creat 7.0, SDMA (33.6), USG 1.018

ULTRASONOGRAPHIC EXAMINATION OF THE HEART

The echocardiogram in this patient demonstrated normal **left atrial** size based on 3 separate LA measurements. Minor **mitral** valve insufficiency was noted. Minor **myocardial** remodeling was noted. The **left ventricle** presented minor sectorial hypertrophy without significant remodeling. There was no evidence of volume overload. The **left ventricular outflow** tract demonstrated normal laminar flow and subjective structural integrity. The **right atrium** and auricle revealed normal size, structure and content. No evidence of masses was noted or chamber overload. **Tricuspid** valvular assessment demonstrated adequate linear morphology and kinetics. The **right ventricle** was of normal size (1/3 diameter of LV), chordae structure, myocardial echogenicity and thickness. **Pulmonic** tract assessment revealed normal valve structure, laminar flow, and diameter (approx. 1:1 pa/ao ratio). No visible **pericardial** or free pleura fluid was noted or extra cardiac pathology in the visible planes. The cranial **mediastinum and pericardial regions** were free of masses in the visible window.

INTERPRETED BY

Eric Lindquist, DMV,
 DABVP (CFM), Cert.
 IVUSS, CEO of
 SonoPath.com

IMAGING PERFORMED BY

Vincent Ravancho,
 CVT

HOSPITAL NAME

Paws Wings, Scales AH

REFERRING VET

Dr. Stancel

INVOICE

77648

DATE

5/18/26

FELINE CARDIAC PARAMETERS	BODY WEIGHT	HR (BPM)	IVSd (cm)	LVIDd (cm)	LVWd (cm)	FS (%)	EF (%)
NORMAL PARAMETER	-----	150-240	0.3-0.6	1.0-2.1	0.25-0.6	35-67	80-100
PATIENT	7.3 lbs	NM	0.44	1.28	0.53	50	77.44
FELINE CARDIAC PARAMETERS	LA/AO (M-mode)	LA/AO HEART BASE (Sisson)	LAD LA MAX 4 Chamber		LVOT VEL. (m/s)	RVOT VEL. (m/s)	IVRT (m/)
NORMAL PARAMETER	<1.5	1.6	0.7-1.7		<1.6	<1.3	40-60
PATIENT	1.3	1.2	1.3		1.8	1.3	NM
Adapted from June Boon, Veterinary Echocardiography, 1998 Sisson D et al. JVIM 1991; 5: 232, Jacobs et al. Am J Vet Res 1985; 46:1705							

ULTRASONOGRAPHIC FINDINGS

Normal echocardiogram.
 Trivial mitral insufficiency and minor myocardial remodeling.



INTERPRETATION OF THE FINDINGS & FURTHER RECOMMENDATIONS

PATIENT

Miso Arevalo

SPECIES

Feline

BREED

Domestic Shorthair

SEX

Spayed female

AGE

15 years

WEIGHT

7.3 lbs

INTERPRETED BY

Eric Lindquist, DMV,
 DABVP (CFM), Cert.
 IVUSS, CEO of
 SonoPath.com

IMAGING PERFORMED BY

Vincent Ravancho,
 CVT

HOSPITAL NAME

Paws Wings, Scales AH

REFERRING VET

Dr. Stancel

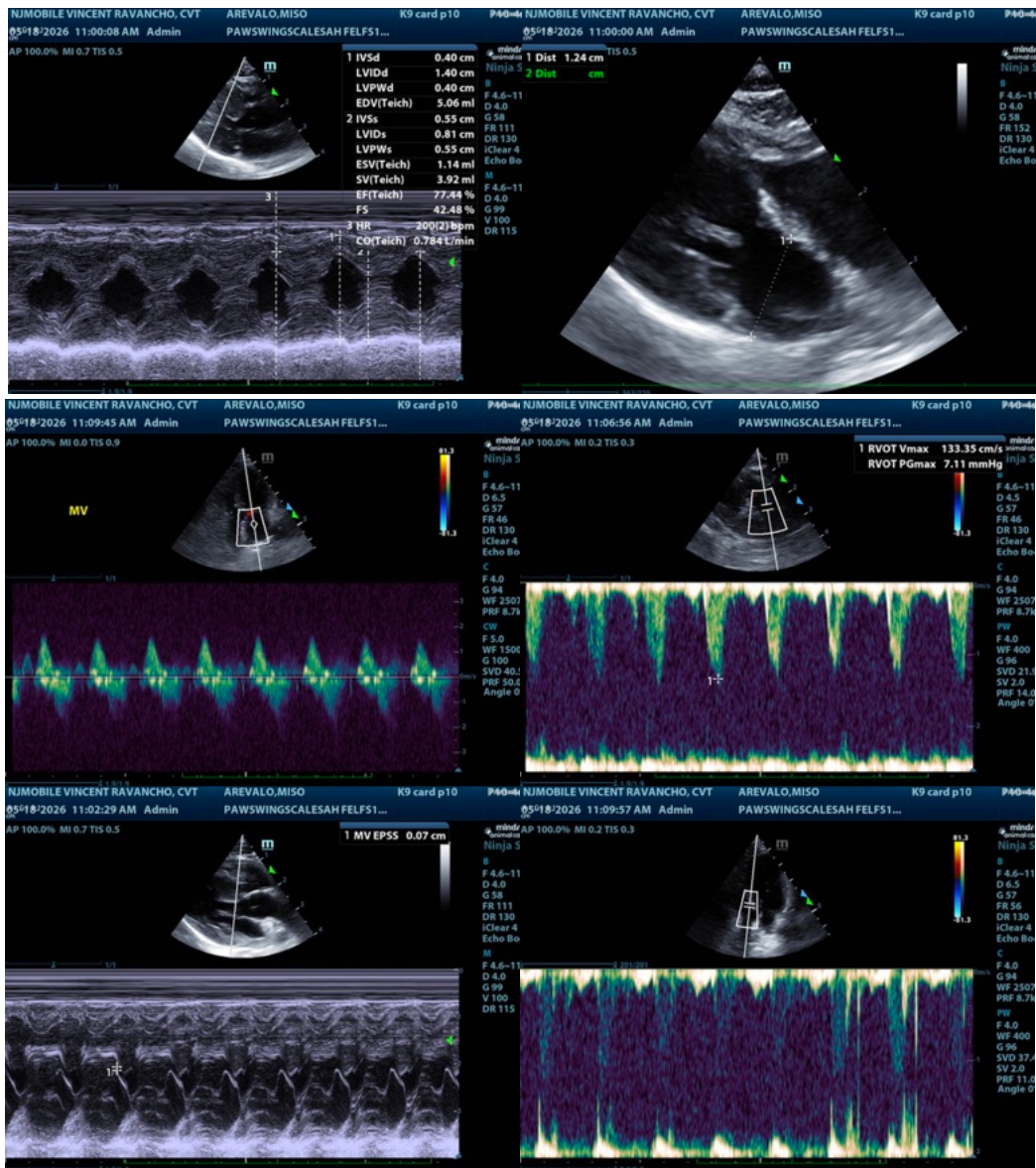
INVOICE

77648

DATE

5/18/26

Any volume shifts owing to the azotemia may be playing a role in this patient. However, there was no evidence of clinical disease noted. Systemic hypertension may also be playing a role in the cardiac presentation, yet there was no evidence of volume overload or pressure overload. There is no contraindication to fluid therapy. An abdominal sonogram is recommended for further definition.





PATIENT

Miso Arevalo

SPECIES

Feline

BREED

Domestic Shorthair

SEX

Spayed female

AGE

15 years

WEIGHT

7.3 lbs

INTERPRETED BY

Eric Lindquist, DMV,
 DABVP (CFM), Cert.
 IVUSS, CEO of
 SonoPath.com

IMAGING PERFORMED BY

Vincent Ravancho,
 CVT

HOSPITAL NAME

Paws Wings, Scales AH

REFERRING VET

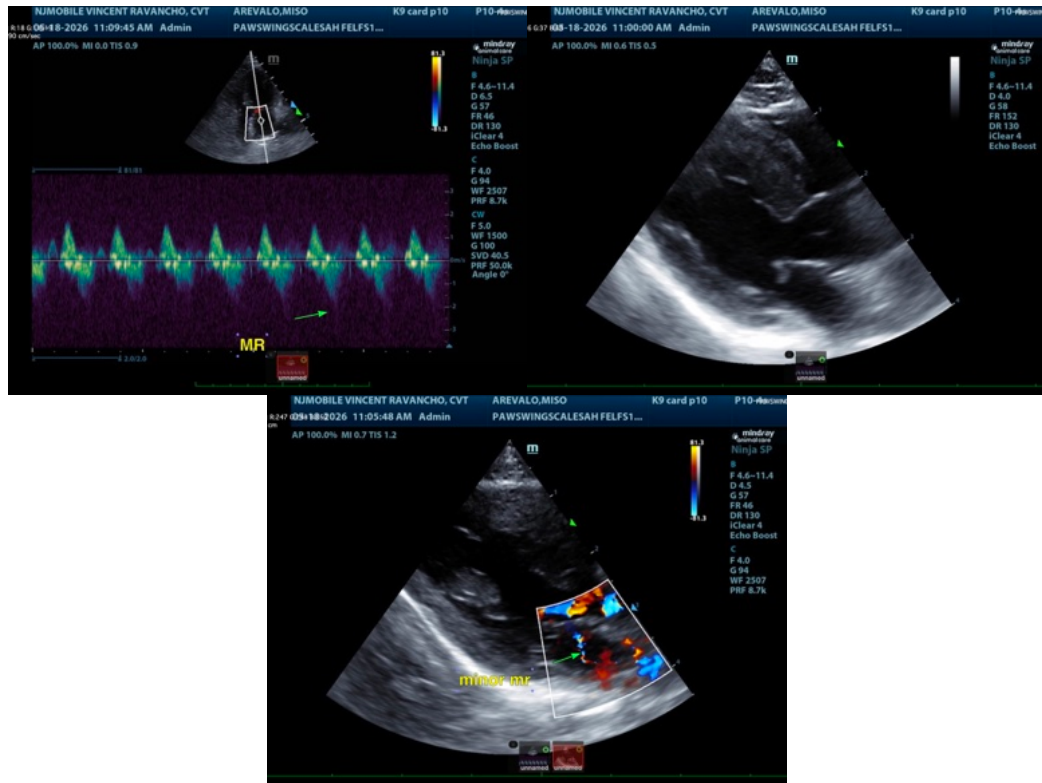
Dr. Stancel

INVOICE

77648

DATE

5/18/26



The information and recommendations provided are based on the images presented by the referring veterinarian/sonographer. No evaluation can be communicated regarding pathology that was not visible in the image/video clips provided.

Thank you for this referral. If the clinical or image interpretation does not parallel your findings or if I can be of any further assistance please contact me.

Eric Lindquist, DMV, DABVP (CFM), Cert. IVUSS, CEO of SonoPath.com

Info@SonoPath.com