

**PATIENT**

Cocobean Abrams

**SPECIES**

Canine

**BREED**

Long Haired Chihuahua

**SEX**

Neutered male

**AGE**

10 years

**WEIGHT**

4.7 lbs

**INTERPRETED BY**

Eric Lindquist, DMV,  
DABVP, Cert. IVUSS,  
CEO of SonoPath.com

**IMAGING PERFORMED BY**

Shari Reffi, CVT

**HOSPITAL NAME**

Flanders VC

**REFERRING VET**

Dr. Gasparro

**INVOICE**

75366

**DATE**

5/12/26

**PRESENTING CLINICAL SIGNS**

History: Pre-anesthetic evaluation for safety. Grade 2-3/6 L sided heart murmur. No current medications.

**ULTRASONOGRAPHIC EXAMINATION OF THE HEART**

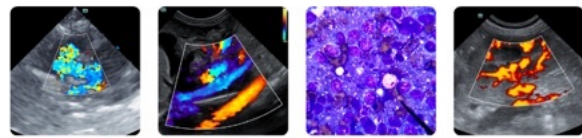
The echocardiogram in this patient demonstrated normal **left atrial** size based on 3 different LA measurement methods. Chamber volumes and echogenicity were normal. The cranial and caudal **mitral** valve leaflets presented vegetative thickening consistent with endocardiosis. Doppler indicated minor insufficiency. The **left ventricle** presented thicknesses with linear contour and was not dilated nor restricted. The **myocardium** presented normal echogenicity without subjective evidence of significant fibrotic or ischemic disease. **Contractility** of the ventricular walls was adequate and in normal range for this patient evidenced by the fractional shortening measurement and subjective evaluation of the different regions of the myocardium. The **left ventricular outflow** tract demonstrated normal laminar flow and subjective structural integrity. The **right atrium** and auricle revealed normal size, structure and content. No evidence of masses was noted or chamber overload. **Tricuspid** valvular assessment demonstrated adequate linear morphology. The **right ventricle** was of normal size (1/3 diameter of LV), chordae structure, myocardial echogenicity and thickness. **Pulmonic** tract assessment revealed normal valve structure, laminar flow, and diameter (approx. 1:1 pa/ao ratio). No visible **pericardial** or free pleura fluid was noted. No echographically detectable evidence of infiltrative disease was visible. The cranial **mediastinum and pericardial regions** were free of masses in the visible window.

**E Wave Velocity 0.6 m/sec**

<b>CANINE CARDIAC PARAMETERS</b>	<b>MR VMAX</b> (m/s)	<b>TR VMAX</b> (m/s)	<b>LA/AO</b>	<b>LA/AO</b> (Heart Base)	<b>FS</b> (%)	<b>EF</b> (%)	<b>EPSS</b> (cm)
<b>NORMAL PARAMETER</b>	4.5-5.5	<2.7	1.3	<1.6	28-40	40-100	<0.6
<b>PATIENT</b>	-	-	1.0	1.26	32	64	0.1
<b>CANINE CARDIAC PARAMETERS</b>	<b>HR</b> (BPM)	<b>AV VMAX</b> (m/s)	<b>PV MAX</b> (m/s)	<b>BODY WEIGHT</b> (kg)	<b>LA</b> 2D short axis Base view (cm)	<b>LVIDd</b> Avg; 2D and m-mode short axis (cm)	<b>LVIDs</b> Avg; 2D and m-mode short axis (cm)
<b>NORMAL PARAMETER</b>	50-100	0.7-1.7	0.7-1.6	BELOW	BELOW	BELOW	BELOW
<b>PATIENT</b>	123	1.0	0.92	4.7 lbs	1.6	1.36	

**ULTRASONOGRAPHIC FINDINGS**

Stage B1 valvular disease.



**PATIENT**

Cocobean Abrams

**SPECIES**

Canine

**BREED**

Long Haired Chihuahua

**SEX**

Neutered male

**AGE**

10 years

**WEIGHT**

4.7 lbs

**INTERPRETED BY**

Eric Lindquist, DMV,  
 DABVP, Cert. IVUSS,  
 CEO of SonoPath.com

**IMAGING PERFORMED BY**

Shari Reffi, CVT

**HOSPITAL NAME**

Flanders VC

**REFERRING VET**

Dr. Gasparro

**INVOICE**

75366

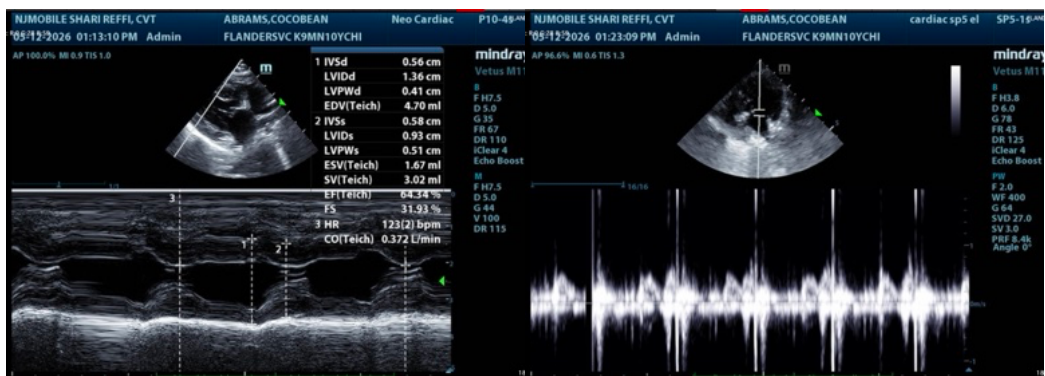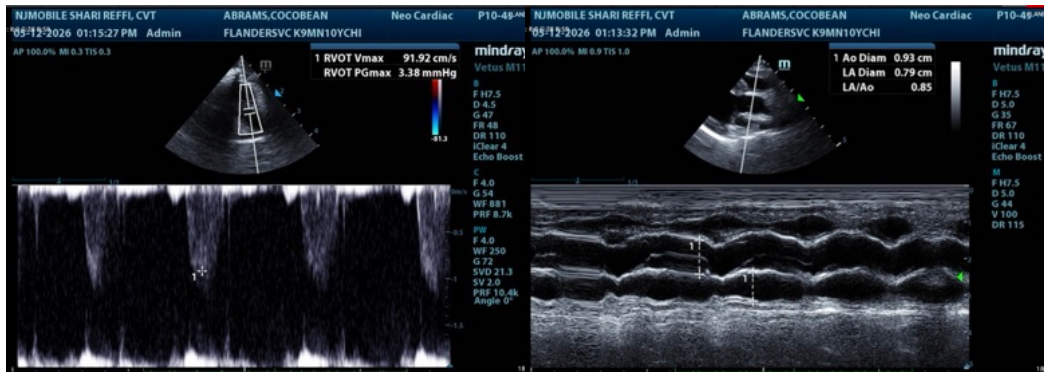
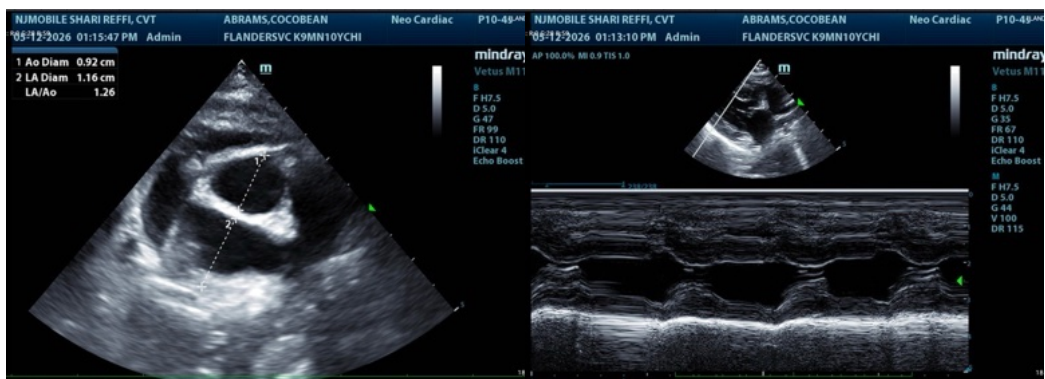
**DATE**

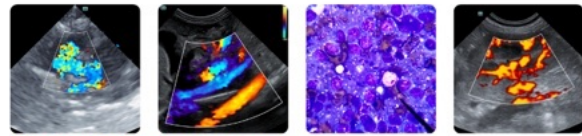
5/12/26

**INTERPRETATION OF THE FINDINGS & FURTHER RECOMMENDATIONS**

There is no overt contraindication to anesthetic procedure.

The heart is stable without clinical disease. No overt contraindication for anesthesia of brief to moderate duration. I suggest Torbutrol premed, Propofol induction, Isoflo maintenance or similar protocol if anesthesia is desired. Blood pressure recommended if not already performed and target white coat negative systolic pressure of < 160 mmHg. If higher than this ACE-inhibitor is suggested to reach this level. Recheck echocardiogram is recommended in 6 months, earlier if murmur grade increases or clinical signs initiate.





**PATIENT**

Cocobean Abrams

**SPECIES**

Canine

**BREED**

Long Haired Chihuahua

**SEX**

Neutered male

**AGE**

10 years

**WEIGHT**

4.7 lbs

**INTERPRETED BY**

Eric Lindquist, DMV,  
DABVP, Cert. IVUSS,  
CEO of SonoPath.com

**IMAGING PERFORMED BY**

Shari Reffi, CVT

**HOSPITAL NAME**

Flanders VC

**REFERRING VET**

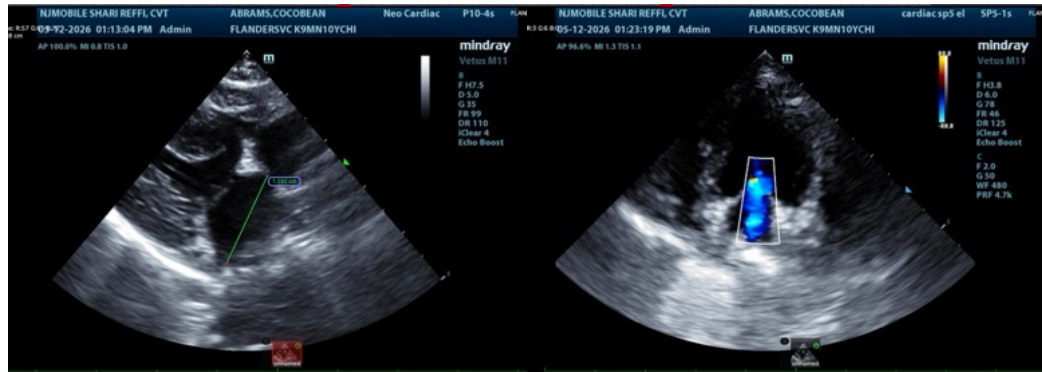
Dr. Gasparro

**INVOICE**

75366

**DATE**

5/12/26



The information and recommendations provided are based on the images presented by the referring veterinarian/sonographer. No evaluation can be communicated regarding pathology that was not visible in the image/video clips provided.

Thank you for this referral. If the clinical or image interpretation does not parallel your findings or if I can be of any further assistance please contact me.

Eric Lindquist, DMV, DABVP, Cert. IVUSS, CEO of SonoPath.com

Info@SonoPath.com