

PATIENT

Sonny Davis

SPECIES

Canine

BREED

Miniature Poodle Mix

SEX

Neutered male

AGE

14 years

WEIGHT

12.6 lbs

INTERPRETED BY

Eric Lindquist, DMV,
 DABVP, Cert. IVUSS,
 CEO of SonoPath.com

IMAGING PERFORMED BY

Shari Reffi, CVT

HOSPITAL NAME

Heart and Paw Lake
 Hopatcong

REFERRING VET

Dr. Marmolejo

INVOICE

75312

DATE

5/11/26

PRESENTING CLINICAL SIGNS

History: BCS 4/9. Progressive heart murmur. (last echocardiogram 10/16/2025) report attached. New heart murmur grade IV/VI, asymptomatic. Current meds: Denamarin (Torb/Midaz)
 Abnormal PE/Chem/CBC/UA Results: ALT-815; AST-220; ALP-754; BUN-32.7

ULTRASONOGRAPHIC EXAMINATION OF THE HEART

The echocardiogram in this patient presented compensated mitral and tricuspid insufficiency. All four volumes were normal. The pulmonary and aortic outflows were unremarkable with normal velocities. Arrhythmogenic activity was noted in this patient. There was no pericardial or pleural effusion noted.

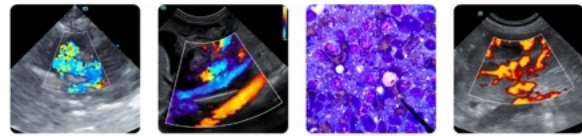
| CANINE CARDIAC PARAMETERS | MR VMAX (m/s) | TR VMAX (m/s) | LA/AO | LA/AO (Heart Base) | FS (%) | EF (%) | EPSS (cm) |
|---------------------------|---------------|---------------|--------------|--------------------|---------------------------------|--|--|
| NORMAL PARAMETER | 4.5-5.5 | <2.7 | 1.3 | <1.6 | 28-40 | 40-100 | <0.6 |
| PATIENT | 5.66 | 2.86 | 1.05 | 1.29 | 40 | 72 | 0.29 |
| CANINE CARDIAC PARAMETERS | HR (BPM) | AV VMAX (m/s) | PV MAX (m/s) | BODY WEIGHT | LA 2D short axis Base view (cm) | LVIDd Avg; 2D and m-mode short axis (cm) | LVIDs Avg; 2D and m-mode short axis (cm) |
| NORMAL PARAMETER | 50-100 | 0.7-1.7 | 0.7-1.6 | BELOW | BELOW | BELOW | BELOW |
| PATIENT | | 1.3 | 0.77 | 12.6 lbs | 2.9 | 2.6 | |

ULTRASONOGRAPHIC FINDINGS

Stable stage B1 valvular disease with arrhythmogenic activity.

INTERPRETATION OF THE FINDINGS & FURTHER RECOMMENDATIONS

I recommend EKG to assess for pathological arrhythmia versus pronounced sinus arrhythmia. Otherwise, no specific therapy is warranted. There was no overt progression from the prior echocardiogram.



PATIENT

Sonny Davis

SPECIES

Canine

BREED

Miniature Poodle Mix

SEX

Neutered male

AGE

14 years

WEIGHT

12.6 lbs

INTERPRETED BY

Eric Lindquist, DMV,
 DABVP, Cert. IVUSS,
 CEO of SonoPath.com

IMAGING PERFORMED BY

Shari Reffi, CVT

HOSPITAL NAME

Heart and Paw Lake
 Hopatcong

REFERRING VET

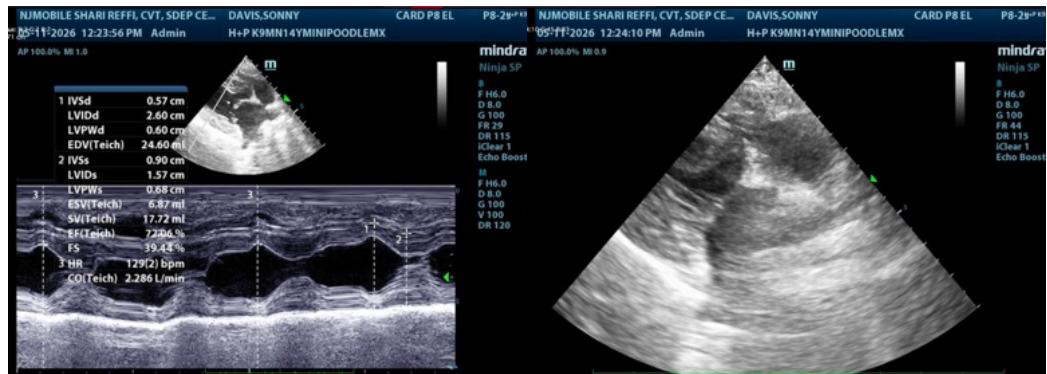
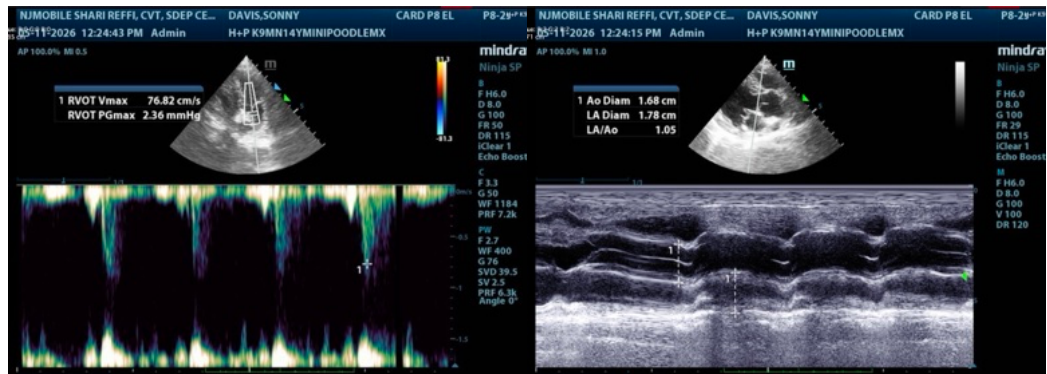
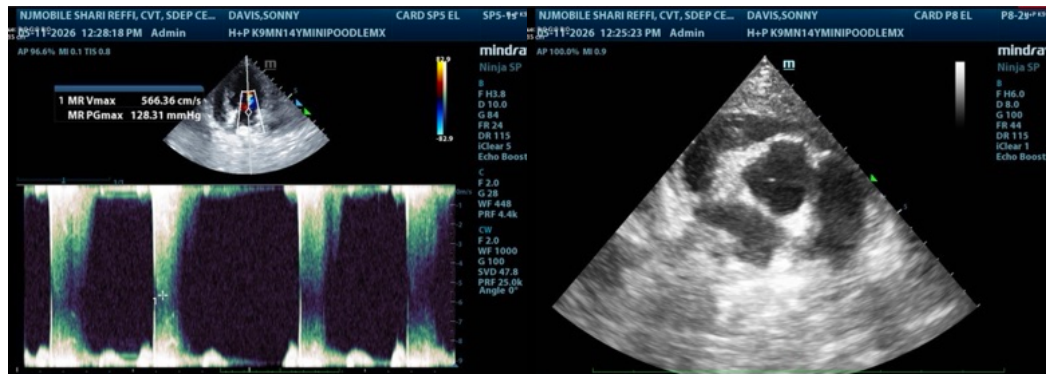
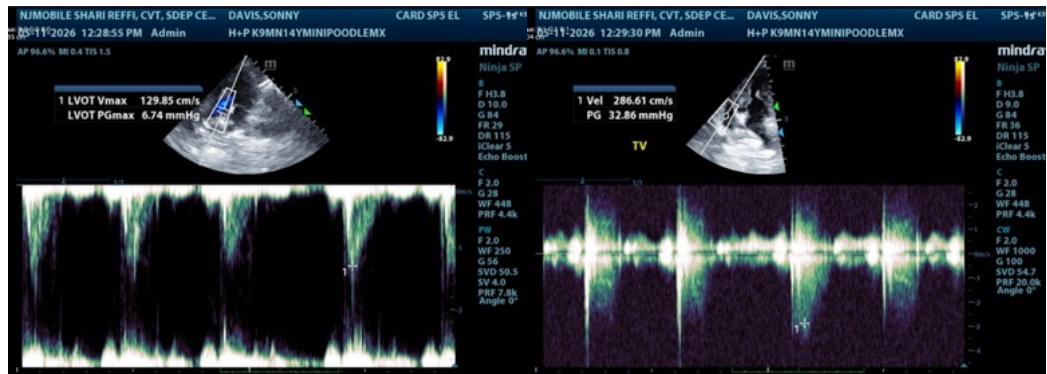
Dr. Marmolejo

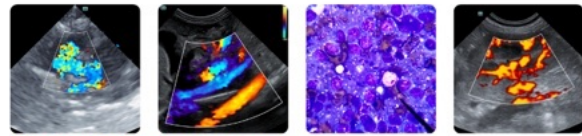
INVOICE

75312

DATE

5/11/26





PATIENT

Sonny Davis

SPECIES

Canine

BREED

Miniature Poodle Mix

SEX

Neutered male

AGE

14 years

WEIGHT

12.6 lbs

INTERPRETED BY

Eric Lindquist, DMV,
DABVP, Cert. IVUSS,
CEO of SonoPath.com

IMAGING PERFORMED BY

Shari Reffi, CVT

HOSPITAL NAME

Heart and Paw Lake
Hopatcong

REFERRING VET

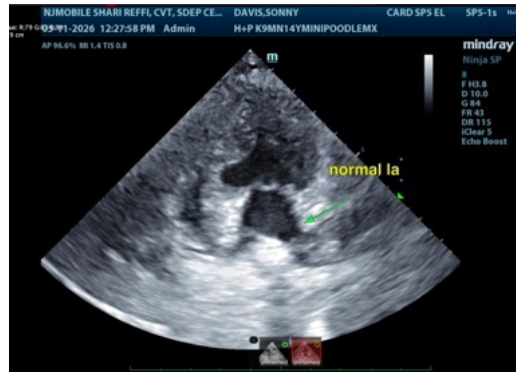Dr. Marmolejo

INVOICE

75312

DATE

5/11/26



The information and recommendations provided are based on the images presented by the referring veterinarian/sonographer. No evaluation can be communicated regarding pathology that was not visible in the image/video clips provided.

Thank you for this referral. If the clinical or image interpretation does not parallel your findings or if I can be of any further assistance please contact me.

Eric Lindquist, DMV, DABVP, Cert. IVUSS, CEO of SonoPath.com

Info@SonoPath.com