



## PATIENT

Beans Tansey

## SPECIES

Feline

## BREED

Domestic Shorthair

## SEX

Neutered male

## AGE

5 years

## WEIGHT

11.2 lbs

## INTERPRETED BY

Eric Lindquist, DMV,  
DABVP (CFM), Cert.  
IVUSS, CEO of  
SonoPath.com

## IMAGING PERFORMED BY

Chloe Lowe

## HOSPITAL NAME

Blairstown AH

## REFERRING VET

Dr. Summers

## INVOICE

74306

## DATE

4/8/26

## PRESENTING CLINICAL SIGNS

History: Not eating well. Vomiting. Exam WNL  
Gabapentin 100mg q12hr ( but owner having hard time giving)  
Abnormal PE/Chem/CBC/UA Results: WNL

## ULTRASONOGRAPHIC EXAMINATION OF THE ABDOMEN

### *Urinary System*

The **urinary bladder**, trigone, and pelvic urethra presented normal thicknesses and normal tone. The ureters were not visible which is normal. No uroliths or sediment were visualized and anechoic urine was present. No evidence of inflammatory or neoplastic changes was noted. Ureteral papillae were normal.

The **kidneys** revealed normal size and structure, corticomedullary definition and ratio for this age. The cortices presented largely uniform texture with normal echogenic relationship to liver and spleen. Medullary structure differed distinctly from the cortex and no evidence of pelvic dilation was present. The capsules were acceptably uniform without significant irregularities. The right kidney measured 4.6 cm. The left kidney measured 4.26 cm.

### *Adrenal Glands*

Both **adrenal glands** were visualized and recognized as having normal shape, size, position and echogenicity for this breed. The phrenic vasculature, glandular echogenicity and detail were unremarkable. Capsule, cortex, and medullary definition were normal for this age patient. The left adrenal gland measured 0.4 cm. The right adrenal gland measured 0.49 cm.

### *Spleen*

The **spleen** presented a smooth homogeneous parenchyma hyperechoic to liver and renal cortical parenchyma. The capsule was smooth without noticeable expansion or deviation from within the spleen or adjacent pathology. The splenic vasculature demonstrated normal volume without signs of congestion or thrombosis. No sonographic evidence of acute or chronic inflammatory, neoplastic, or infarctual changes was noted.

### *Liver*

The **liver** images submitted revealed subjectively normal liver size, contour, and structure. Parenchymal echogenicity was naturally coarse and hypoechoic to the spleen. Vascular and biliary tracts were of normal volume with no evidence of congestion. The gallbladder presented acceptably thin walls with primarily anechoic content. The cystic and common bile ducts were normal. No pathological hepatic lymphadenopathy was evident. No overt structural evidence of inflammatory, infiltrative or regenerative pathology was evident.



**PATIENT**

Beans Tansey

**SPECIES**

Feline

**BREED**

Domestic Shorthair

**SEX**

Neutered male

**AGE**

5 years

**WEIGHT**

11.2 lbs

**INTERPRETED BY**

Eric Lindquist, DMV,  
DABVP (CFM), Cert.  
IVUSS, CEO of  
SonoPath.com

**IMAGING PERFORMED BY**

Chloe Lowe

**HOSPITAL NAME**

Blairstown AH

**REFERRING VET**

Dr. Summers

**INVOICE**

74306

**DATE**

4/8/26

**Gastrointestinal**

The **gastrointestinal** presentation revealed mild uniform prominence of the gastric mucosa as well as areas of "ropey" small intestinal wall with slight disruption of the normal 1:3 muscularis/mucosal ratio. The intestinal submucosa was slightly irregular, thickened and hyperechoic suggestive of low grade, chronic disease. No concerning lymphadenopathy was visible. No evidence of obstruction was present. Chronic inflammatory bowel disease is likely with a low possibility of an early neoplastic event such as lymphoma. Full thickness tissue biopsies via open laparotomy, ideally guided by intraoperative ultrasound in order to obtain the most representative mural sample, would be necessary to rule out this possibility.

**Pancreas**

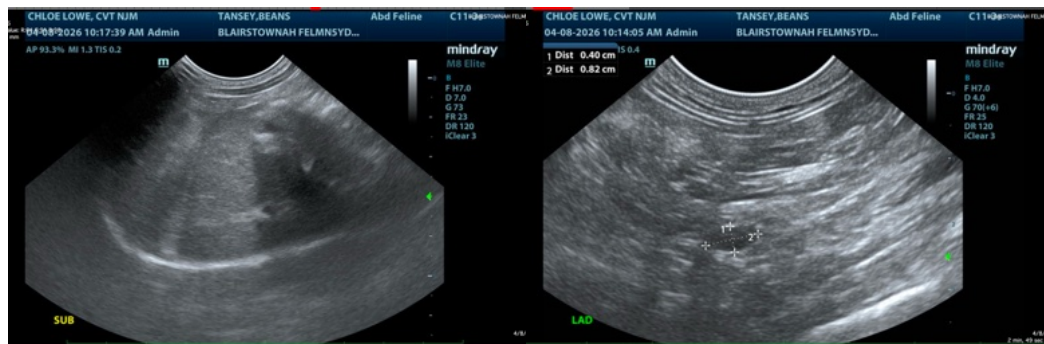
The **pancreas** was hypoechoic and irregular at the right base. Enhanced mesentery was noted around the pancreas suggestive for pancreatitis.

**ULTRASONOGRAPHIC FINDINGS**

IBD GI pattern.  
Suspicion of pancreatitis, low grade.

**INTERPRETATION OF THE FINDINGS & FURTHER RECOMMENDATIONS**

IV fluid support, broad spectrum antibiotics, pain management, +/- Prednisolone trial is recommended. There is no evidence of foreign bodies or neoplasia. Hydrolyzed diet is recommended along with anti-parasitic protocol.





**PATIENT**

Beans Tansey

**SPECIES**

Feline

**BREED**

Domestic Shorthair

**SEX**

Neutered male

**AGE**

5 years

**WEIGHT**

11.2 lbs

**INTERPRETED BY**

Eric Lindquist, DMV,  
 DABVP (CFM), Cert.  
 IVUSS, CEO of  
 SonoPath.com

**IMAGING PERFORMED BY**

Chloe Lowe

**HOSPITAL NAME**

Blairstown AH

**REFERRING VET**

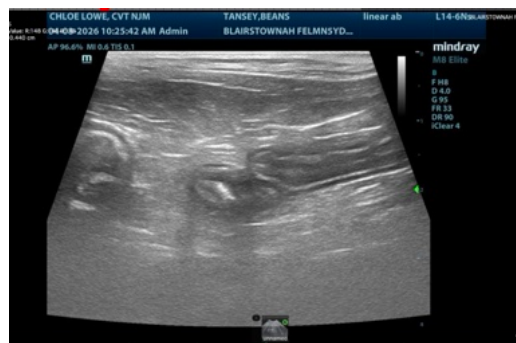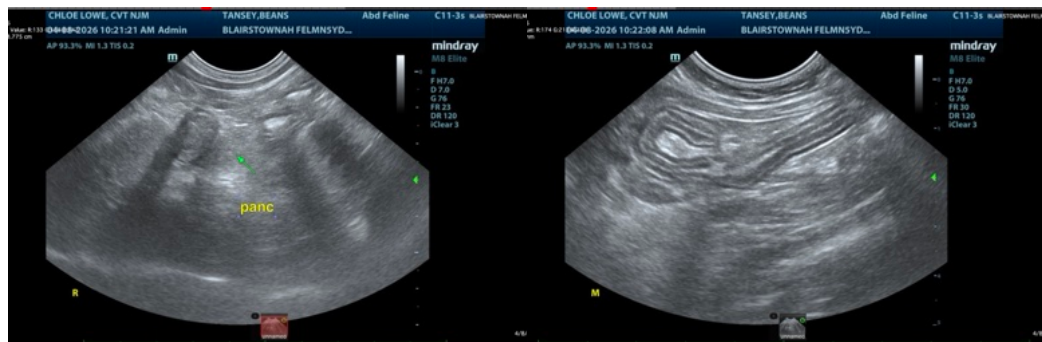
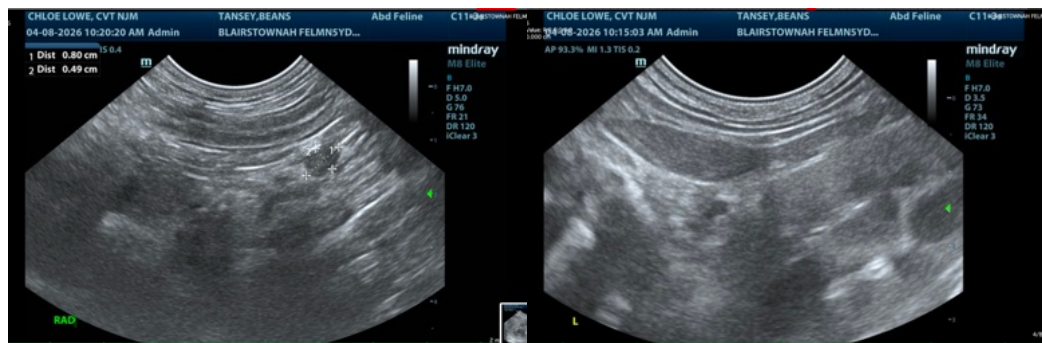
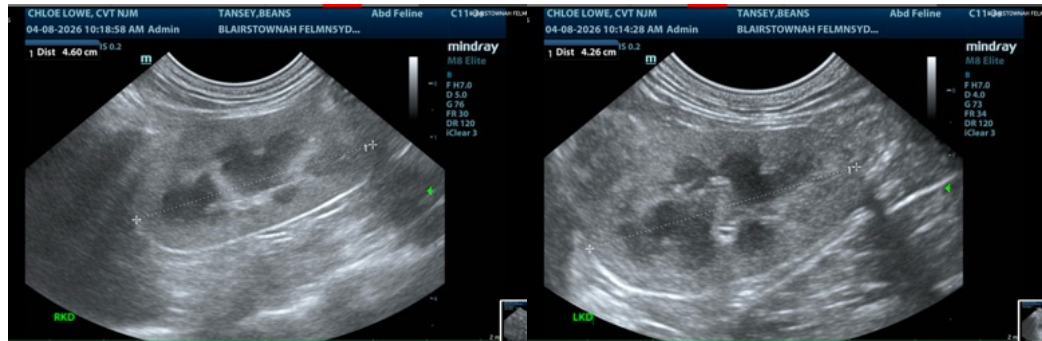
Dr. Summers

**INVOICE**

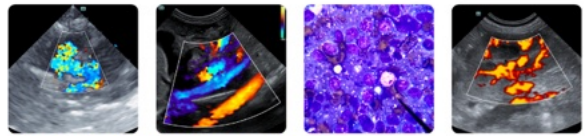
74306

**DATE**

4/8/26



The information and recommendations provided are based on the images presented by the referring veterinarian/sonographer. No evaluation can be communicated regarding pathology that was not visible in the image/video clips provided.



**PATIENT**

Beans Tansey

Thank you for this referral. If the clinical or image interpretation does not parallel your findings or if I can be of any further assistance please contact me.

**SPECIES**

Feline

Eric Lindquist, DMV, DABVP (CFM), Cert. IVUSS, CEO of SonoPath.com

Info@SonoPath.com

**BREED**

Domestic Shorthair

**SEX**

Neutered male

**AGE**

5 years

**WEIGHT**

11.2 lbs

**INTERPRETED BY**

Eric Lindquist, DMV,  
DABVP (CFM), Cert.  
IVUSS, CEO of  
SonoPath.com

**IMAGING  
PERFORMED BY**

Chloe Lowe

**HOSPITAL NAME**

Blairstown AH

**REFERRING VET**

Dr. Summers

**INVOICE**

74306

**DATE**

4/8/26