



PATIENT

Rudy Snyder

SPECIES

Canine

BREED

Cockapoo

SEX

Neutered male

AGE

14 year

WEIGHT

17.8 lbs

INTERPRETED BY

Eric Lindquist, DMV
DABVP, Cert. IVUSS

IMAGING PERFORMED BY

Rebecca Hamilton

HOSPITAL NAME

Budd Lake AH

REFERRING VET

Dr. Welch

INVOICE

75044

DATE

4/30/26

PRESENTING CLINICAL SIGNS

History: Heart murmur 4-5/6, now coughing last two weeks at night before bed

ULTRASONOGRAPHIC EXAMINATION OF THE HEART

The echocardiogram in this patient demonstrated enlarged **left atrial** size based on 3 different LA measurement methods. The cranial and caudal **mitral** valve leaflets presented vegetative thickening consistent with endocardiosis. Prolapse of the anterior mitral valve leaflet was noted. Doppler indicated measurable insufficiency. Volume overload was noted in the **left atrium** and **left ventricle**. The **myocardium** presented normal echogenicity without subjective evidence of significant fibrotic or ischemic disease. **Contractility** of the ventricular walls was adequate and in normal range for this patient evidenced by the fractional shortening measurement and subjective evaluation of the different regions of the myocardium. The **left ventricular outflow** tract demonstrated normal laminar flow and subjective structural integrity. The **right atrium** and auricle revealed normal size, structure and content. No evidence of masses was noted or chamber overload. **Tricuspid** insufficiency was noted. The **right ventricle** was of normal size (1/3 diameter of LV), chordae structure, myocardial echogenicity and thickness. **Pulmonic** tract assessment revealed normal valve structure, laminar flow, and diameter (approx. 1:1 pa/ao ratio). No visible **pericardial** or free pleura fluid was noted. No echographically detectable evidence of infiltrative disease was visible. The cranial **mediastinum and pericardial regions** were free of masses in the visible window.

CANINE CARDIAC PARAMETERS	MR VMAX (m/s)	TR VMAX (m/s)	LA/AO	LA/AO (Heart Base)	FS (%)	EF (%)	EPSS (cm)
NORMAL PARAMETER	4.5-5.5	<2.7	1.3	<1.6	28-40	40-100	<0.6
PATIENT	6.29		NM		41	72	0.1
CANINE CARDIAC PARAMETERS	HR (BPM)	AV VMAX (m/s)	PV MAX (m/s)	BODY WEIGHT	LA 2D short axis Base view (cm)	LVIDd Avg; 2D and m-mode short axis (cm)	LVIDs Avg; 2D and m-mode short axis (cm)
NORMAL PARAMETER	50-100	0.7-1.7	0.7-1.6	BELOW	BELOW	BELOW	BELOW
PATIENT	177	1.4	1.1	17.8 lbs	4.4 max	3.9	

ULTRASONOGRAPHIC FINDINGS

Mitral and tricuspid insufficiency was noted.
Stage B2 + valvular disease.



PATIENT

Rudy Snyder

SPECIES

Canine

BREED

Cockapoo

SEX

Neutered male

AGE

14 year

WEIGHT

17.8 lbs

INTERPRETED BY

Eric Lindquist, DMV
 DABVP, Cert. IVUSS

IMAGING PERFORMED BY

Rebecca Hamilton

HOSPITAL NAME

Budd Lake AH

REFERRING VET

Dr. Welch

INVOICE

75044

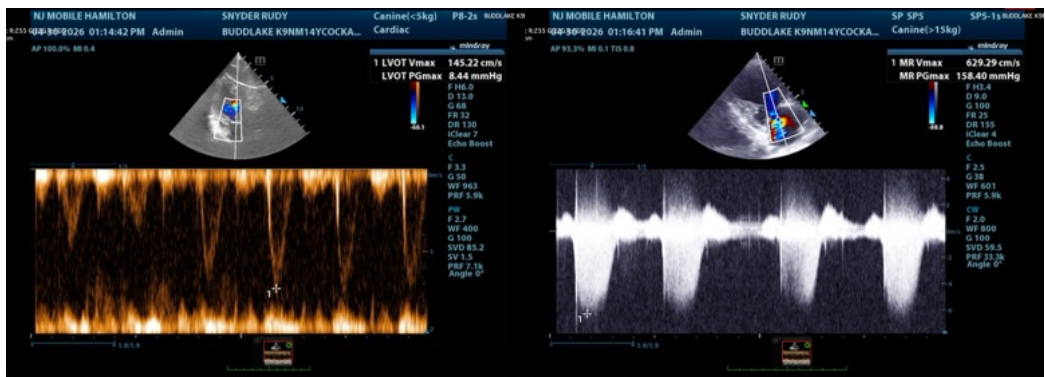
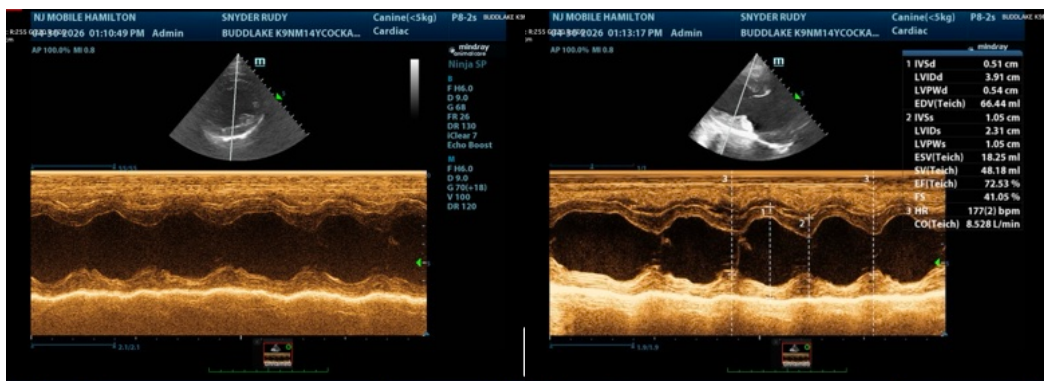
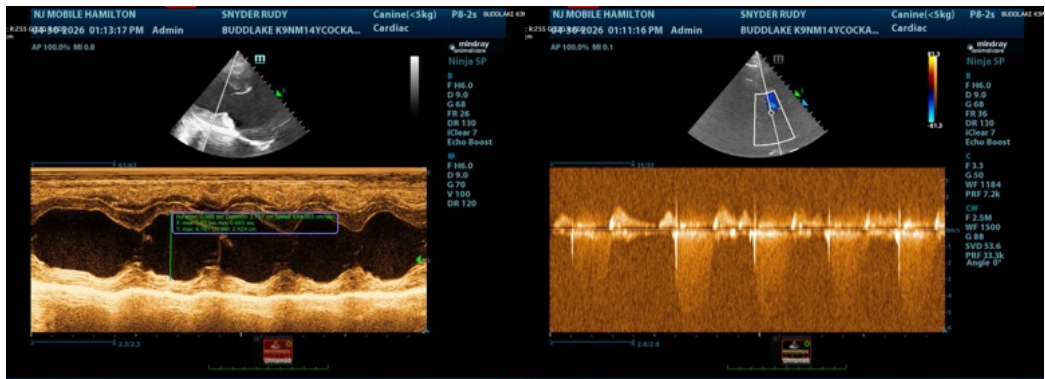
DATE

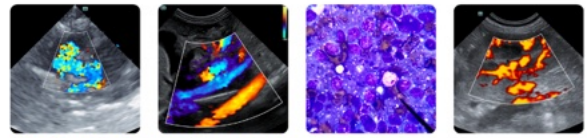
4/30/26

INTERPRETATION OF THE FINDINGS & FURTHER RECOMMENDATIONS

Given the coughing, this is consistent with stage B2+-C1 valvular disease. I recommend initiating Pimobendan at 0.3 mg/kg b.i.d., ace inhibitor at 0.5 mg/kg s.i.d. progressing to b.i.d. and Spironolactone at 1-2 mg/kg s.i.d., and Lasix at 1-2 mg/kg b.i.d. Hycodan for cough is indicated.

The heart is in a somewhat precarious state with volume overload and a heart that is working to compensate for the valvular insufficiency. Target respiratory rate is < 20 resp/minute after therapy. After initiating therapy, I recommend recheck on the clinical exam, BUN, Creatinine, USG, Chest radiographs & Blood pressure in 5-7 days. Recheck echo in 1 month. Earlier if clinical decompensation is occurring. I do not recommend anesthesia at this time until stabilization has occurred on the recommended medications. Repeat preanesthetic echo is ideal if anesthesia is eventually necessary.





PATIENT

Rudy Snyder

SPECIES

Canine

BREED

Cockapoo

SEX

Neutered male

AGE

14 year

WEIGHT

17.8 lbs

INTERPRETED BY

Eric Lindquist, DMV
DABVP, Cert. IVUSS

IMAGING PERFORMED BY

Rebecca Hamilton

HOSPITAL NAME

Budd Lake AH

REFERRING VET

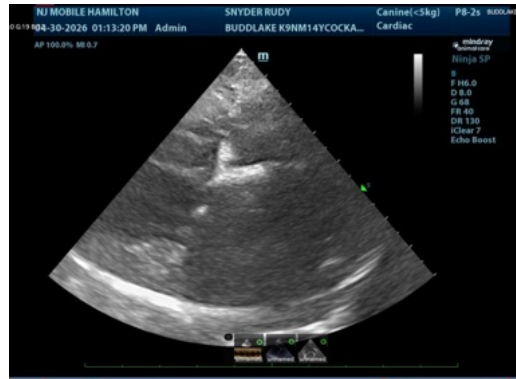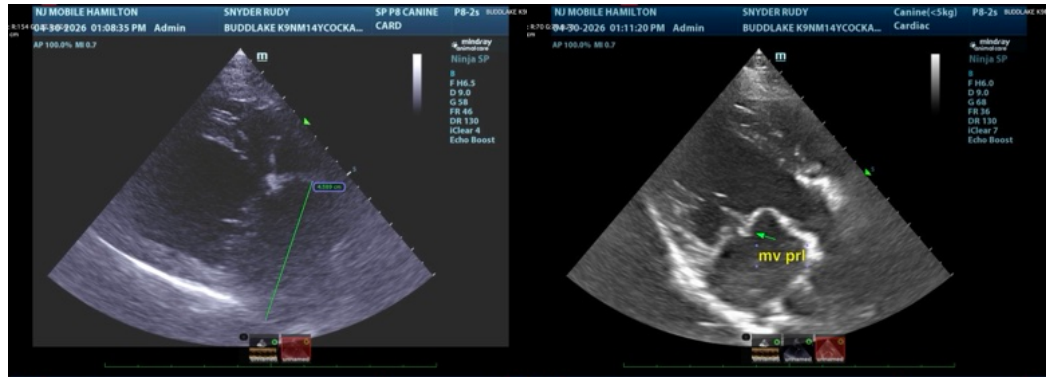
Dr. Welch

INVOICE

75044

DATE

4/30/26



The information and recommendations provided are based on the images presented by the referring veterinarian/sonographer. No evaluation can be communicated regarding pathology that was not visible in the image/video clips provided.

Thank you for this referral. If the clinical or image interpretation does not parallel your findings or if I can be of any further assistance please contact me.

Eric Lindquist, DMV, DABVP, Cert. IVUSS, CEO of SonoPath.com

info@SonoPath.com