



PATIENT

Lexie Werrell

SPECIES

Canine

BREED

Golden Retriever

SEX

Intact female

AGE

11 years

WEIGHT

47 lbs

INTERPRETED BY

Eric Lindquist, DMV,
DABVP (CFM), Cert.
IVUSS, CEO of
SonoPath.com

IMAGING PERFORMED BY

Chloe Lowe

HOSPITAL NAME

All Creatures Great
and Small Denville

REFERRING VET

Dr. Ashmore

INVOICE

74746

DATE

4/23/26

PRESENTING CLINICAL SIGNS

History: Pyometra times one week. Second opinion this morning, large white opacity cranial abdomen on radiograph.
WBC increased, increased liver values, mild anemia.

ULTRASONOGRAPHIC EXAMINATION OF THE ABDOMEN

Urinary System

The **urinary bladder**, trigone, and pelvic urethra presented normal thicknesses and normal tone. The ureters were not visible which is normal. No uroliths or sediment were visualized and anechoic urine was present. No evidence of inflammatory or neoplastic changes was noted. Ureteral papillae were normal.

The **kidneys** revealed largely normal size and structure, corticomedullary definition and ratio (cortex 1/3 of medulla) were essentially maintained with some age-related loss of curvilinear patterns regarding the capsule and C/M junction. The cortices presented largely uniform texture with some increased echogenicity expected for this age patient. Medullary structure differed distinctly from that of the cortex and no evidence of pelvic dilation was present. The right kidney measured 7.55 cm. The left kidney measured 7.0 cm.

A large **pyometra** was noted in this patient with over distension to 8.0 cm. The wall was thickened. There was reactive mesentery and slight free fluid noted. The ovaries were cystic. The right ovary measured 3.0 cm.

The iliac lymph nodes were slightly enlarged/reactive.

Adrenal Glands

The **adrenal glands** appeared slightly enlarged and swollen. No evidence of focal capsular expansion or invasion into the phrenic veins was noted. No overt suspicion of neoplasia was noted. This is considered likely a hyperplastic change associated with stress or adrenal endocrinopathy (PDH). If isosthenuria is persistently present and the patient morphologically suggests Cushing's disease then ACTH testing would be indicated. The left adrenal gland measured 2.2 x 0.8 cm at the cranial pole and 0.88 cm at the caudal pole. The right adrenal gland measured 2.03 x 1.32 cm at the cranial pole and 0.67 cm at the caudal pole.

Spleen

The **spleen** presented a smooth homogeneous parenchyma hyperechoic to liver and renal cortical parenchyma. The capsule was smooth without noticeable expansion or deviation from within the spleen or adjacent pathology. The splenic vasculature demonstrated normal volume without signs of congestion or thrombosis. No sonographic evidence of acute or chronic inflammatory, neoplastic, or infarctual changes was noted.



PATIENT

Lexie Werrell

Liver

SPECIES

Canine

BREED

Golden Retriever

SEX

Intact female

AGE

11 years

WEIGHT

47 lbs

INTERPRETED BY

Eric Lindquist, DMV,
DABVP (CFM), Cert.
IVUSS, CEO of
SonoPath.com

IMAGING PERFORMED BY

Chloe Lowe

HOSPITAL NAME

All Creatures Great
and Small Denville

REFERRING VET

Dr. Ashmore

INVOICE

74746

DATE

4/23/26

The **liver** images submitted revealed subjectively normal liver size, contour, and structure. Parenchymal echogenicity was naturally coarse and hypoechoic to the spleen. Vascular and biliary tracts were of normal volume with no evidence of congestion. The gallbladder presented acceptably thin walls with primarily anechoic content. The cystic and common bile ducts were normal. No pathological hepatic lymphadenopathy was evident. No overt structural evidence of inflammatory, infiltrative or regenerative pathology was evident.

Gastrointestinal

Examination of the **gastrointestinal tract** revealed a stomach and intestine free of stasis, of normal wall thickness, acceptable curvilinear mural detail, and peristaltic activity. Small and large intestine demonstrated normal luminal chyme and stool consistency respectively. No obstructive or overt infiltrative disease was noted. No associated abnormal lymphatic activity was noted.

Pancreas

The base and limbs of the **pancreas** were observed to be largely isoechoic to surrounding omental fat. Pancreatic duct and capsular contour were acceptably normal and parenchyma respected normal curvilinear patterns. No overt evidence of active inflammatory or neoplastic disease was noted.

ULTRASONOGRAPHIC FINDINGS

Large pyometra, luminal over distension up to 8.0 cm.

Polycystic ovaries.

Mild bilateral adrenal hypertrophy, possibly stress related to emerging PDH.

INTERPRETATION OF THE FINDINGS & FURTHER RECOMMENDATIONS

Immediate ovariohysterectomy is recommended in this patient.



PATIENT

Lexie Werrell

SPECIES

Canine

BREED

Golden Retriever

SEX

Intact female

AGE

11 years

WEIGHT

47 lbs

INTERPRETED BY

Eric Lindquist, DMV,
 DABVP (CFM), Cert.
 IVUSS, CEO of
 SonoPath.com

**IMAGING
 PERFORMED BY**

Chloe Lowe

HOSPITAL NAME

All Creatures Great
 and Small Denville

REFERRING VET

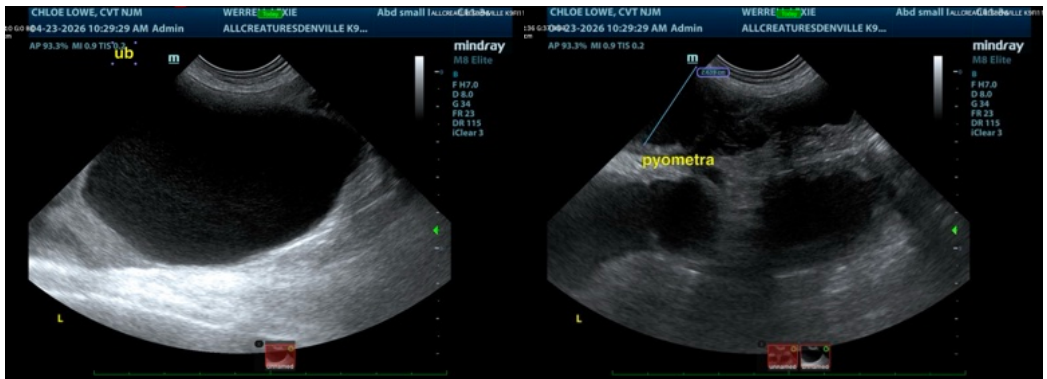
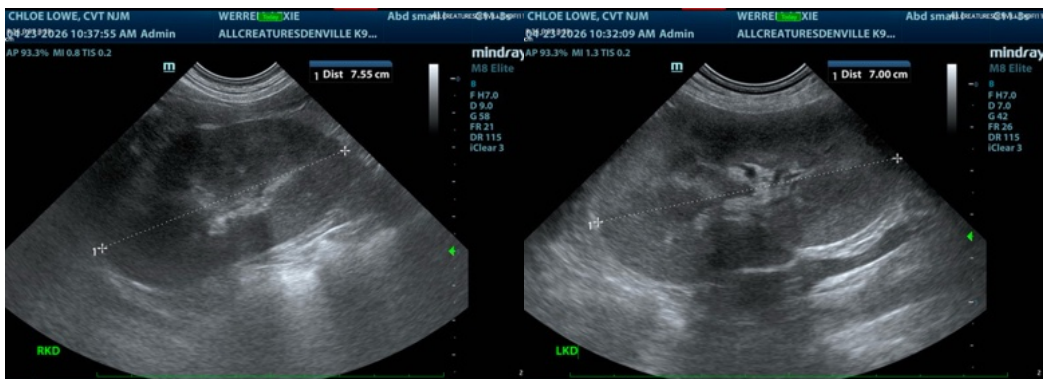
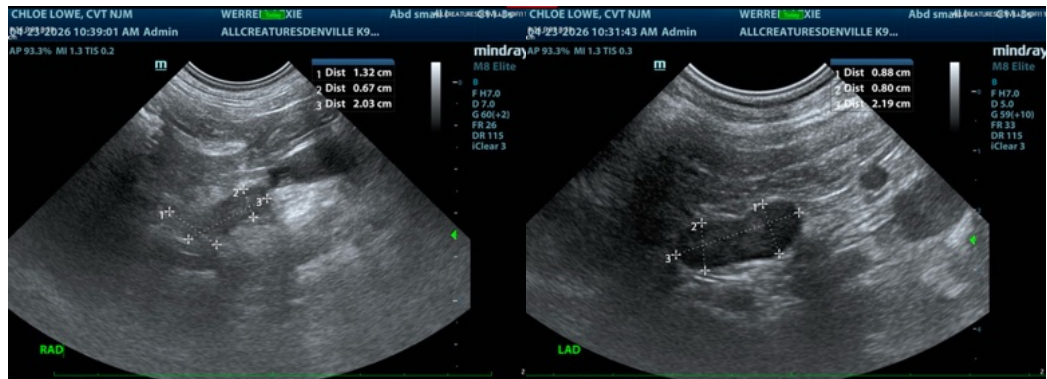
Dr. Ashmore

INVOICE

74746

DATE

4/23/26





PATIENT

Lexie Werrell

SPECIES

Canine

BREED

Golden Retriever

SEX

Intact female

AGE

11 years

WEIGHT

47 lbs

INTERPRETED BY

Eric Lindquist, DMV, DABVP (CFM), Cert. IVUSS, CEO of SonoPath.com

IMAGING PERFORMED BY

Chloe Lowe

HOSPITAL NAME

All Creatures Great and Small Denville

REFERRING VET

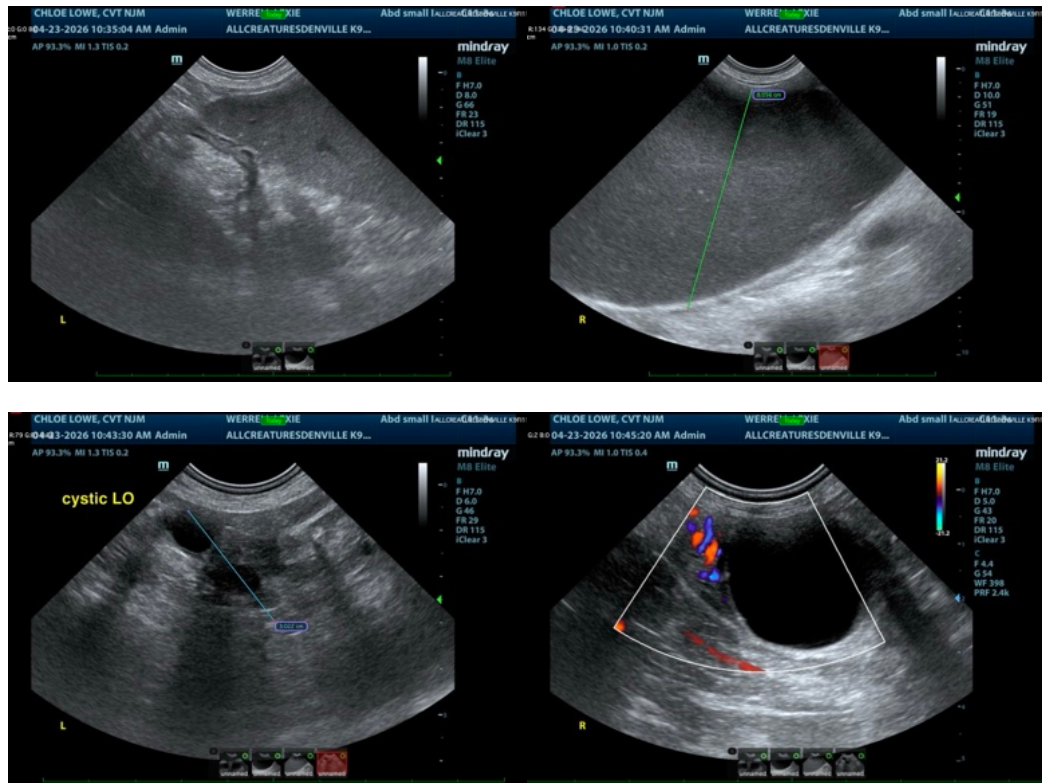
Dr. Ashmore

INVOICE

74746

DATE

4/23/26



The information and recommendations provided are based on the images presented by the referring veterinarian/sonographer. No evaluation can be communicated regarding pathology that was not visible in the image/video clips provided.

Thank you for this referral. If the clinical or image interpretation does not parallel your findings or if I can be of any further assistance please contact me.

Eric Lindquist, DMV, DABVP (CFM), Cert. IVUSS, CEO of SonoPath.com

Info@SonoPath.com