



PATIENT

Minx Valenza

SPECIES

Feline

BREED

Domestic Shorthair

SEX

Spayed female

AGE

11 years

WEIGHT

11.6 lbs

INTERPRETED BY

Eric Lindquist, DMV,
 DABVP (CFM), Cert.
 IVUSS, CEO of
 SonoPath.com

IMAGING PERFORMED BY

Chloe Lowe

HOSPITAL NAME

All Animal Veterinary
 Services

REFERRING VET

Dr. Acworth

INVOICE

74485

DATE

4/15/26

PRESENTING CLINICAL SIGNS

History: Congestive heart failure, hyperthyroid.
 Methimazole 5 mg 1/2 bid started 2 weeks ago, lasix 12.5mg 1/2 bid and enalapril 2.4 mg 1 Sid started 3 days ago.

ULTRASONOGRAPHIC EXAMINATION OF THE HEART

The echocardiogram in this patient demonstrated volume overload of the left and right atria with tachycardia. Mitral and tricuspid insufficiency was noted. There was slight pericardial effusion noted. The left ventricular septum presented hypokinesis with adequate contractility in the left ventricular free wall. Pleural and slight pericardial effusion was noted owing to left and right sided heart failure. The hepatic veins were dilated with a mild amount of ascites.

FELINE CARDIAC PARAMETERS	BODY WEIGHT (kg)	HR (BPM)	IVSd (cm)	LVIDd (cm)	LVWd (cm)	FS (%)	EF (%)
NORMAL PARAMETER	-----	150-240	0.3-0.6	1.0-2.1	0.25-0.6	35-67	80-100
PATIENT	11.6 lbs	265	0.59	1.57	0.59	38	72
FELINE CARDIAC PARAMETERS	LA/AO (M-mode)	LA/AO HEART BASE (Sisson)	LAD LA MAX 4 Chamber		LVOT VEL. (m/s)	RVOT VEL. (m/s)	IVRT (m/)
NORMAL PARAMETER	<1.5	1.6	0.7-1.7		<1.6	<1.3	40-60
PATIENT	2.0	1.3	1.9				NM
Adapted from June Boon, Veterinary Echocardiography, 1998 Sisson D et al. JVIM 1991; 5: 232, Jacobs et al. Am J Vet Res 1985; 46:1705							

ULTRASONOGRAPHIC FINDINGS

Unclassified cardiomyopathy with tachycardia, likely tachyarrhythmia.

INTERPRETATION OF THE FINDINGS & FURTHER RECOMMENDATIONS

EKG is indicated. I recommend adding Pimobendan to the protocol at 0.3 mg/kg b.i.d. and Plavix therapy at 18.75 mg s.i.d. The prognosis is guarded. The blood pressure measurements should be monitored. EKG is essential as well as basal respiratory rate. BUN, creatinine and urine specific gravity should also be evaluated. Recheck echocardiogram is recommended in a month or earlier if clinical signs persist.



PATIENT

Minx Valenza

SPECIES

Feline

BREED

Domestic Shorthair

SEX

Spayed female

AGE

11 years

WEIGHT

11.6 lbs

INTERPRETED BY

Eric Lindquist, DMV, DABVP (CFM), Cert. IVUSS, CEO of SonoPath.com

IMAGING PERFORMED BY

Chloe Lowe

HOSPITAL NAME

All Animal Veterinary Services

REFERRING VET

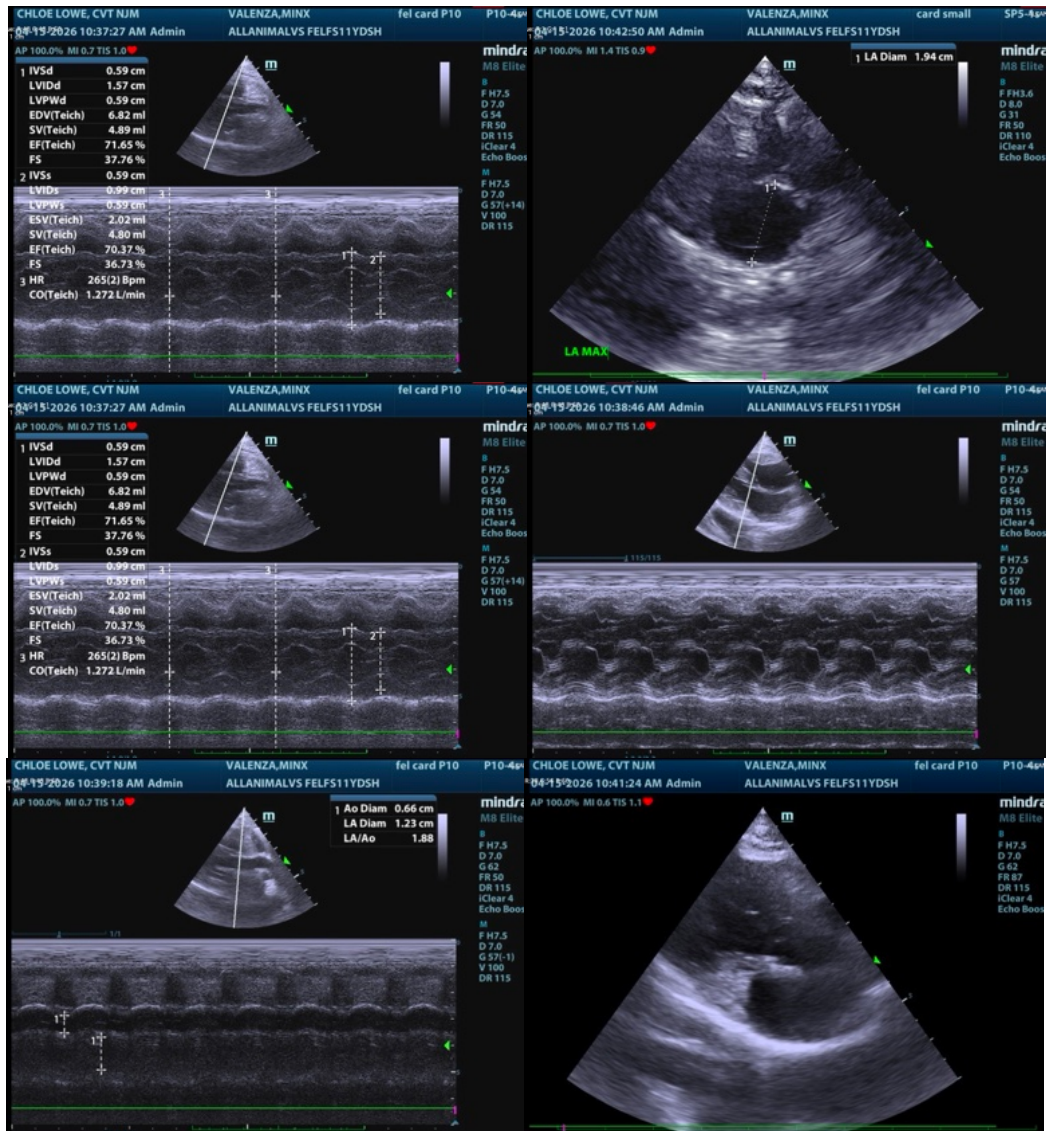
Dr. Acworth

INVOICE

74485

DATE

4/15/26



The information and recommendations provided are based on the images presented by the referring veterinarian/sonographer. No evaluation can be communicated regarding pathology that was not visible in the image/video clips provided.

Thank you for this referral. If the clinical or image interpretation does not parallel your findings or if I can be of any further assistance please contact me.

Eric Lindquist, DMV, DABVP (CFM), Cert. IVUSS, CEO of SonoPath.com

Info@SonoPath.com