



PATIENT

Rudy Phillips

SPECIES

Canine

BREED

Mix

SEX

Neutered male

AGE

13 years

WEIGHT

47.6 lbs

INTERPRETED BY

Eric Lindquist, DMV,
DABVP (CFM), Cert.
IVUSS, CEO of
SonoPath.com

IMAGING PERFORMED BY

Chloe Lowe

HOSPITAL NAME

Middlehope VH

REFERRING VET

Dr. Rich

INVOICE

74425

DATE

4/13/26

PRESENTING CLINICAL SIGNS

History: Metastasis check. Skin mass biopsied, malignant melanoma. Fluoxetine 20 mg Sid.
Abnormal PE/Chem/CBC/UA Results: WNL

ULTRASONOGRAPHIC EXAMINATION OF THE ABDOMEN

Urinary System

The **urinary bladder**, trigone, and pelvic urethra presented normal thicknesses and normal tone. The ureters were not visible which is normal. No uroliths or sediment were visualized and anechoic urine was present. No evidence of inflammatory or neoplastic changes was noted. Ureteral papillae were normal.

The **kidneys** revealed normal size and structure, corticomedullary definition and ratio for this age. The cortices presented largely uniform texture with normal echogenic relationship to liver and spleen. Medullary structure differed distinctly from the cortex and no evidence of pelvic dilation was present. The capsules were acceptably uniform without significant irregularities. The right kidney measured 5.8 cm. The left kidney measured 5.12 cm.

Adrenal Glands

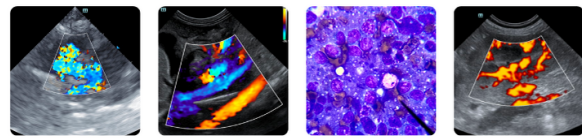
Both **adrenal glands** were visualized and recognized as having normal size, position and echogenicity for this breed. The phrenic vasculature, glandular echogenicity and detail were unremarkable. Capsule, cortex, and medullary definition were normal for this age patient. The left adrenal gland measured 2.59 x 0.55 cm at the caudal pole and 0.57 cm at the cranial pole. The right adrenal gland revealed a slight irregularity to the cranial pole was noted. The right adrenal gland measured 2.34 x 1.05 cm at the cranial pole and 0.63 cm at the caudal pole.

Spleen

The **spleen** presented a smooth homogeneous parenchyma hyperechoic to liver and renal cortical parenchyma. The capsule was smooth without noticeable expansion or deviation from within the spleen or adjacent pathology. The splenic vasculature demonstrated normal volume without signs of congestion or thrombosis. No sonographic evidence of acute or chronic inflammatory, neoplastic, or infarctual changes was noted.

Liver

The **liver** images from right and left intercostal as well as subcostal views revealed subjectively normal liver size, contour, and structure. Some age-related parenchymal remodeling was noted but likely not clinically significant at this time. Vascular and biliary tracts were of normal volume and no evidence of congestion was noted. The gallbladder presented some dependent debris with essentially normal contour. The cystic and common bile ducts were normal. No overt evidence of active inflammatory,



PATIENT

Rudy Phillips

SPECIES

Canine

BREED

Mix

SEX

Neutered male

AGE

13 years

WEIGHT

47.6 lbs

INTERPRETED BY

Eric Lindquist, DMV,
DABVP (CFM), Cert.
IVUSS, CEO of
SonoPath.com

IMAGING PERFORMED BY

Chloe Lowe

HOSPITAL NAME

Middlehope VH

REFERRING VET

Dr. Rich

INVOICE

74425

DATE

4/13/26

infiltrative or regenerative pathology was noted but should be paired with current or past LE elevations regarding any clinical significance to this presentation. The hepatic lymph nodes were unremarkable.

Gastrointestinal

Examination of the **gastrointestinal tract** revealed a stomach and intestine free of stasis, of normal wall thickness, acceptable curvilinear mural detail, and peristaltic activity. Small and large intestine demonstrated normal luminal chyme and stool consistency respectively. No obstructive or overt infiltrative disease was noted. No associated abnormal lymphatic activity was noted.

Pancreas

The base and limbs of the **pancreas** were observed to be largely isoechoic to surrounding omental fat. Pancreatic duct and capsular contour were acceptably normal and parenchyma respected normal curvilinear patterns. No overt evidence of active inflammatory or neoplastic disease was noted.

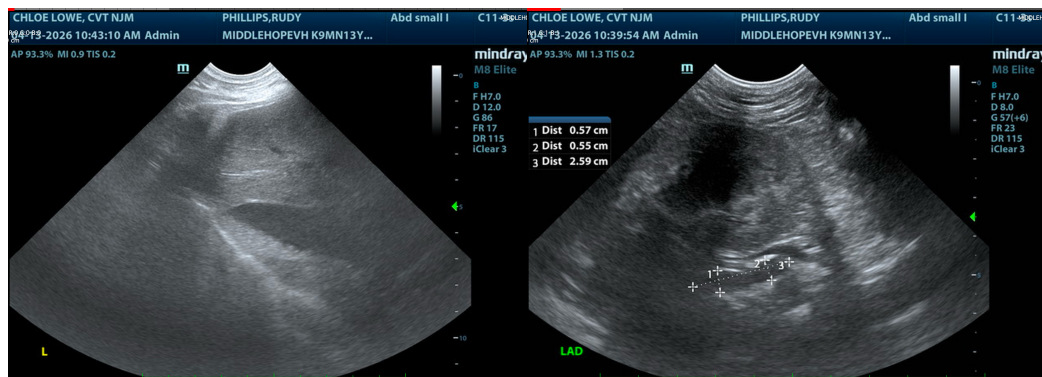
ULTRASONOGRAPHIC FINDINGS

Age related abdominal changes.

Slight irregular right adrenal gland to monitor.

INTERPRETATION OF THE FINDINGS & FURTHER RECOMMENDATIONS

There was no evidence of significant primary or metastatic disease.





PATIENT

Rudy Phillips

SPECIES

Canine

BREED

Mix

SEX

Neutered male

AGE

13 years

WEIGHT

47.6 lbs

INTERPRETED BY

Eric Lindquist, DMV,
 DABVP (CFM), Cert.
 IVUSS, CEO of
 SonoPath.com

IMAGING PERFORMED BY

Chloe Lowe

HOSPITAL NAME

Middlehope VH

REFERRING VET

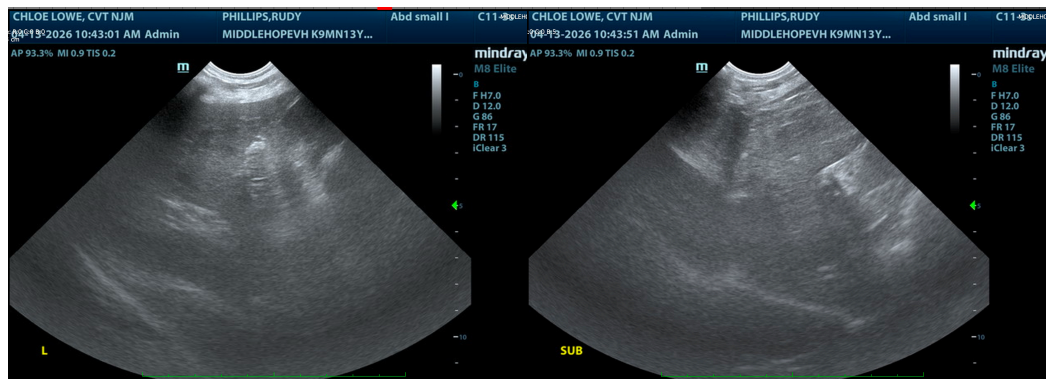
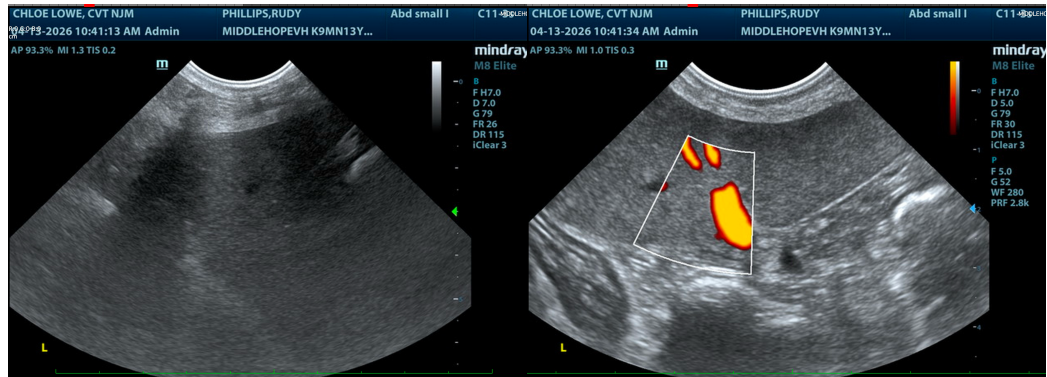
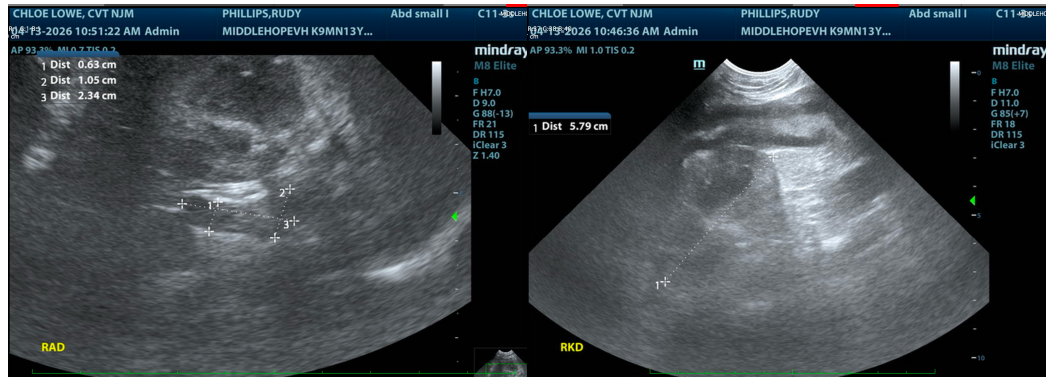
Dr. Rich

INVOICE

74425

DATE

4/13/26



The information and recommendations provided are based on the images presented by the referring veterinarian/sonographer. No evaluation can be communicated regarding pathology that was not visible in the image/video clips provided.

Thank you for this referral. If the clinical or image interpretation does not parallel your findings or if I can be of any further assistance please contact me.

Eric Lindquist, DMV, DABVP (CFM), Cert. IVUSS, CEO of SonoPath.com

Info@SonoPath.com