



PATIENT

Brady Raimondo

SPECIES

Canine

BREED

Hound Mix

SEX

Neutered male

AGE

12 years

WEIGHT

68 lbs

INTERPRETED BY

Eric Lindquist, DMV,
 DABVP (CFM), Cert.
 IVUSS, CEO of
 SonoPath.com

IMAGING PERFORMED BY

Vincent Ravancho,
 CVT

HOSPITAL NAME

The Gentle Vet

REFERRING VET

Dr. Dulude

INVOICE

72297

DATE

3/6/26

PRESENTING CLINICAL SIGNS

- 6 Month recheck - Stage B2 Valvular dz
- Medications - Pimobendan, Enalapril, Spironolactone, Sotalol, Tylan Powder

ULTRASONOGRAPHIC EXAMINATION OF THE HEART

The cardiac presentation in this patient presented mild to moderate persistent volume overload in the left atrium and left ventricle. Prolapse of the anterior mitral valve leaflet was noted. Aortic and pulmonic outflow velocities were adequate. Mild tricuspid insufficiency was noted. The right atrium and right ventricle were unremarkable. The pericardium and pleural spaces were unremarkable. Bradyarrhythmia was noted. The hepatic veins were not dilated.

CANINE CARDIAC PARAMETERS	MR VMAX (m/s)	TR VMAX (m/s)	LA/AO	LA/AO (Heart Base)	FS (%)	EF (%)	EPSS (cm)
NORMAL PARAMETER	4.5-5.5	<2.7	1.3	<1.6	28-40	40-100	<0.6
PATIENT	5.31	1.73	NM	1.9	30	57	0.53
CANINE CARDIAC PARAMETERS	HR (BPM)	AV VMAX (m/s)	PV MAX (m/s)	BODY WEIGHT	LA 2D short axis Base view (cm)	LVIDd Avg; 2D and m-mode short axis (cm)	LVIDs Avg; 2D and m-mode short axis (cm)
NORMAL PARAMETER	50-100	0.7-1.7	0.7-1.6	BELOW	BELOW	BELOW	BELOW
PATIENT	65	1.08	1.0	68 lbs	5.7	5.1	

ULTRASONOGRAPHIC FINDINGS

Brady arrhythmia and mild volume overload.

INTERPRETATION OF THE FINDINGS & FURTHER RECOMMENDATIONS

I recommend EKG to assess for potential heart block or other bradyarrhythmia. If the arrhythmia is able to be corrected then this will increase cardiac function and the patient not necessitate further treatment. The current dosing should prove adequate. However, adding Lasix at 1-2 mg/kg could be considered as well to help with the volume overload.



PATIENT

Brady Raimondo

SPECIES

Canine

BREED

Hound Mix

SEX

Neutered male

AGE

12 years

WEIGHT

68 lbs

INTERPRETED BY

Eric Lindquist, DMV,
 DABVP (CFM), Cert.
 IVUSS, CEO of
 SonoPath.com

**IMAGING
 PERFORMED BY**

Vincent Ravancho,
 CVT

HOSPITAL NAME

The Gentle Vet

REFERRING VET

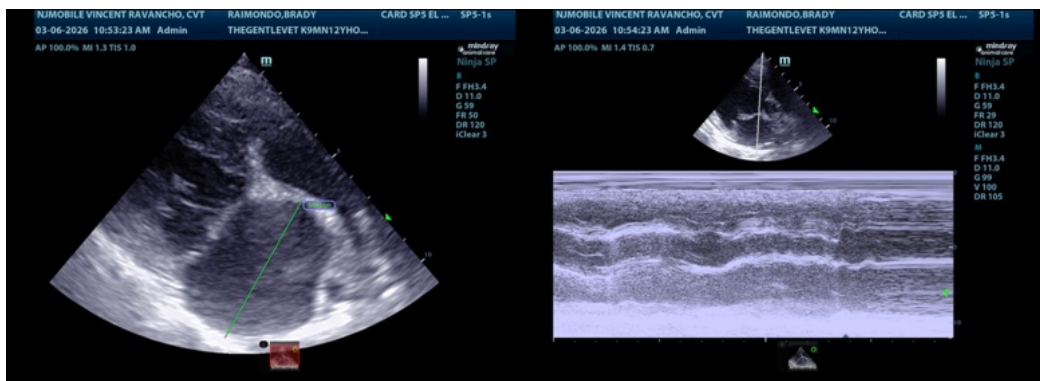
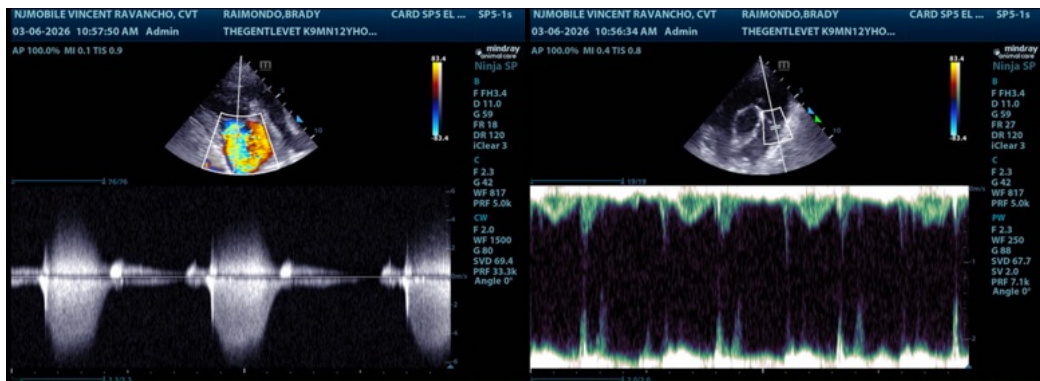
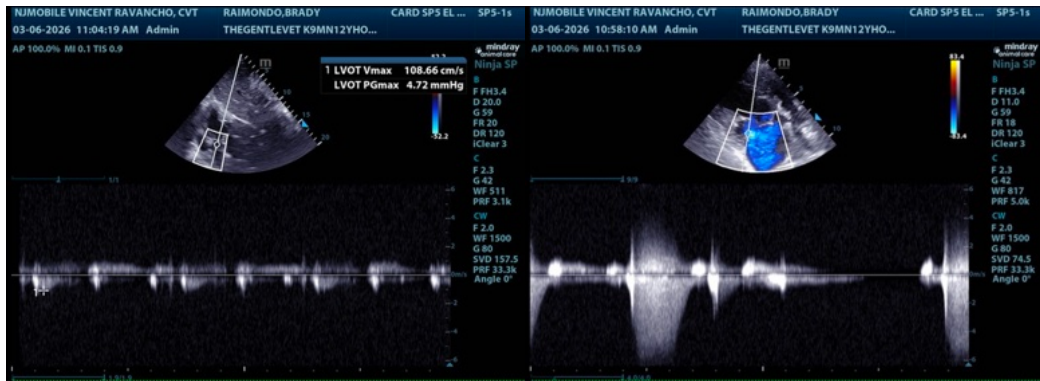
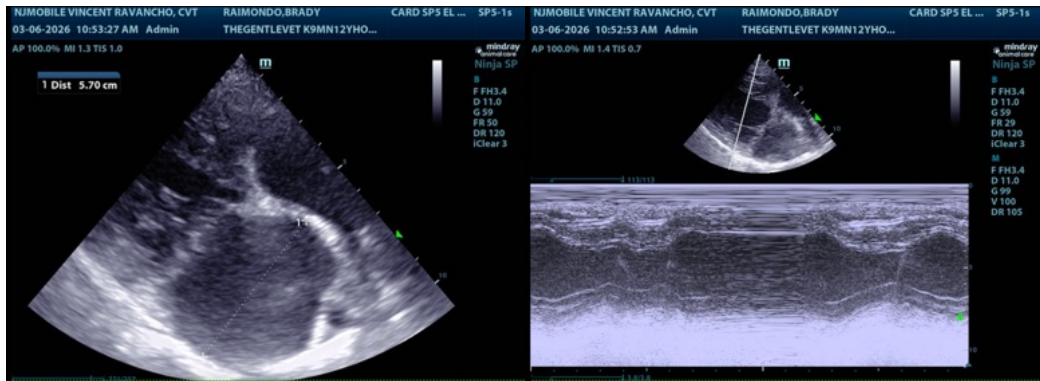
Dr. Dulude

INVOICE

72297

DATE

3/6/26





PATIENT

Brady Raimondo

SPECIES

Canine

BREED

Hound Mix

SEX

Neutered male

AGE

12 years

WEIGHT

68 lbs

INTERPRETED BY

Eric Lindquist, DMV,
DABVP (CFM), Cert.
IVUSS, CEO of
SonoPath.com

**IMAGING
PERFORMED BY**

Vincent Ravancho,
CVT

HOSPITAL NAME

The Gentle Vet

REFERRING VET

Dr. Dulude

INVOICE

72297

DATE

3/6/26

The information and recommendations provided are based on the images presented by the referring veterinarian/sonographer. No evaluation can be communicated regarding pathology that was not visible in the image/video clips provided.

Thank you for this referral. If the clinical or image interpretation does not parallel your findings or if I can be of any further assistance please contact me.

Eric Lindquist, DMV, DABVP (CFM), Cert. IVUSS, CEO of SonoPath.com

Info@SonoPath.com