



**PATIENT**

Jaxson Gambatese

**SPECIES**

Canine

**BREED**

Brussels Griffon

**SEX**

Neutered male

**AGE**

14 years

**WEIGHT**

10.6 lbs

**INTERPRETED BY**

Eric Lindquist, DMV,  
DABVP (CFM), Cert.  
IVUSS, CEO of  
SonoPath.com

**IMAGING PERFORMED BY**

Vincent Ravancho,  
CVT

**HOSPITAL NAME**

All Creatures Great  
Samll Denville

**REFERRING VET**

Dr. Ashmore

**INVOICE**

78374

**DATE**

3/30/26

**PRESENTING CLINICAL SIGNS**

- Recheck MMVD and pulmonary hypertension from cardiologist
- Current medications - Vetmedin, Sildenafil 20mg TID

**ULTRASONOGRAPHIC EXAMINATION OF THE HEART**

The **echocardiogram** presented moderate to severe right atrial enlargement. Pulmonary artery dilation and eccentric hypertrophy of the left ventricle was noted. There was severe tricuspid insufficiency noted. This is consistent with pulmonary hypertension. Mitral insufficiency was noted with volume contracted left ventricle and left atrium.

| <b>CANINE CARDIAC PARAMETERS</b> | <b>MR VMAX (m/s)</b> | <b>TR VMAX (m/s)</b> | <b>LA/AO</b>        | <b>LA/AO (Heart Base)</b> | <b>FS (%)</b>                          | <b>EF (%)</b>                                   | <b>EPSS (cm)</b>                                |
|----------------------------------|----------------------|----------------------|---------------------|---------------------------|--|---|---|
| <b>NORMAL PARAMETER</b>          | 4.5-5.5              | <2.7                 | 1.3                 | <1.6                      | 28-40                                  | 40-100  | <0.6  |
| <b>PATIENT</b>                   | NM                   | 4.0                  | 1.0                 | 1.4                       | 35                                     | 70  | NM  |
| <b>CANINE CARDIAC PARAMETERS</b> | <b>HR (BPM)</b>      | <b>AV VMAX (m/s)</b> | <b>PV MAX (m/s)</b> | <b>BODY WEIGHT</b>        | <b>LA 2D short axis Base view (cm)</b> | <b>LVIDd Avg; 2D and m-mode short axis (cm)</b> | <b>LVIDs Avg; 2D and m-mode short axis (cm)</b> |
| <b>NORMAL PARAMETER</b>          | 50-100               | 0.7-1.7              | 0.7-1.6             | BELOW                     | BELOW                                  | BELOW   | BELOW   |
| <b>PATIENT</b>                   | 120                  | 1.2                  | 0.8                 | 10.6 lbs                  | 2.0                                    | 1.7   |   |

**ULTRASONOGRAPHIC FINDINGS**

Right sided cardiac enlargement.  
Pulmonary hypertension.

**INTERPRETATION OF THE FINDINGS & FURTHER RECOMMENDATIONS**

I recommend continuation of the sildenafil and Vetmedin in this patient. I recommend adding Spironolactone at 1-2 mg/kg s.i.d. If the Sildenafil dose has been steady over the last 2-4 weeks then increasing Sildenafil by 0.5 mg/kg b.i.d. can also be considered. Prognosis is guarded.



**PATIENT**

Jaxson Gambatese

**SPECIES**

Canine

**BREED**

Brussels Griffon

**SEX**

Neutered male

**AGE**

14 years

**WEIGHT**

10.6 lbs

**INTERPRETED BY**

Eric Lindquist, DMV,  
 DABVP (CFM), Cert.  
 IVUSS, CEO of  
 SonoPath.com

**IMAGING PERFORMED BY**

Vincent Ravancho,  
 CVT

**HOSPITAL NAME**

All Creatures Great  
 Samll Denville

**REFERRING VET**

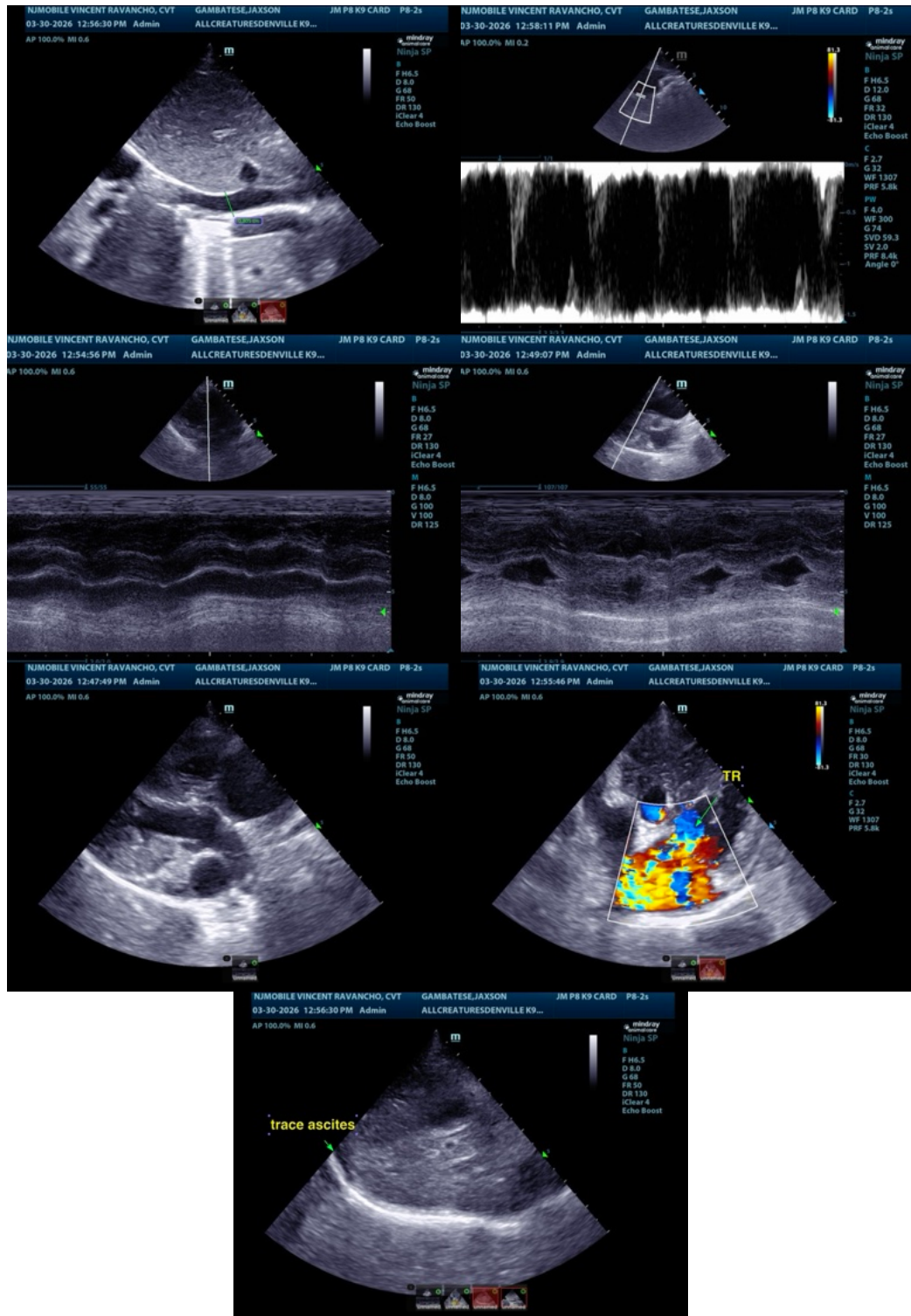
Dr. Ashmore

**INVOICE**

78374

**DATE**

3/30/26



The information and recommendations provided are based on the images presented by the referring veterinarian/sonographer. No evaluation can be communicated regarding pathology that was not visible in the image/video clips provided.



**PATIENT**

Jaxson Gambatese

Thank you for this referral. If the clinical or image interpretation does not parallel your findings or if I can be of any further assistance please contact me.

**SPECIES**

Canine

Eric Lindquist, DMV, DABVP (CFM), Cert. IVUSS, CEO of SonoPath.com

Info@SonoPath.com

**BREED**

Brussels Griffon

**SEX**

Neutered male

**AGE**

14 years

**WEIGHT**

10.6 lbs

**INTERPRETED BY**

Eric Lindquist, DMV,  
DABVP (CFM), Cert.  
IVUSS, CEO of  
SonoPath.com

**IMAGING  
PERFORMED BY**

Vincent Ravancho,  
CVT

**HOSPITAL NAME**

All Creatures Great  
Samll Denville

**REFERRING VET**

Dr. Ashmore

**INVOICE**

78374

**DATE**

3/30/26