



PATIENT

Oreo Bertoline

SPECIES

Feline

BREED

Domestic Medium Hair

SEX

Spayed female

AGE

8 years

WEIGHT

9.8 lbs

INTERPRETED BY

Eric Lindquist, DMV
DABVP, Cert. IVUSS

IMAGING PERFORMED BY

Dr. Ken Leal

HOSPITAL NAME

Andover AH

REFERRING VET

Dr.
Vanderbogart/Lawlor

INVOICE

72169

DATE

3/3/26

PRESENTING CLINICAL SIGNS

- Overgrooming since beginning of January 2026
- Tried diet change (off chx, start fish)
- Medications: Revolution, gabapentin
- Saw slight improvement with meds.

ULTRASONOGRAPHIC EXAMINATION OF THE ABDOMEN

Urinary System

The **urinary bladder**, trigone, and pelvic urethra presented normal thicknesses and normal tone. The ureters were not visible which is normal. Sand accumulation was noted, grouping of which measured 1.8 cm and was non-obstructive at the time of the sonogram. No evidence of inflammatory or neoplastic changes was noted. Ureteral papillae were normal.

The **kidneys** revealed normal size and structure, corticomedullary definition and ratio for this age. The cortices presented largely uniform texture with normal echogenic relationship to liver and spleen. Medullary structure differed distinctly from the cortex and no evidence of pelvic dilation was present. The capsules were acceptably uniform without significant irregularities. The left kidney measured 4.1 cm. The right kidney measured 4.44 cm.

Adrenal Glands

Both **adrenal glands** were visualized and recognized as having normal shape, size, position and echogenicity for this breed. The phrenic vasculature, glandular echogenicity and detail were unremarkable. Capsule, cortex, and medullary definition were normal for this age patient. The left adrenal gland measured 0.41 cm. The right adrenal gland measured 0.48 cm.

Spleen

The **spleen** presented a smooth homogeneous parenchyma hyperechoic to liver and renal cortical parenchyma. The capsule was smooth without noticeable expansion or deviation from within the spleen or adjacent pathology. The splenic vasculature demonstrated normal volume without signs of congestion or thrombosis. No sonographic evidence of acute or chronic inflammatory, neoplastic, or infarctual changes was noted.

Liver

The **liver** images submitted revealed subjectively normal liver size, contour, and structure. Parenchymal echogenicity was naturally coarse and hypoechoic to the spleen. Vascular and biliary tracts were of normal volume with no evidence of congestion. The gallbladder presented acceptably thin walls with primarily anechoic content. The cystic and common bile ducts were normal. No pathological hepatic lymphadenopathy was evident. No overt structural evidence of inflammatory, infiltrative or regenerative pathology was evident.



PATIENT

Oreo Bertoline

SPECIES

Feline

BREED

Domestic Medium Hair

SEX

Spayed female

AGE

8 years

WEIGHT

9.8 lbs

INTERPRETED BY

Eric Lindquist, DMV
DABVP, Cert. IVUSS

IMAGING PERFORMED BY

Dr. Ken Leal

HOSPITAL NAME

Andover AH

REFERRING VET

Dr.
Vanderbogart/Lawlor

INVOICE

72169

DATE

3/3/26

Gastrointestinal

Examination of the **gastrointestinal tract** revealed a stomach and intestine free of stasis, of normal wall thickness, acceptable curvilinear mural detail, and peristaltic activity. Small and large intestine demonstrated normal luminal chyme and stool consistency respectively. No obstructive or overt infiltrative disease was noted. No associated abnormal lymphatic activity was noted.

Pancreas

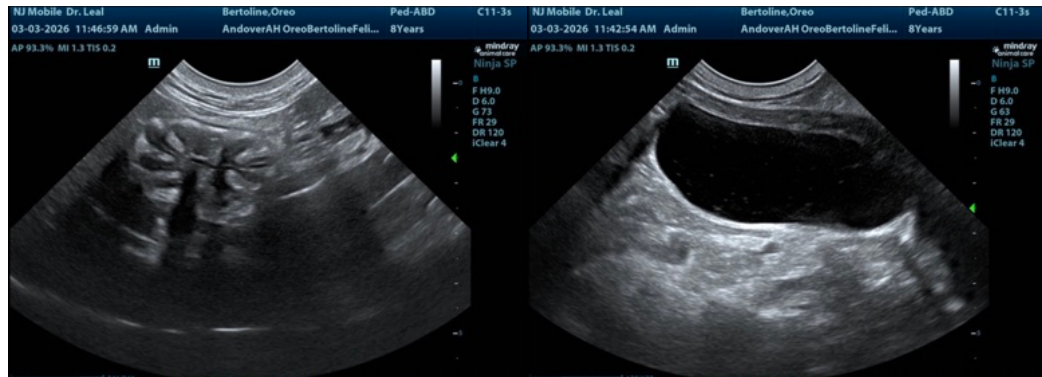
The **pancreas** was mildly heterogenous with slight duct dilation.

ULTRASONOGRAPHIC FINDINGS

- Bladder sand, likely struvite accumulation.
- Subtle heterogenous pancreatic changes.
- Otherwise, unremarkable abdomen.

INTERPRETATION OF THE FINDINGS & FURTHER RECOMMENDATIONS

Bladder sediment dissolution protocol is recommended based on urinalysis results. Subxiphoid palpation is recommended. Recheck sonogram is recommended in 6-8 weeks to assess any progress in bladder sand dissolution.





PATIENT

Oreo Bertoline

SPECIES

Feline

BREED

Domestic Medium Hair

SEX

Spayed female

AGE

8 years

WEIGHT

9.8 lbs

INTERPRETED BY

Eric Lindquist, DMV
 DABVP, Cert. IVUS

IMAGING PERFORMED BY

Dr. Ken Leal

HOSPITAL NAME

Andover AH

REFERRING VET

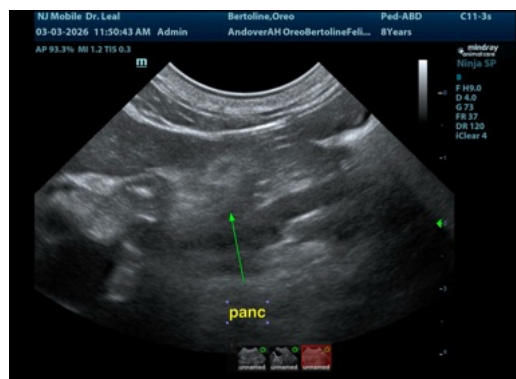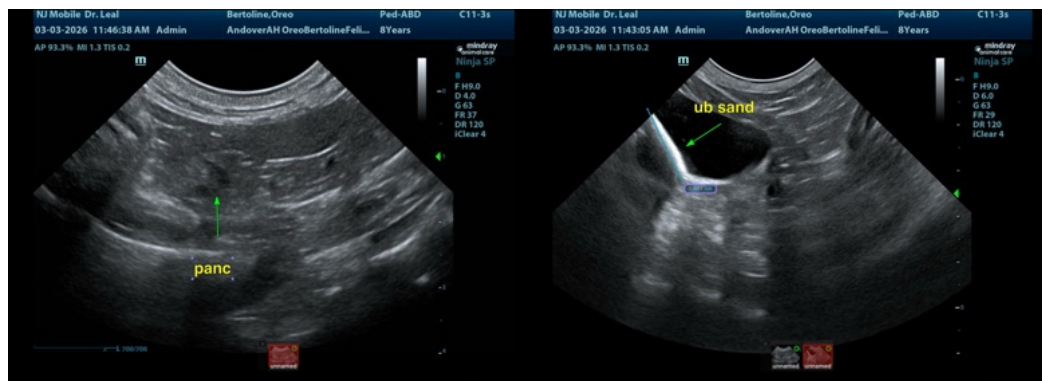
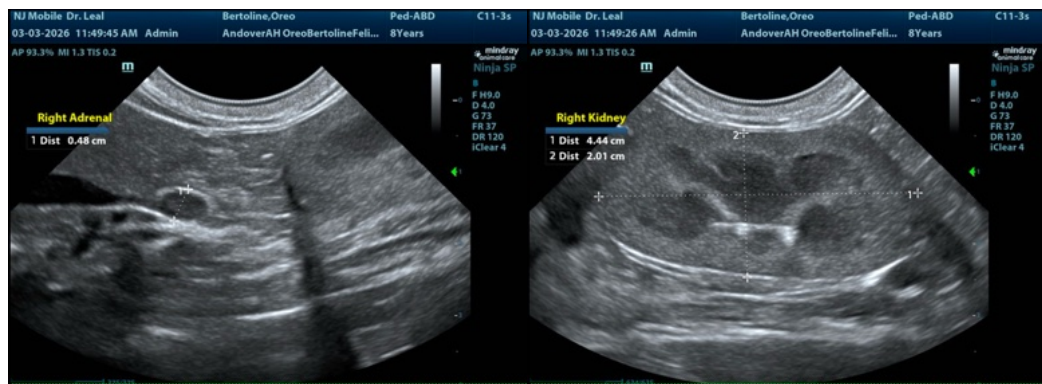
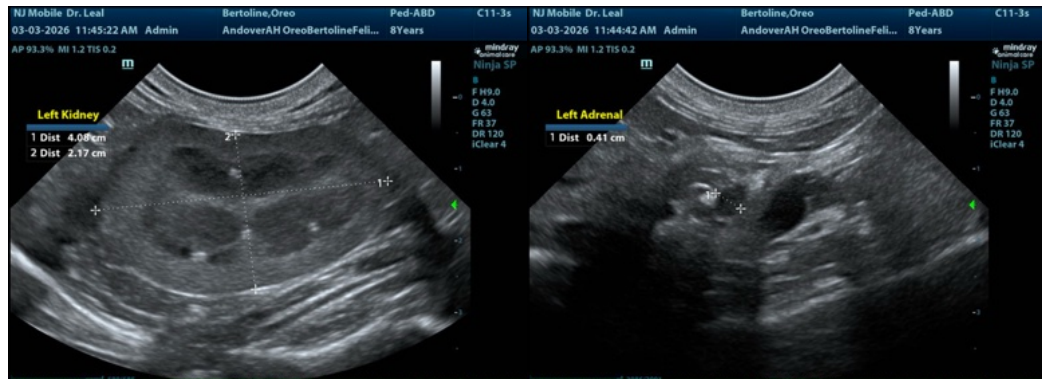
Dr. Vanderbogart/Lawlor

INVOICE

72169

DATE

3/3/26





PATIENT

Oreo Bertoline

SPECIES

Feline

BREED

Domestic Medium Hair

SEX

Spayed female

AGE

8 years

WEIGHT

9.8 lbs

INTERPRETED BY

Eric Lindquist, DMV
DABVP, Cert. IVUSS

**IMAGING
PERFORMED BY**

Dr. Ken Leal

HOSPITAL NAME

Andover AH

REFERRING VET

Dr.
Vanderbogart/Lawlor

INVOICE

72169

DATE

3/3/26

The information and recommendations provided are based on the images presented by the referring veterinarian/sonographer. No evaluation can be communicated regarding pathology that was not visible in the image/video clips provided.

Thank you for this referral. If the clinical or image interpretation does not parallel your findings or if I can be of any further assistance please contact me.

Eric Lindquist, DMV, DABVP, Cert. IVUSS, CEO of SonoPath.com

info@SonoPath.com