



PATIENT

Ravella Gaurino

SPECIES

Canine

BREED

Shiba Inu

SEX

Spayed female

AGE

14 years

WEIGHT

-

INTERPRETED BY

Eric Lindquist, DMV,
DABVP (CFM), Cert.
IVUSS, CEO of
SonoPath.com

IMAGING PERFORMED BY

Chloe Lowe/ Abd
Shari Reffi/Echo

HOSPITAL NAME

Midland Park VH

REFERRING VET

Dr. Shokoff

INVOICE

72089

DATE

3/2/26

PRESENTING CLINICAL SIGNS

- Hunched/ uncomfortable, decreased appetite/ thirst, straining to urinate/ defecate
- Grade 2/6 systolic murmur
- NSF on chest/ abdomen rads
- Tense abd/ dorsal spine - r/o and discomfort vs back pain
- gabapentin and simparica trio
- BUN 105, ALKP 231 UA pending

ULTRASONOGRAPHIC EXAMINATION OF THE ABDOMEN

Urinary System

The **urinary bladder**, trigone, and pelvic urethra presented normal thicknesses and normal tone. The ureters were not visible which is normal. No uroliths or sediment were visualized and anechoic urine was present. No evidence of inflammatory or neoplastic changes was noted. Ureteral papillae were normal.

The **kidneys** revealed largely normal size and structure, corticomedullary definition and ratio (cortex 1/3 of medulla) were essentially maintained with some age-related loss of curvilinear patterns regarding the capsule and C/M junction. The cortices presented largely uniform texture with some increased echogenicity expected for this age patient. Medullary structure differed distinctly from that of the cortex and no evidence of pelvic dilation was present. The right kidney measured 5.4 cm. The left kidney measured 4.6 cm.

Adrenal Glands

Both **adrenal glands** were visualized and recognized as having normal shape, size, position and echogenicity for this breed. The phrenic vasculature, glandular echogenicity and detail were unremarkable. Capsule, cortex, and medullary definition were normal for this age patient. The right adrenal gland measured 2.1 x 0.6 cm at the cranial pole and 0.54 cm at the caudal pole. The left adrenal gland measured 1.72 x 0.5 cm at the cranial pole and 0.52 cm at the caudal pole.

Spleen

The **spleen** was largely smooth with subtle heterogeneous parenchymal changes while maintaining normal echogenic relationship to the liver and kidney. These changes are consistent with normal age-related alteration. Micronodular hyperplasia pattern was noted. The splenic vasculature demonstrated normal volume without signs of congestion or significant contraction.

Liver

The **liver** images from right and left intercostal as well as subcostal views revealed subjectively normal liver size, contour, and structure. Some age-related parenchymal remodeling was noted but likely not clinically significant at this time. Vascular and biliary tracts were of normal volume and no evidence of



PATIENT

Ravella Gaurino

SPECIES

Canine

BREED

Shiba Inu

SEX

Spayed female

AGE

14 years

WEIGHT

-

INTERPRETED BY

Eric Lindquist, DMV,
DABVP (CFM), Cert.
IVUSS, CEO of
SonoPath.com

**IMAGING
PERFORMED BY**

Chloe Lowe/ Abd
Shari Reffi/Echo

HOSPITAL NAME

Midland Park VH

REFERRING VET

Dr. Shokoff

INVOICE

72089

DATE

3/2/26

congestion was noted. The gallbladder presented calculi. Grouping of which measured 2.2 cm and was non-obstructive. The cystic and common bile ducts were normal. No overt evidence of active inflammatory, infiltrative or regenerative pathology was noted but should be paired with current or past LE elevations regarding any clinical significance to this presentation. The hepatic lymph nodes were unremarkable.

Gastrointestinal

Examination of the **gastrointestinal tract** revealed a stomach and intestine free of stasis, of normal wall thickness, acceptable curvilinear mural detail, and peristaltic activity. Small and large intestine demonstrated normal luminal chyme and stool consistency respectively. No obstructive or overt infiltrative disease was noted. No associated abnormal lymphatic activity was noted.

Pancreas

The base and limbs of the **pancreas** were observed to be largely isoechoic to surrounding omental fat. Pancreatic duct and capsular contour were acceptably normal and parenchyma respected normal curvilinear patterns. No overt evidence of active inflammatory or neoplastic disease was noted.

ULTRASONOGRAPHIC EXAMINATION OF THE HEART

The echocardiogram in this patient demonstrated normal **left atrial** size based on 3 different LA measurement methods. Chamber volumes and echogenicity were normal. The cranial and caudal **mitral** valve leaflets presented vegetative thickening consistent with endocardiosis. Doppler indicated measurable insufficiency. The **left ventricle** presented thicknesses with linear contour and was not dilated nor restricted. The **myocardium** presented normal echogenicity without subjective evidence of significant fibrotic or ischemic disease. **Contractility** of the ventricular walls was adequate and in normal range for this patient evidenced by the fractional shortening measurement and subjective evaluation of the different regions of the myocardium. The **left ventricular outflow** tract demonstrated normal laminar flow and subjective structural integrity. The **right atrium** and auricle revealed normal size, structure and content. No evidence of masses was noted or chamber overload. **Tricuspid** insufficiency was noted. The **right ventricle** was of normal size (1/3 diameter of LV), chordae structure, myocardial echogenicity and thickness. **Pulmonic** tract assessment revealed normal valve structure, laminar flow, and diameter (approx. 1:1 pa/ao ratio). No visible **pericardial** or free pleura fluid was noted. No echographically detectable evidence of infiltrative disease was visible. The cranial **mediastinum and pericardial regions** were free of masses in the visible window.



PATIENT

Ravella Gaurino

SPECIES

Canine

BREED

Shiba Inu

SEX

Spayed female

AGE

14 years

WEIGHT

-

INTERPRETED BY

Eric Lindquist, DMV,
DABVP (CFM), Cert.
IVUSS, CEO of
SonoPath.com

IMAGING PERFORMED BY

Chloe Lowe/ Abd
Shari Reffi/Echo

HOSPITAL NAME

Midland Park VH

REFERRING VET

Dr. Shokoff

INVOICE

72089

DATE

3/2/26

CANINE CARDIAC PARAMETERS	MR VMAX (m/s)	TR VMAX (m/s)	LA/AO	LA/AO (Heart Base)	FS (%)	EF (%)	EPSS (cm)
NORMAL PARAMETER	4.5-5.5	<2.7	1.3	<1.6	28-40	40-100	<0.6
PATIENT	5.2	-	1.1	1.4	29	57	0.1
CANINE CARDIAC PARAMETERS	HR (BPM)	AV VMAX (m/s)	PV MAX (m/s)	BODY WEIGHT (kg)	LA 2D short axis Base view (cm)	LVIDd Avg; 2D and m-mode short axis (cm)	LVIDs Avg; 2D and m-mode short axis (cm)
NORMAL PARAMETER	50-100	0.7-1.7	0.7-1.6	BELOW	BELOW	BELOW	BELOW
PATIENT	139	1.4	0.9	-	3.47	3.12	

ULTRASONOGRAPHIC FINDINGS

Cholelithiasis, non-obstructive.

Micronodular hyperplasia splenic pattern.

Age related abdominal changes elsewhere.

Stage B1 valvular disease.

INTERPRETATION OF THE FINDINGS & FURTHER RECOMMENDATIONS

The cause of azotemia is unclear in this patient. If any weight loss is an issue, then FNA of the spleen is indicated. There was no evidence of visceral disease responsible for the clinical signs. Concern for back pain given the patient's history. Hydration status, urinalysis should be evaluated if not already performed.

The heart is stable without clinical disease. No overt contraindication for anesthesia of brief to moderate duration. I suggest Torbutrol premed, Propofol induction, Isoflo maintenance or similar protocol if anesthesia is desired. Blood pressure recommended if not already performed and target white coat negative systolic pressure of < 160 mmHg. If higher than this ACE-inhibitor is suggested to reach this level. Recheck echocardiogram is recommended in 6 months, earlier if murmur grade increases or clinical signs initiate.



PATIENT

Ravella Gaurino

SPECIES

Canine

BREED

Shiba Inu

SEX

Spayed female

AGE

14 years

WEIGHT

-

INTERPRETED BY

Eric Lindquist, DMV,
 DABVP (CFM), Cert.
 IVUSS, CEO of
 SonoPath.com

IMAGING PERFORMED BY

Chloe Lowe/ Abd
 Shari Reffi/Echo

HOSPITAL NAME

Midland Park VH

REFERRING VET

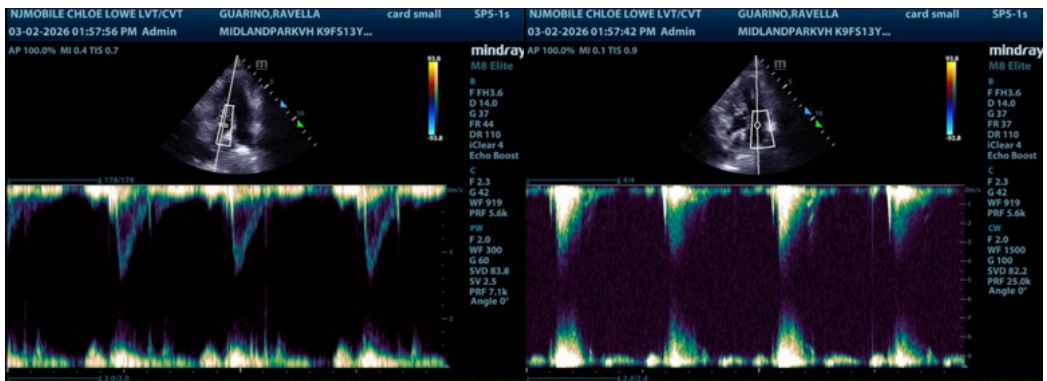
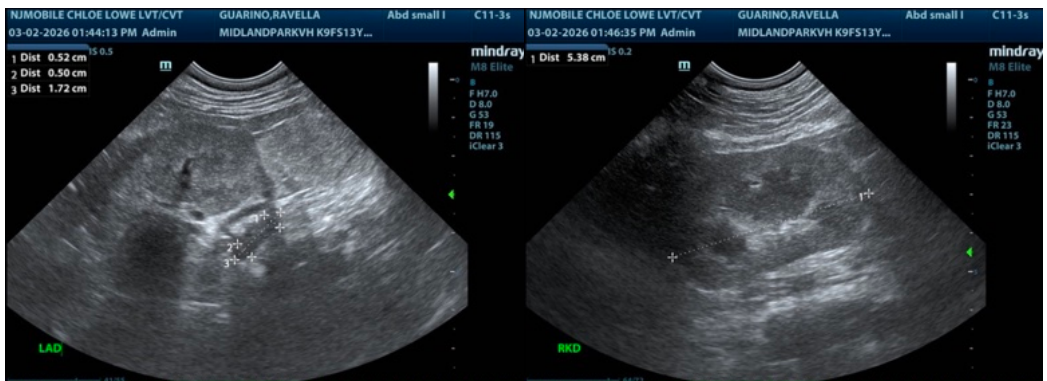
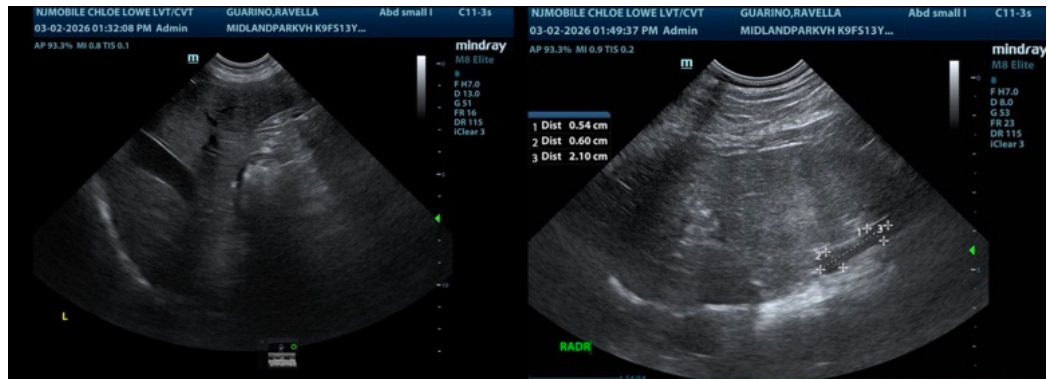
Dr. Shokoff

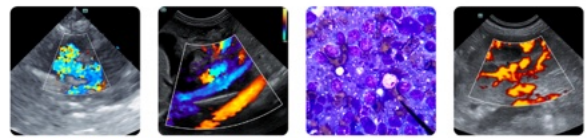
INVOICE

72089

DATE

3/2/26





PATIENT

Ravella Gaurino

SPECIES

Canine

BREED

Shiba Inu

SEX

Spayed female

AGE

14 years

WEIGHT

-

INTERPRETED BY

Eric Lindquist, DMV,
 DABVP (CFM), Cert.
 IVUSS, CEO of
 SonoPath.com

**IMAGING
 PERFORMED BY**

Chloe Lowe/ Abd
 Shari Reffi/Echo

HOSPITAL NAME

Midland Park VH

REFERRING VET

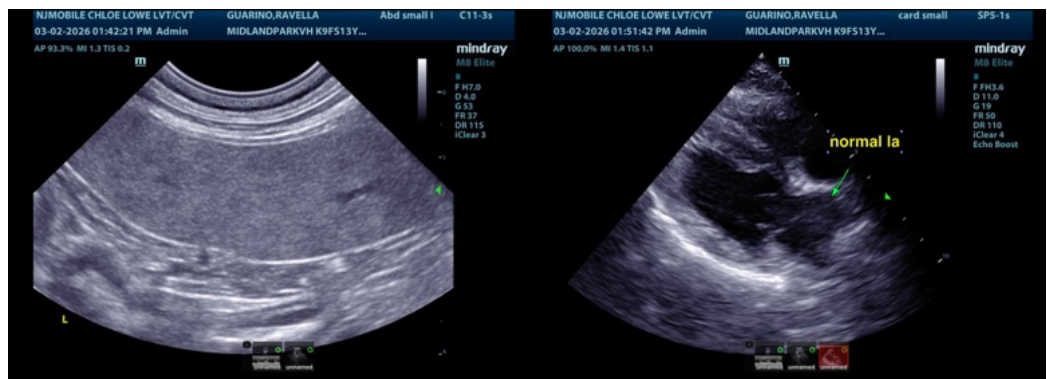
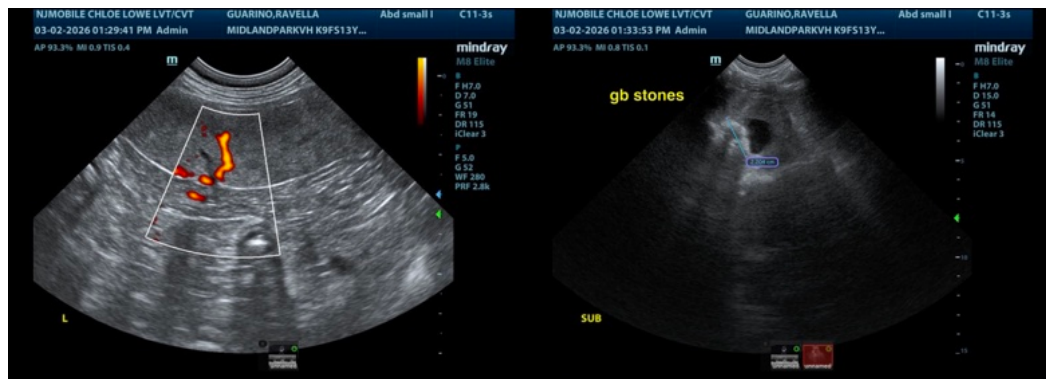
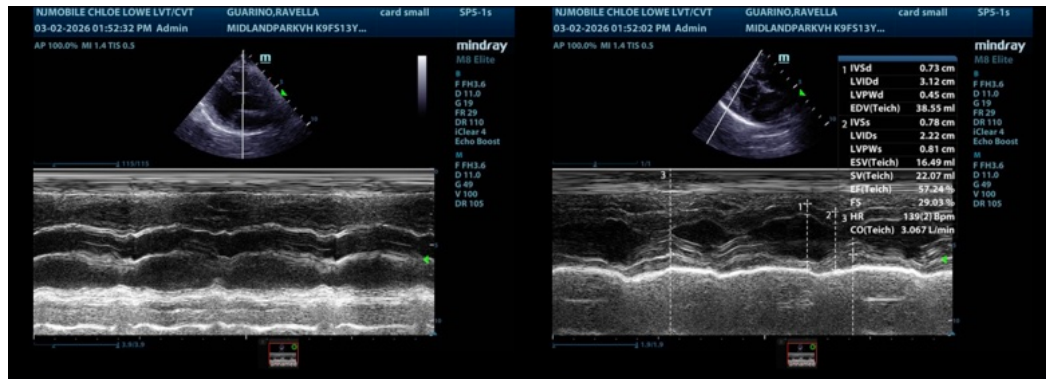
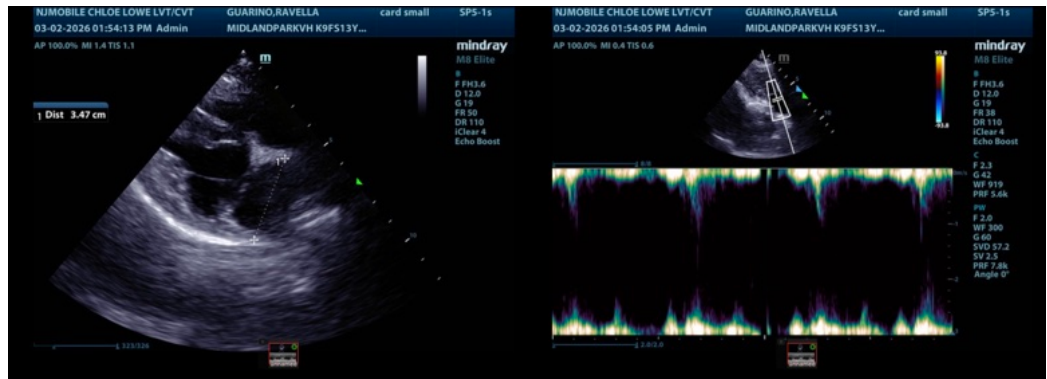
Dr. Shokoff

INVOICE

72089

DATE

3/2/26





PATIENT

Ravella Gaurino

SPECIES

Canine

BREED

Shiba Inu

SEX

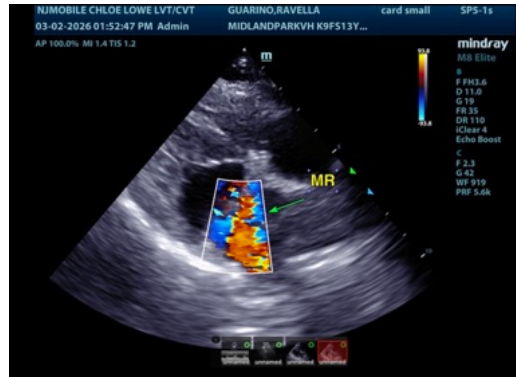
Spayed female

AGE

14 years

WEIGHT

-



The information and recommendations provided are based on the images presented by the referring veterinarian/sonographer. No evaluation can be communicated regarding pathology that was not visible in the image/video clips provided.

Thank you for this referral. If the clinical or image interpretation does not parallel your findings or if I can be of any further assistance please contact me.

Eric Lindquist, DMV, DABVP (CFM), Cert. IVUSS, CEO of SonoPath.com

Info@SonoPath.com

INTERPRETED BY

Eric Lindquist, DMV,
DABVP (CFM), Cert.
IVUSS, CEO of
SonoPath.com

IMAGING PERFORMED BY

Chloe Lowe/ Abd
Shari Reffi/Echo

HOSPITAL NAME

Midland Park VH

REFERRING VET

Dr. Shokoff

INVOICE

72089

DATE

3/2/26