



**PATIENT**

Cleo Pascale

**SPECIES**

Feline

**BREED**

Persian

**SEX**

Male

**AGE**

1 year

**WEIGHT**

-

**INTERPRETED BY**

Eric Lindquist, DMV  
 DABVP, Cert. IVUSS

**IMAGING PERFORMED BY**

Rebecca Hamilton

**HOSPITAL NAME**

Animal Clinic and  
 Hospital of Jersey City

**REFERRING VET**

-

**INVOICE**

72090

**DATE**

3/2/26

**PRESENTING CLINICAL SIGNS**

- Pre-ax check
- Whenever the pet plays to hard will start open mouth breathing and panting
- Abnormal PE/Chem/CBC/UA Results: none

**ULTRASONOGRAPHIC EXAMINATION OF THE HEART**

The echocardiogram in this patient demonstrated normal **left atrial** size based on 3 separate LA measurements. The cranial and caudal **mitral** valve leaflets presented normal linear structure and kinetics.. The **left ventricle** presented normal thicknesses with linear contour and was not dilated nor restricted. The **myocardium** presented normal echogenicity without subjective evidence of significant fibrotic or ischemic disease. **Contractility** of the ventricular walls was adequate and in normal range for this patient evidenced by the fractional shortening measurement and subjective evaluation of the different regions and angles of the myocardium. The **left ventricular outflow** tract demonstrated normal laminar flow and subjective structural integrity. The **right atrium** and auricle revealed normal size, structure and content. No evidence of masses was noted or chamber overload. Trivial **tricuspid** insufficiency was noted. The **right ventricle** was of normal size (1/3 diameter of LV), chordae structure, myocardial echogenicity and thickness. **Pulmonic** tract assessment revealed normal valve structure, laminar flow, and diameter (approx.1:1 pa/ao ratio). No visible **pericardial** or free pleura fluid was noted or extra cardiac pathology in the visible planes. The cranial **mediastinum and pericardial regions** were free of masses in the visible window.

**E Wave 0.9 m/sec**

FELINE CARDIAC PARAMETERS	BODY WEIGHT (kg)	HR (BPM)	IVSd (cm)	LVIDd (cm)	LVWd (cm)	FS (%)	EF (%)
NORMAL PARAMETER	-----	150-240	0.3-0.6	1.0-2.1	0.25-0.6	35-67	80-100
PATIENT	-	200	0.4	1.4	0.45	50	90
FELINE CARDIAC PARAMETERS	LA/AO (M-mode)	LA/AO HEART BASE (Sisson)	LAD LA MAX 4 Chamber		LVOT VEL. (m/s)	RVOT VEL. (m/s)	IVRT (m/)
NORMAL PARAMETER	<1.5	1.6	0.7-1.7		<1.6	<1.3	40-60
PATIENT	1.1	1.1	1.2		2.0	0.77	NM
Adapted from June Boon, Veterinary Echocardiography, 1998							
Sisson D et al. JVIM 1991; 5: 232, Jacobs et al. Am J Vet Res 1985; 46:1705							

**ULTRASONOGRAPHIC FINDINGS**

Normal echocardiogram.



**PATIENT**

Cleo Pascale

**SPECIES**

Feline

**BREED**

Persian

**SEX**

Male

**AGE**

1 year

**WEIGHT**

-

**INTERPRETED BY**

Eric Lindquist, DMV  
 DABVP, Cert. IVUSS

**IMAGING PERFORMED BY**

Rebecca Hamilton

**HOSPITAL NAME**

Animal Clinic and  
 Hospital of Jersey City

**REFERRING VET**

-

**INVOICE**

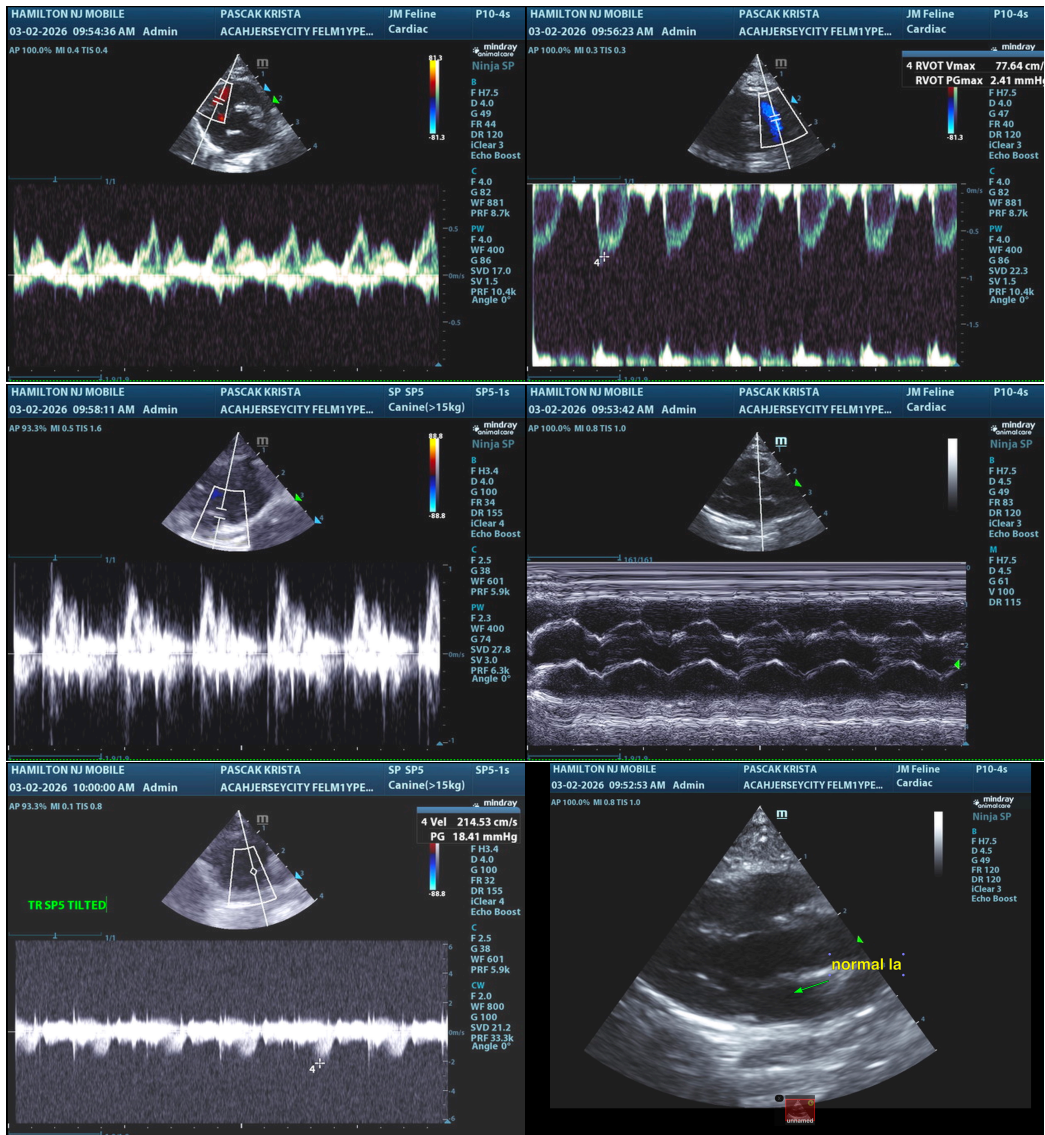
72090

**DATE**

3/2/26

**INTERPRETATION OF THE FINDINGS & FURTHER RECOMMENDATIONS**

There was no structural or functional evidence of pathology related to the clinical signs. Orthopedic pain, primary respiratory disease or paroxysmal arrhythmia are all possible, yet no arrhythmogenic activity was noted during the echocardiogram. Long lead 2 EKG is indicated to assess for any arrhythmogenic activity. There was no evidence of systolic anterior motion.





**PATIENT**

Cleo Pascale

**SPECIES**

Feline

**BREED**

Persian

**SEX**

Male

**AGE**

1 year

**WEIGHT**

-

**INTERPRETED BY**

Eric Lindquist, DMV  
 DABVP, Cert. IVUSS

**IMAGING PERFORMED BY**

Rebecca Hamilton

**HOSPITAL NAME**

Animal Clinic and  
 Hospital of Jersey City

**REFERRING VET**

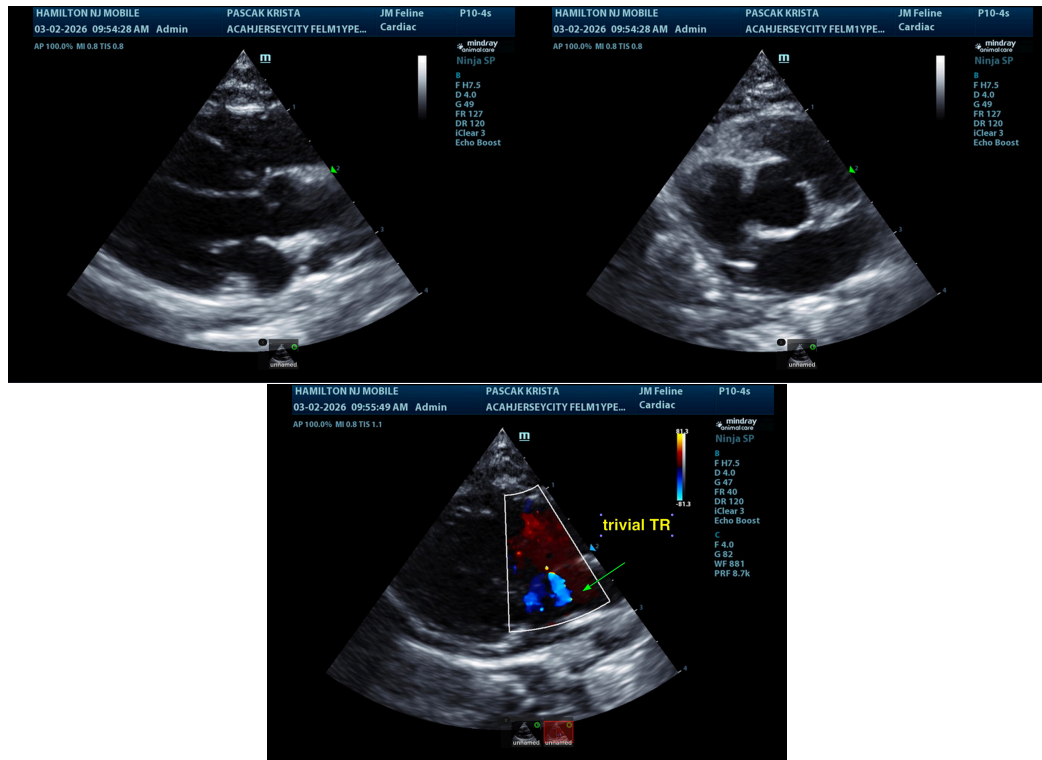
-

**INVOICE**

72090

**DATE**

3/2/26



The information and recommendations provided are based on the images presented by the referring veterinarian/sonographer. No evaluation can be communicated regarding pathology that was not visible in the image/video clips provided.

Thank you for this referral. If the clinical or image interpretation does not parallel your findings or if I can be of any further assistance please contact me.

**Eric Lindquist, DMV, DABVP, Cert. IVUSS, CEO of SonoPath.com**

[info@SonoPath.com](mailto:info@SonoPath.com)