



PATIENT

Maggie Palz

SPECIES

Canine

BREED

Shih Tzu Mix

SEX

Spayed female

AGE

9 years

WEIGHT

10.3 lbs

INTERPRETED BY

Eric Lindquist, DMV,
DABVP (CFM), Cert.
IVUSS, CEO of
SonoPath.com

IMAGING PERFORMED BY

Chloe Lowe

HOSPITAL NAME

Budd Lake AH

REFERRING VET

Dr. Welch

INVOICE

73624

DATE

3/19/26

PRESENTING CLINICAL SIGNS

- Exercise intolerance potentially noted at home. Heart murmur 4/6. A little tense abdomen. Overweight
- Lyme + and treated in December 2025 Alk Phos 145, AST 11 UA protein ++, USG 1.042

ULTRASONOGRAPHIC EXAMINATION OF THE ABDOMEN

Urinary System

The **urinary bladder**, trigone, and pelvic urethra presented normal thicknesses and normal tone. The ureters were not visible which is normal. No uroliths or sediment were visualized and anechoic urine was present. No evidence of inflammatory or neoplastic changes was noted. Ureteral papillae were normal.

The **kidneys** revealed largely normal size and structure, corticomedullary definition and ratio (cortex 1/3 of medulla) were essentially maintained with some age-related loss of curvilinear patterns regarding the capsule and C/M junction. The cortices presented largely uniform texture with some increased echogenicity expected for this age patient. Medullary structure differed distinctly from that of the cortex and no evidence of pelvic dilation was present. Hyperechoic medullary rim sign was noted. This is idiopathic and typical for the breed. . The left kidney measured 2.93 cm. The right kidney measured 3.27 cm.

Adrenal Glands

Both **adrenal glands** were visualized and recognized as having normal shape, size, position and echogenicity for this breed. The phrenic vasculature, glandular echogenicity and detail were unremarkable. Capsule, cortex, and medullary definition were normal for this age patient. The right adrenal gland measured 1.3 x 0.61 cm at the cranial pole and 0.41 cm at the caudal pole. The left adrenal gland measured 1.4 x 0.39 cm at the caudal pole and 0.42 cm at the cranial pole.

Spleen

The **spleen** presented a smooth homogeneous parenchyma hyperechoic to liver and renal cortical parenchyma. The capsule was smooth without noticeable expansion or deviation from within the spleen or adjacent pathology. The splenic vasculature demonstrated normal volume without signs of congestion or thrombosis. No sonographic evidence of acute or chronic inflammatory, neoplastic, or infarctual changes was noted.

Liver

The **liver** images from right and left intercostal as well as subcostal views revealed subjectively normal liver size, contour, and structure. Some age-related parenchymal remodeling was noted but likely not clinically significant at this time. Vascular and biliary tracts were of normal volume and no evidence of congestion was noted. The gallbladder presented some dependent debris with essentially normal contour. The cystic and common bile ducts were normal. No overt evidence of active inflammatory,



PATIENT

Maggie Palz

infiltrative or regenerative pathology was noted but should be paired with current or past LE elevations regarding any clinical significance to this presentation. The hepatic lymph nodes were unremarkable.

SPECIES

Canine

Gastrointestinal

Examination of the **gastrointestinal tract** revealed a stomach and intestine free of stasis, of normal wall thickness, acceptable curvilinear mural detail, and peristaltic activity. Small and large intestine demonstrated normal luminal chyme and stool consistency respectively. No obstructive or overt infiltrative disease was noted. No associated abnormal lymphatic activity was noted.

BREED

Shih Tzu Mix

SEX

Spayed female

Pancreas

The base and limbs of the **pancreas** were observed to be largely isoechoic to surrounding omental fat. Pancreatic duct and capsular contour were acceptably normal and parenchyma respected normal curvilinear patterns. No overt evidence of active inflammatory or neoplastic disease was noted.

AGE

9 years

WEIGHT

10.3 lbs

ULTRASONOGRAPHIC EXAMINATION OF THE HEART

The echocardiogram in this patient demonstrated normal **left atrial** size based on 3 different LA measurement methods. Chamber volumes and echogenicity were normal. The cranial and caudal **mitral** valve leaflets presented vegetative thickening consistent with endocardiosis. Prolapse of the anterior mitral valve leaflet was noted. Doppler indicated measurable insufficiency. The **left ventricle** presented thicknesses with linear contour and was not dilated nor restricted. The **myocardium** presented normal echogenicity without subjective evidence of significant fibrotic or ischemic disease. **Contractility** of the ventricular walls was adequate and in normal range for this patient evidenced by the fractional shortening measurement and subjective evaluation of the different regions of the myocardium. The **left ventricular outflow** tract demonstrated normal laminar flow and subjective structural integrity. The **right atrium** and auricle revealed normal size, structure and content. No evidence of masses was noted or chamber overload. **Tricuspid** valvular assessment demonstrated adequate linear morphology. The **right ventricle** was of normal size (1/3 diameter of LV), chordae structure, myocardial echogenicity and thickness. **Pulmonic** tract assessment revealed normal valve structure, laminar flow, and diameter (approx. 1:1 pa/ao ratio). No visible **pericardial** or free pleura fluid was noted. No echographically detectable evidence of infiltrative disease was visible. The cranial **mediastinum and pericardial regions** were free of masses in the visible window.

INTERPRETED BY

Eric Lindquist, DMV,
DABVP (CFM), Cert.
IVUSS, CEO of
SonoPath.com

IMAGING PERFORMED BY

Chloe Lowe

HOSPITAL NAME

Budd Lake AH

REFERRING VET

Dr. Welch

INVOICE

73624

DATE

3/19/26



PATIENT

Maggie Palz

SPECIES

Canine

BREED

Shih Tzu Mix

SEX

Spayed female

AGE

9 years

WEIGHT

10.3 lbs

INTERPRETED BY

Eric Lindquist, DMV,
 DABVP (CFM), Cert.
 IVUSS, CEO of
 SonoPath.com

IMAGING PERFORMED BY

Chloe Lowe

HOSPITAL NAME

Budd Lake AH

REFERRING VET

Dr. Welch

INVOICE

73624

DATE

3/19/26

CANINE CARDIAC PARAMETERS	MR VMAX (m/s)	TR VMAX (m/s)	LA/AO	LA/AO (Heart Base)	FS (%)	EF (%)	EPSS (cm)
NORMAL PARAMETER	4.5-5.5	<2.7	1.3	<1.6	28-40	40-100	<0.6
PATIENT	5.0		NM	1.38	37	69	0.1
CANINE CARDIAC PARAMETERS	HR (BPM)	AV VMAX (m/s)	PV MAX (m/s)	BODY WEIGHT	LA 2D short axis Base view (cm)	LVIDd Avg; 2D and m-mode short axis (cm)	LVIDs Avg; 2D and m-mode short axis (cm)
NORMAL PARAMETER	50-100	0.7-1.7	0.7-1.6	BELOW	BELOW	BELOW	BELOW
PATIENT	177		1.0	10.3 lbs	2.5 max	2.35	

ULTRASONOGRAPHIC FINDINGS

Idiopathic medullary rim kidney.

Stage B1 valvular disease with mitral valve prolapse. No significant volume overload.

INTERPRETATION OF THE FINDINGS & FURTHER RECOMMENDATIONS

Urinalysis is warranted if not already performed to assess any significant proteinuria or inflammatory sediment. Blood pressure measurements are indicated. I cannot rule out the potential of paroxysmal arrhythmia as the cause of the exercise intolerance. Holter monitor would be necessary. Other causes such as orthopedic pain or extracardiac thoracic disease should be considered as well as potential underlying hypertension.

The heart is stable without clinical disease. No overt contraindication for anesthesia of brief to moderate duration. I suggest Torbutrol premed, Propofol induction, Isoflo maintenance or similar protocol if anesthesia is desired. Blood pressure recommended if not already performed and target white coat negative systolic pressure of < 160 mmHg. If higher than this ACE-inhibitor is suggested to reach this level. Recheck echocardiogram is recommended in 6 months, earlier if murmur grade increases or clinical signs initiate.



PATIENT

Maggie Palz

SPECIES

Canine

BREED

Shih Tzu Mix

SEX

Spayed female

AGE

9 years

WEIGHT

10.3 lbs

INTERPRETED BY

Eric Lindquist, DMV,
 DABVP (CFM), Cert.
 IVUSS, CEO of
 SonoPath.com

**IMAGING
 PERFORMED BY**

Chloe Lowe

HOSPITAL NAME

Budd Lake AH

REFERRING VET

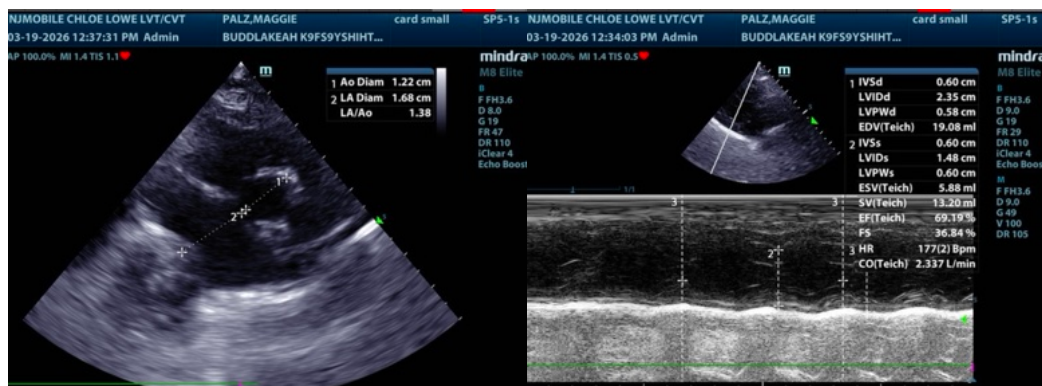
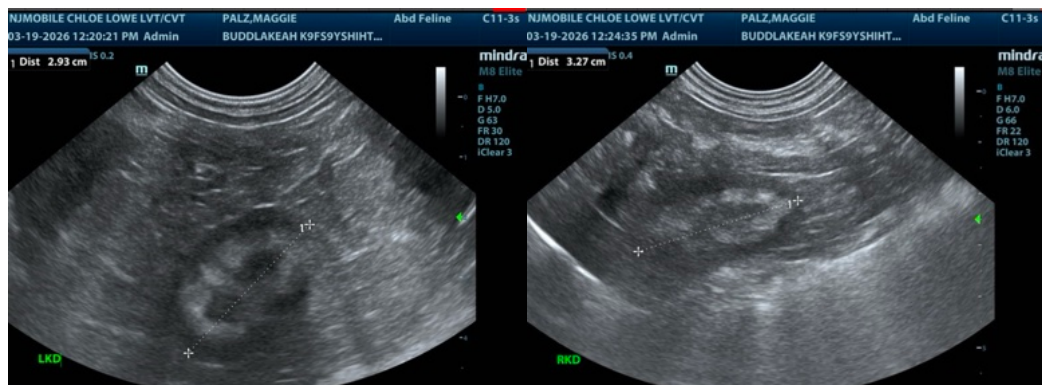
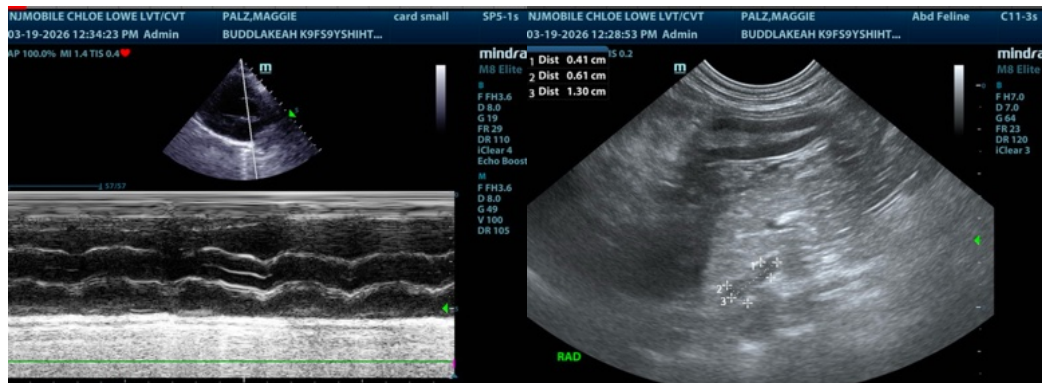
Dr. Welch

INVOICE

73624

DATE

3/19/26





PATIENT

Maggie Palz

SPECIES

Canine

BREED

Shih Tzu Mix

SEX

Spayed female

AGE

9 years

WEIGHT

10.3 lbs

INTERPRETED BY

Eric Lindquist, DMV,
 DABVP (CFM), Cert.
 IVUSS, CEO of
 SonoPath.com

**IMAGING
 PERFORMED BY**

Chloe Lowe

HOSPITAL NAME

Budd Lake AH

REFERRING VET

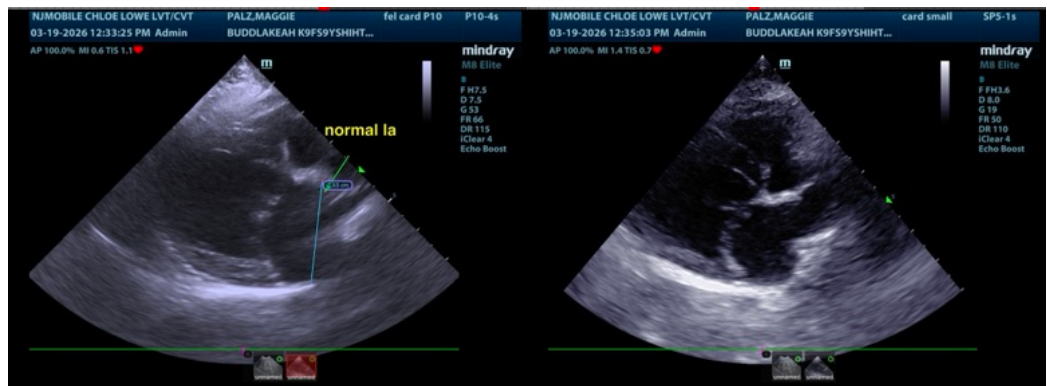
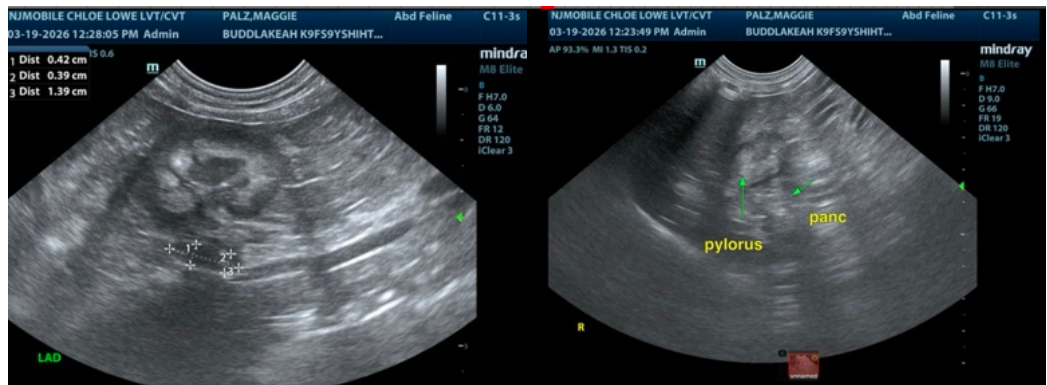
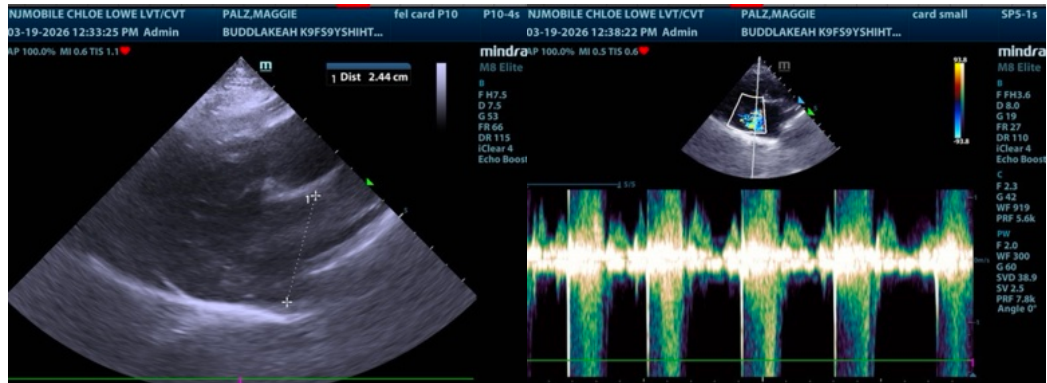
Dr. Welch

INVOICE

73624

DATE

3/19/26





PATIENT

Maggie Palz

SPECIES

Canine

BREED

Shih Tzu Mix

SEX

Spayed female

AGE

9 years

WEIGHT

10.3 lbs

INTERPRETED BY

Eric Lindquist, DMV,
DABVP (CFM), Cert.
IVUSS, CEO of
SonoPath.com

**IMAGING
PERFORMED BY**

Chloe Lowe

HOSPITAL NAME

Budd Lake AH

REFERRING VET

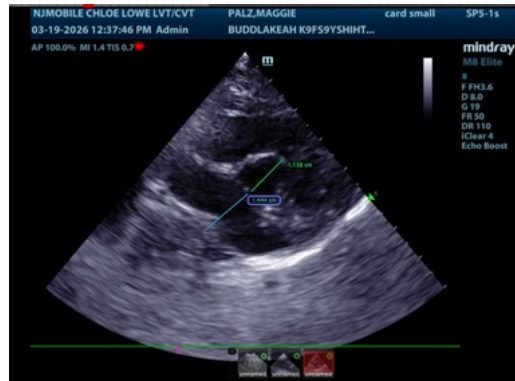
Dr. Welch

INVOICE

73624

DATE

3/19/26



The information and recommendations provided are based on the images presented by the referring veterinarian/sonographer. No evaluation can be communicated regarding pathology that was not visible in the image/video clips provided.

Thank you for this referral. If the clinical or image interpretation does not parallel your findings or if I can be of any further assistance please contact me.

Eric Lindquist, DMV, DABVP (CFM), Cert. IVUSS, CEO of SonoPath.com

Info@SonoPath.com