



PATIENT

Cleo Marcus

SPECIES

Feline

BREED

Domestic Longhair

SEX

Spayed female

AGE

10 years

WEIGHT

10 lbs

INTERPRETED BY

Eric Lindquist, DMV,
DABVP (CFM), Cert.
IVUSS, CEO of
SonoPath.com

IMAGING PERFORMED BY

Chloe Lowe

HOSPITAL NAME

Hackettstown AH

REFERRING VET

Dr. Long

INVOICE

73625

DATE

3/19/26

PRESENTING CLINICAL SIGNS

- Weight loss of unknown origin, lost 5 pounds since 2021 (though BCS 5/9). General malaise. Pain on right hip extension. Moderate dental disease.
- Artifact of thrombocytopenia (sampling artifact), platelets 58 k/uL, scan RBC concentration (HCT 50%) Chemistries including T4 WNL UA 2+ protein, euc 0.1, 4-10 structural USG 1.062

ULTRASONOGRAPHIC EXAMINATION OF THE ABDOMEN

Urinary System

The **urinary bladder**, trigone, and pelvic urethra presented normal thicknesses and normal tone. The ureters were not visible which is normal. No uroliths or sediment were visualized and anechoic urine was present. No evidence of inflammatory or neoplastic changes was noted. Ureteral papillae were normal.

The **kidneys** revealed normal size and structure, corticomedullary definition and ratio for this age. The cortices presented largely uniform texture with normal echogenic relationship to liver and spleen. Medullary structure differed distinctly from the cortex and no evidence of pelvic dilation was present. The capsules were acceptably uniform without significant irregularities. The left kidney measured 3.62 cm and the right kidney measured 4.16 cm.

Adrenal Glands

Both **adrenal glands** were visualized and recognized as having normal shape, size, position and echogenicity for this breed. The phrenic vasculature, glandular echogenicity and detail were unremarkable. Capsule, cortex, and medullary definition were normal for this age patient. The left adrenal gland measured 0.42 cm. The right adrenal gland measured 0.35 cm.

Spleen

The **spleen** presented a smooth homogeneous parenchyma hyperechoic to liver and renal cortical parenchyma. The capsule was smooth without noticeable expansion or deviation from within the spleen or adjacent pathology. The splenic vasculature demonstrated normal volume without signs of congestion or thrombosis. No sonographic evidence of acute or chronic inflammatory, neoplastic, or infarctual changes was noted.

Liver

The **liver** images submitted revealed subjectively normal liver size, contour, and structure. Parenchymal echogenicity was naturally coarse and hypoechoic to the spleen. Vascular and biliary tracts were of normal volume with no evidence of congestion. The gallbladder presented acceptably thin walls with primarily anechoic content. The cystic and common bile ducts were normal. No pathological hepatic lymphadenopathy was evident. No overt structural evidence of inflammatory, infiltrative or regenerative pathology was evident.



PATIENT

Cleo Marcus

SPECIES

Feline

BREED

Domestic Longhair

SEX

Spayed female

AGE

10 years

WEIGHT

10 lbs

INTERPRETED BY

Eric Lindquist, DMV,
DABVP (CFM), Cert.
IVUSS, CEO of
SonoPath.com

IMAGING PERFORMED BY

Chloe Lowe

HOSPITAL NAME

Hackettstown AH

REFERRING VET

Dr. Long

INVOICE

73625

DATE

3/19/26

Gastrointestinal

Minor fluid filled **gastric** lumen was noted without loos mural detail. Mild uniform prominence of the gastric mucosa was noted as well as areas of "ropey" small intestinal wall with slight disruption of the normal 1:3 muscularis/mucosal ratio. The intestinal submucosa was slightly irregular, thickened and hyperechoic suggestive of low grade, chronic disease. No concerning lymphadenopathy was visible. No evidence of obstruction was present. Chronic inflammatory bowel disease is likely with a low possibility of an early neoplastic event such as lymphoma. Full thickness tissue biopsies via open laparotomy, ideally guided by intraoperative ultrasound in order to obtain the most representative mural sample, would be necessary to rule out this possibility.

Pancreas

The base and limbs of the **pancreas** were observed to be largely isoechoic to surrounding omental fat. Some parenchymal remodeling, however, with mild deviation from curvilinear normalcy was observed. Pancreatic duct and capsular irregularities were present consistent with age related changes. If pain upon imaging (+ Murphy sign) was present or if the patient is focally painful in subxiphoid palpation then low-grade smoldering chronic pancreatitis should be suspected.

ULTRASONOGRAPHIC FINDINGS

Mild, chronic intestinal thickening.

Slightly prominent pancreas.

INTERPRETATION OF THE FINDINGS & FURTHER RECOMMENDATIONS

There was no overt neoplastic criteria present. However, full thickness intestinal biopsies would be ideal for further definition from a surgical perspective. Inflammatory bowel is likely. Occult FIP or emerging round cell neoplasia is always possible with this type of presentation.

Maldigestion panel, three view chest radiographs and full CNS examination is recommended to examine for occult disease that could be responsible for the weight loss. Evaluation for competitive eating environments should also be considered.



PATIENT

Cleo Marcus

SPECIES

Feline

BREED

Domestic Longhair

SEX

Spayed female

AGE

10 years

WEIGHT

10 lbs

INTERPRETED BY

Eric Lindquist, DMV,
 DABVP (CFM), Cert.
 IVUSS, CEO of
 SonoPath.com

**IMAGING
 PERFORMED BY**

Chloe Lowe

HOSPITAL NAME

Hackettstown AH

REFERRING VET

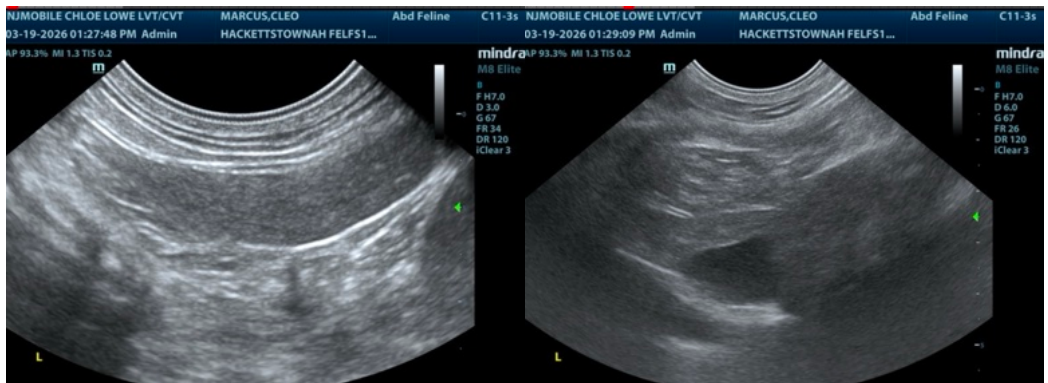
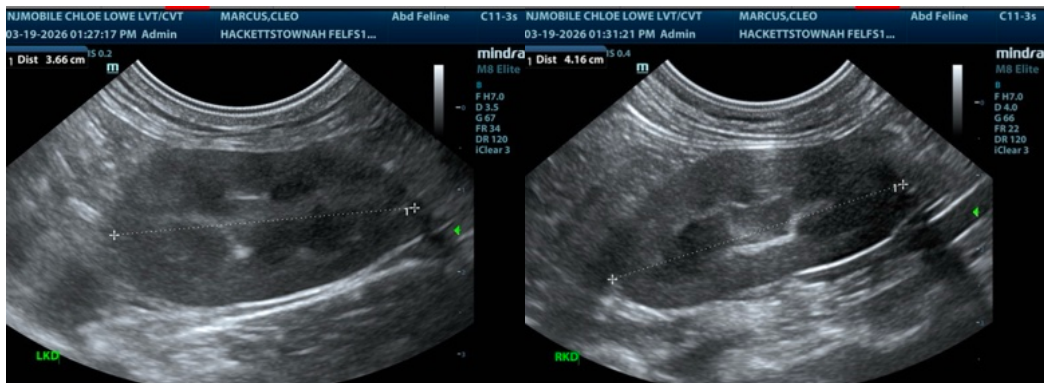
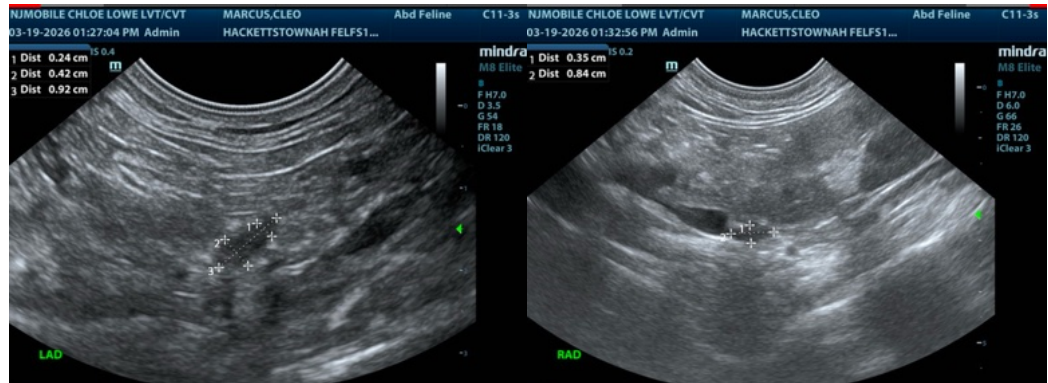
Dr. Long

INVOICE

73625

DATE

3/19/26





PATIENT

Cleo Marcus

SPECIES

Feline

BREED

Domestic Longhair

SEX

Spayed female

AGE

10 years

WEIGHT

10 lbs

INTERPRETED BY

Eric Lindquist, DMV,
DABVP (CFM), Cert. IVUSS, CEO of SonoPath.com

IMAGING PERFORMED BY

Chloe Lowe

HOSPITAL NAME

Hackettstown AH

REFERRING VET

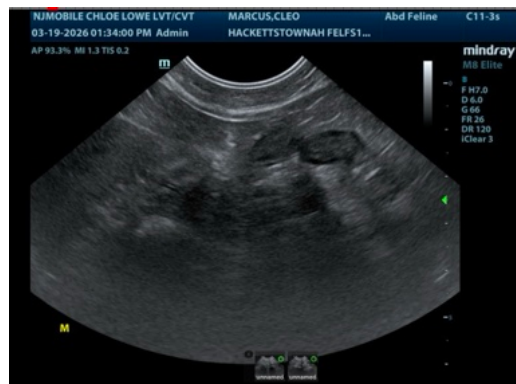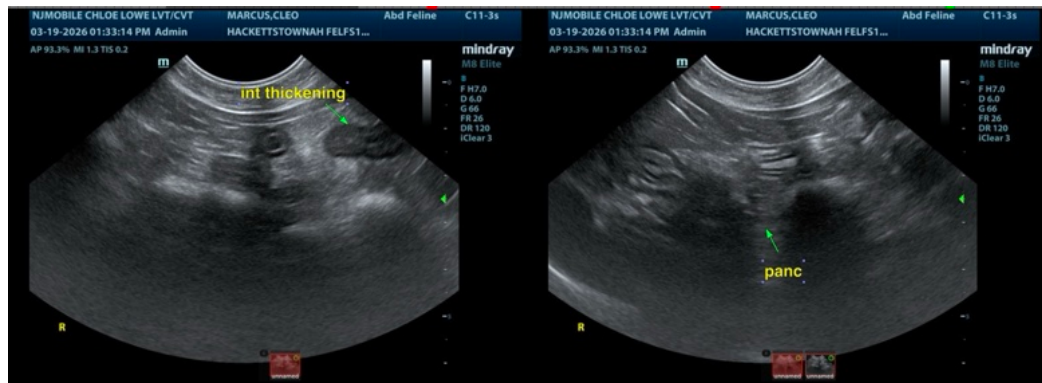
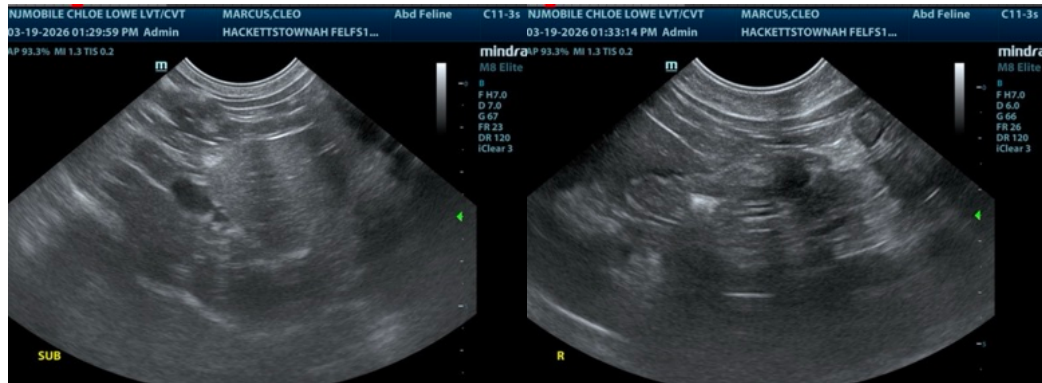
Dr. Long

INVOICE

73625

DATE

3/19/26



The information and recommendations provided are based on the images presented by the referring veterinarian/sonographer. No evaluation can be communicated regarding pathology that was not visible in the image/video clips provided.

Thank you for this referral. If the clinical or image interpretation does not parallel your findings or if I can be of any further assistance please contact me.

Eric Lindquist, DMV, DABVP (CFM), Cert. IVUSS, CEO of SonoPath.com

Info@SonoPath.com