

**PATIENT**

Tucker Mazakewski

**SPECIES**

Canine

**BREED**

Mix

**SEX**

Neutered male

**AGE**

2 years

**WEIGHT**

81 lbs

**PRESENTING CLINICAL SIGNS**

Grade II/VI heart murmur. Mast cell tumors

**ULTRASONOGRAPHIC EXAMINATION OF THE HEART**

The echocardiogram in this patient demonstrated normal **left atrial** size based on 3 different LA measurement methods. Chamber volumes and echogenicity were normal. Centralized mild **mitral** valve insufficiency was noted. The **left ventricle** presented thicknesses with linear contour and was not dilated nor restricted. The **myocardium** presented normal echogenicity without subjective evidence of significant fibrotic or ischemic disease. **Contractility** of the ventricular walls was adequate and in normal range for this patient evidenced by the fractional shortening measurement and subjective evaluation of the different regions of the myocardium. The **left ventricular outflow** tract demonstrated normal laminar flow and subjective structural integrity. The **right atrium** and auricle revealed normal size, structure and content. No evidence of masses was noted or chamber overload. **Tricuspid** valvular assessment demonstrated adequate linear morphology. The **right ventricle** was of normal size (1/3 diameter of LV), chordae structure, myocardial echogenicity and thickness. **Pulmonic** tract assessment revealed normal valve structure, laminar flow, and diameter (approx. 1:1 pa/ao ratio). No visible **pericardial** or free pleura fluid was noted. No echographically detectable evidence of infiltrative disease was visible. The cranial **mediastinum and pericardial regions** were free of masses in the visible window.

**INTERPRETED BY**

Eric Lindquist, DMV,  
DABVP, Cert. IVUSS,  
CEO of SonoPath.com

**IMAGING PERFORMED BY**

Eric Lindquist, DMV,  
DABVP, Cert. IVUSS,  
CEO of SonoPath.com

**HOSPITAL NAME**

Greenwood Lake AH

**REFERRING VET**

Dr. Louer

**INVOICE**

73539

**DATE**

3/17/26

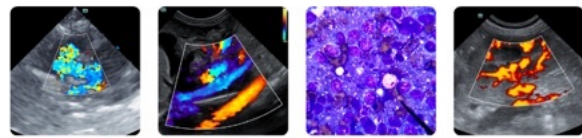
<b>CANINE CARDIAC PARAMETERS</b>	<b>MR VMAX (m/s)</b>	<b>TR VMAX (m/s)</b>	<b>LA/AO</b>	<b>LA/AO (Heart Base)</b>	<b>FS (%)</b>	<b>EF (%)</b>	<b>EPSS (cm)</b>
<b>NORMAL PARAMETER</b>	4.5-5.5	<2.7	1.3	<1.6	28-40	40-100	<0.6
<b>PATIENT</b>	-	-	1.0	1.3	46	77	0.1
<b>CANINE CARDIAC PARAMETERS</b>	<b>HR (BPM)</b>	<b>AV VMAX (m/s)</b>	<b>PV MAX (m/s)</b>	<b>BODY WEIGHT</b>	<b>LA 2D short axis Base view (cm)</b>	<b>LVIDd Avg; 2D and m-mode short axis (cm)</b>	<b>LVIDs Avg; 2D and m-mode short axis (cm)</b>
<b>NORMAL PARAMETER</b>	50-100	0.7-1.7	0.7-1.6	BELOW	BELOW	BELOW	BELOW
<b>PATIENT</b>	129	1.4	1.2	81 lbs	3.8	4.39	

**ULTRASONOGRAPHIC FINDINGS**

- Stage B1 valvular disease.

**INTERPRETATION OF THE FINDINGS & FURTHER RECOMMENDATIONS**

There is no contraindication to anesthetic procedure.



**PATIENT**

Tucker Mazakewski

**SPECIES**

Canine

**BREED**

Mix

**SEX**

Neutered male

**AGE**

2 years

**WEIGHT**

81 lbs

**INTERPRETED BY**

Eric Lindquist, DMV,  
 DABVP, Cert. IVUSS,  
 CEO of SonoPath.com

**IMAGING PERFORMED BY**

Eric Lindquist, DMV,  
 DABVP, Cert. IVUSS,  
 CEO of SonoPath.com

**HOSPITAL NAME**

Greenwood Lake AH

**REFERRING VET**

Dr. Louer

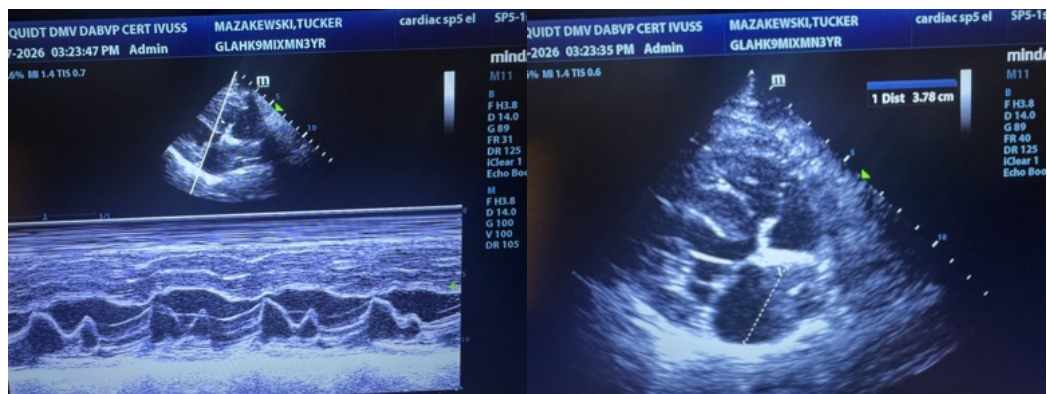
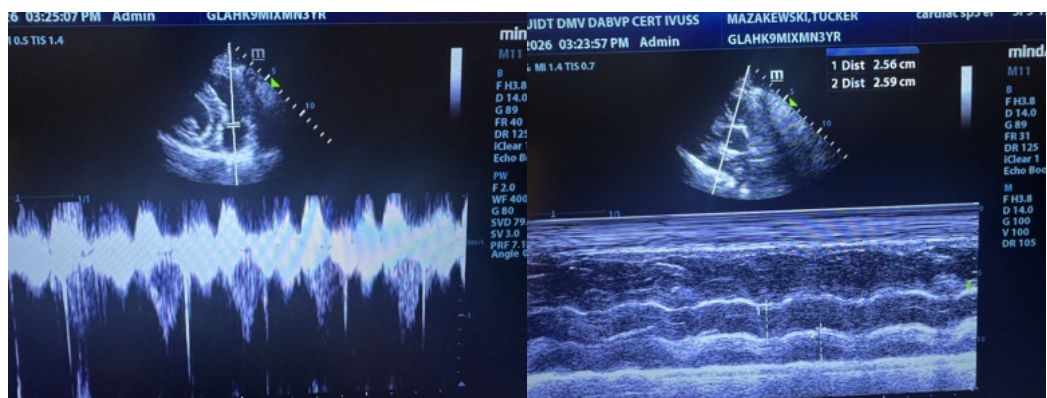
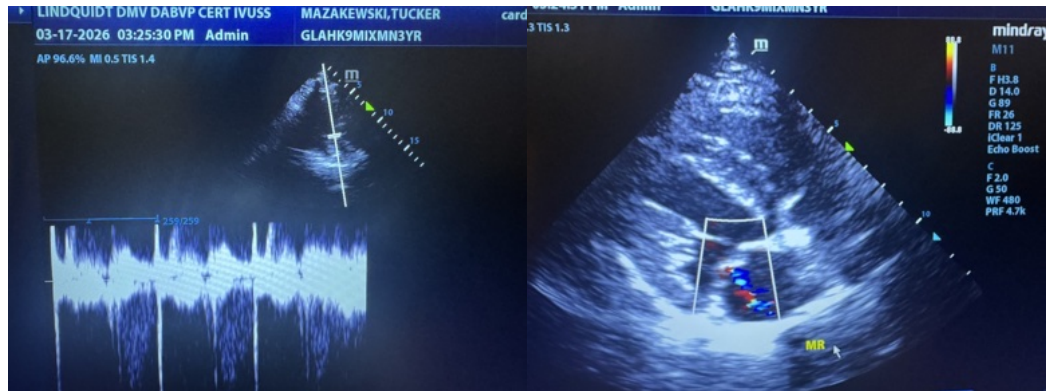
**INVOICE**

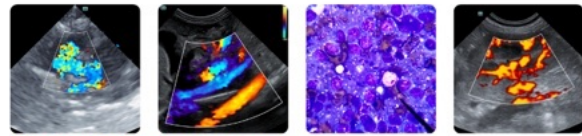
73539

**DATE**

3/17/26

The heart is stable without clinical disease. No overt contraindication for anesthesia of brief to moderate duration. I suggest Torbutrol premed, Propofol induction, Isoflo maintenance or similar protocol if anesthesia is desired. Blood pressure recommended if not already performed and target white coat negative systolic pressure of < 160 mmHg. If higher than this ACE-inhibitor is suggested to reach this level. Recheck echocardiogram is recommended in 6 months, earlier if murmur grade increases or clinical signs initiate.





**PATIENT**

Tucker Mazakewski

**SPECIES**

Canine

**BREED**

Mix

**SEX**

Neutered male

**AGE**

2 years

**WEIGHT**

81 lbs

**INTERPRETED BY**

Eric Lindquist, DMV,  
 DABVP, Cert. IVUSS,  
 CEO of SonoPath.com

**IMAGING PERFORMED BY**

Eric Lindquist, DMV,  
 DABVP, Cert. IVUSS,  
 CEO of SonoPath.com

**HOSPITAL NAME**

Greenwood Lake AH

**REFERRING VET**

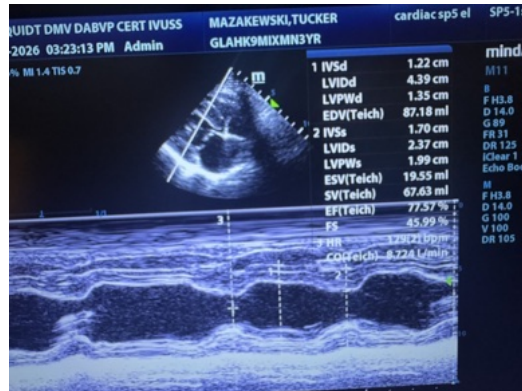
Dr. Louer

**INVOICE**

73539

**DATE**

3/17/26



The information and recommendations provided are based on the images presented by the referring veterinarian/sonographer. No evaluation can be communicated regarding pathology that was not visible in the image/video clips provided.

Thank you for this referral. If the clinical or image interpretation does not parallel your findings or if I can be of any further assistance please contact me.

Eric Lindquist, DMV, DABVP, Cert. IVUSS, CEO of SonoPath.com

Info@SonoPath.com