



PATIENT

Lucky Park

SPECIES

Canine

BREED

Pomeranian

SEX

Neutered male

AGE

10 years

WEIGHT

16.5 lbs

INTERPRETED BY

Eric Lindquist, DMV,
 DABVP (CFM), Cert.
 IVUSS, CEO of
 SonoPath.com

IMAGING PERFORMED BY

Kerri Becker

HOSPITAL NAME

Animal Paradise
 Hospital

REFERRING VET

Dr. ElShafie

INVOICE

73397

DATE

3/11/26

PRESENTING CLINICAL SIGNS

- HX of CHF, assess liver, 4/6 murmur
- BUN-27 cre-1.5 K-3.6 phos-2.7 alp-661 alb-4.6 mon-1.89

ULTRASONOGRAPHIC EXAMINATION OF THE HEART

The echocardiogram in this patient demonstrated enlarged **left atrial** size based on 3 different LA measurement methods. Chamber volumes and echogenicity were normal. The cranial and caudal **mitral** valve leaflets presented vegetative thickening consistent with endocardiosis. Doppler indicated measurable insufficiency. The **left ventricle** presented normal thicknesses with linear contour and was not dilated nor restricted. The **myocardium** presented normal echogenicity without subjective evidence of significant fibrotic or ischemic disease. **Contractility** of the ventricular walls was adequate and in normal range for this patient evidenced by the fractional shortening measurement and subjective evaluation of the different regions of the myocardium. The **left ventricular outflow** tract demonstrated normal laminar flow and subjective structural integrity. The **right atrium** and auricle revealed normal size, structure and content. No evidence of masses was noted or chamber overload. **Tricuspid** valvular assessment demonstrated adequate linear morphology. The **right ventricle** was of normal size (1/3 diameter of LV), chordae structure, myocardial echogenicity and thickness. **Pulmonic** tract assessment revealed normal valve structure, laminar flow, and diameter (approx.1:1 pa/ao ratio). No visible **pericardial** or free pleura fluid was noted. No echographically detectable evidence of infiltrative disease was visible. The cranial **mediastinum and pericardial regions** were free of masses in the visible window.

CANINE CARDIAC PARAMETERS	MR VMAX (m/s)	TR VMAX (m/s)	LA/AO	LA/AO (Heart Base)	FS (%)	EF (%)	EPSS (cm)
NORMAL PARAMETER	4.5-5.5	<2.7	1.3	<1.6	28-40	40-100	<0.6
PATIENT	6.0	1.0	1.5	2.0	40	72	0.1
CANINE CARDIAC PARAMETERS	HR (BPM)	AV VMAX (m/s)	PV MAX (m/s)	BODY WEIGHT	LA 2D short axis Base view (cm)	LVIDd Avg; 2D and m-mode short axis (cm)	LVIDs Avg; 2D and m-mode short axis (cm)
NORMAL PARAMETER	50-100	0.7-1.7	0.7-1.6	BELOW	BELOW	BELOW	BELOW
PATIENT	167	1.9	1.0	16.5 lbs	3.42	3.62	



PATIENT

Lucky Park

SPECIES

Canine

BREED

Pomeranian

SEX

Neutered male

AGE

10 years

WEIGHT

16.5 lbs

INTERPRETED BY

Eric Lindquist, DMV,
DABVP (CFM), Cert.
IVUSS, CEO of
SonoPath.com

IMAGING PERFORMED BY

Kerri Becker

HOSPITAL NAME

Animal Paradise
Hospital

REFERRING VET

Dr. ElShafie

INVOICE

73397

DATE

3/11/26

ULTRASONOGRAPHIC EXAMINATION OF THE ABDOMEN

Urinary System

The **urinary bladder**, trigone, and pelvic urethra presented normal thicknesses and normal tone. The ureters were not visible which is normal. No uroliths or sediment were visualized and anechoic urine was present. No evidence of inflammatory or neoplastic changes was noted. Ureteral papillae were normal.

The **kidneys** revealed largely normal size and structure, corticomedullary definition and ratio (cortex 1/3 of medulla) were essentially maintained with some age-related loss of curvilinear patterns regarding the capsule and C/M junction. The cortices presented largely uniform texture with some increased echogenicity expected for this age patient. Medullary structure differed distinctly from that of the cortex and no evidence of pelvic dilation was present. The right kidney measured 4.72 cm with corticomedullary mineralization. The left kidney measured 4.4 cm.

The residual prostate measured 0.5 cm.

Adrenal Glands

Both **adrenal glands** were visualized and recognized as having largely normal shape, size, position and acceptable echogenicity for this age group and breed. Some heterogeneity was noted within the adrenal parenchyma without concerning capsular distortion. These changes are likely age related but should be monitored by sonogram should the patient be suspected of having adrenal disease. The right adrenal gland measured 1.76 x 1.06 cm at the cranial pole and 0.63 cm at the caudal pole. The left adrenal gland measured 2.27 x 0.61 cm at the cranial pole and 0.59 cm at the caudal pole.

Spleen

The **spleen** revealed a focal, hypoechoic nodule in the mid body that measured 0.67 cm.

Liver

The **liver** images submitted revealed subjectively normal liver size, contour, and structure. Parenchymal echogenicity was naturally coarse and hypoechoic to the spleen. Vascular and biliary tracts were of normal volume with no evidence of congestion. The gallbladder presented acceptably thin walls with primarily anechoic content. The cystic and common bile ducts were normal. No pathological hepatic lymphadenopathy was evident. No overt structural evidence of inflammatory, infiltrative or regenerative pathology was evident.

Gastrointestinal

Examination of the **gastrointestinal tract** revealed a stomach and intestine free of stasis, of normal wall thickness, acceptable curvilinear mural detail, and peristaltic activity. Small and large intestine demonstrated normal luminal chyme and stool consistency respectively. No obstructive or overt infiltrative disease was noted. No associated abnormal lymphatic activity was noted.



PATIENT

Lucky Park

Pancreas

SPECIES

Canine

The base and limbs of the **pancreas** were observed to be largely isoechoic to surrounding omental fat. Pancreatic duct and capsular contour were acceptably normal and parenchyma respected normal curvilinear patterns. No overt evidence of active inflammatory or neoplastic disease was noted.

BREED

Pomeranian

ULTRASONOGRAPHIC FINDINGS

Mitral insufficiency, moderate to severe with mild left atrial enlargement.

SEX

Stage B2 valvular disease.

Neutered male

Focal splenic nodule.

AGE

Age related abdominal changes otherwise.

10 years

WEIGHT

16.5 lbs

INTERPRETATION OF THE FINDINGS & FURTHER RECOMMENDATIONS

Pimobendan is indicated at 0.3 mg/kg b.i.d. Underlying hypertension should be ruled out.

INTERPRETED BY

Eric Lindquist, DMV,
DABVP (CFM), Cert.
IVUSS, CEO of
SonoPath.com

Geriatric diet, serial blood pressure measurements and medical management for stage B2 valvular disease are all indicated. A recheck sonogram of the splenic nodule is recommended in a month to assess for any progression. Nodular hyperplasia is likely and emerging neoplasia is possible. Emerging hemangiosarcoma is possible, yet subjectively appears benign.

IMAGING PERFORMED BY

Kerri Becker

The heart has minor volume overload and is working to compensate for the valvular insufficiency. Target respiratory rate is < 20 resp/minute after therapy. After initiating or adjusting therapy, I recommend recheck on the clinical exam, BUN, Creatinine, USG, Chest radiographs & Blood pressure in 5-7 days. Recheck echo in 3-6 months, earlier if clinical decompensation is occurring. Minor anesthetic risk for a brief procedure at this time. Repeat preanesthetic echo is ideal if anesthesia is eventually necessary. A suggested anesthetic combination would involve Torbutrol premed, propofol induction, Isoflurane maintenance or equivalent protocol.

HOSPITAL NAME

Animal Paradise
Hospital

REFERRING VET

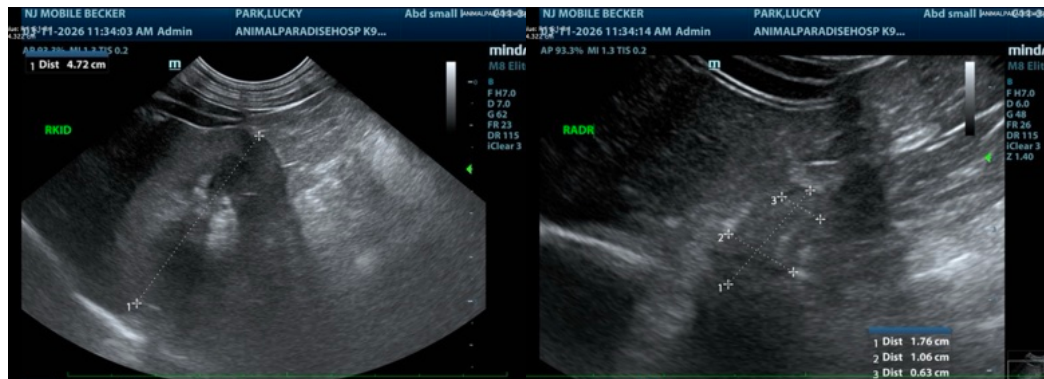
Dr. ElShafie

INVOICE

73397

DATE

3/11/26





PATIENT

Lucky Park

SPECIES

Canine

BREED

Pomeranian

SEX

Neutered male

AGE

10 years

WEIGHT

16.5 lbs

INTERPRETED BY

Eric Lindquist, DMV,
 DABVP (CFM), Cert.
 IVUSS, CEO of
 SonoPath.com

**IMAGING
 PERFORMED BY**

Kerri Becker

HOSPITAL NAME

Animal Paradise
 Hospital

REFERRING VET

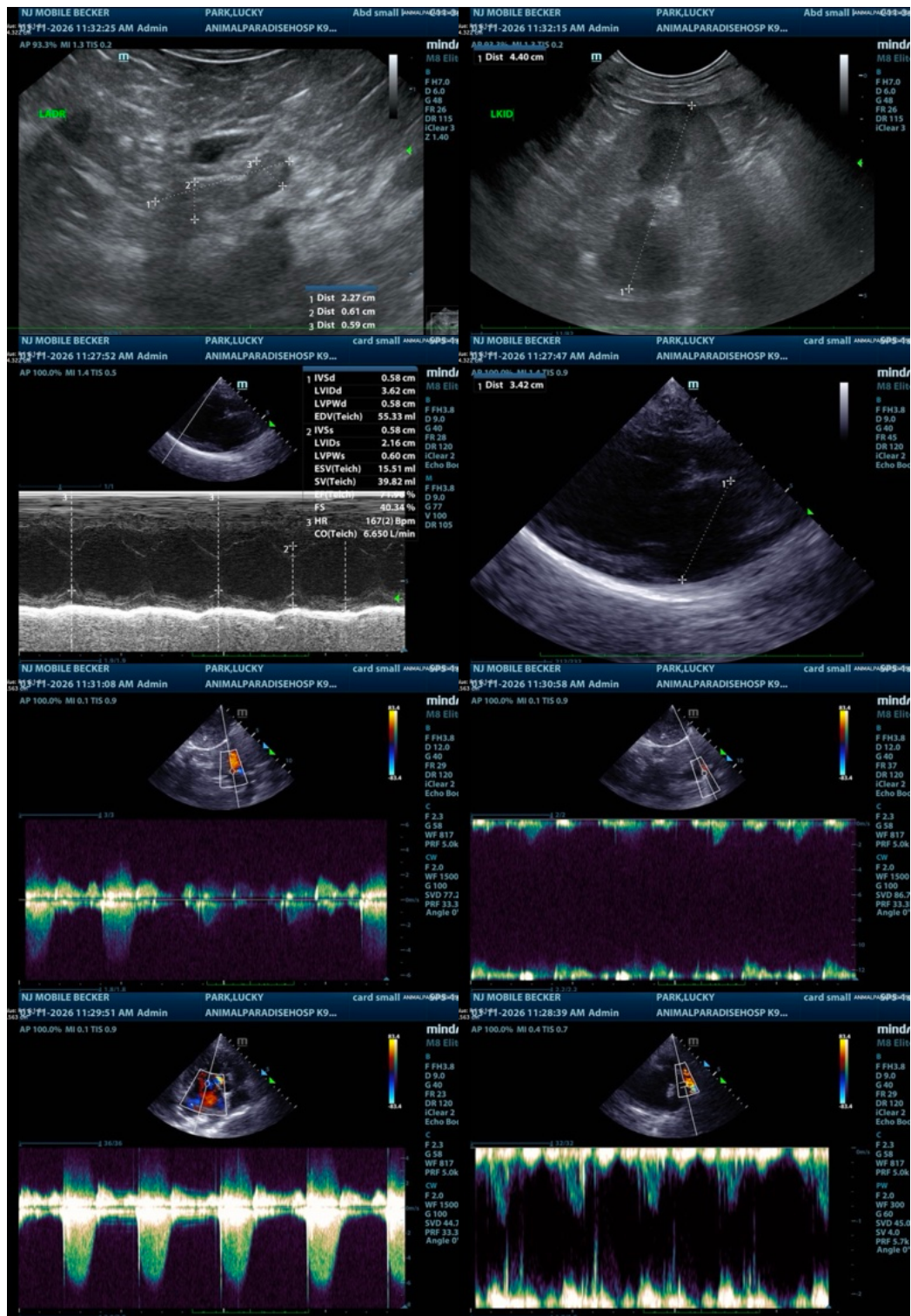
Dr. ElShafie

INVOICE

73397

DATE

3/11/26





PATIENT

Lucky Park

SPECIES

Canine

BREED

Pomeranian

SEX

Neutered male

AGE

10 years

WEIGHT

16.5 lbs

INTERPRETED BY

Eric Lindquist, DMV,
 DABVP (CFM), Cert.
 IVUSS, CEO of
 SonoPath.com

IMAGING PERFORMED BY

Kerri Becker

HOSPITAL NAME

Animal Paradise
 Hospital

REFERRING VET

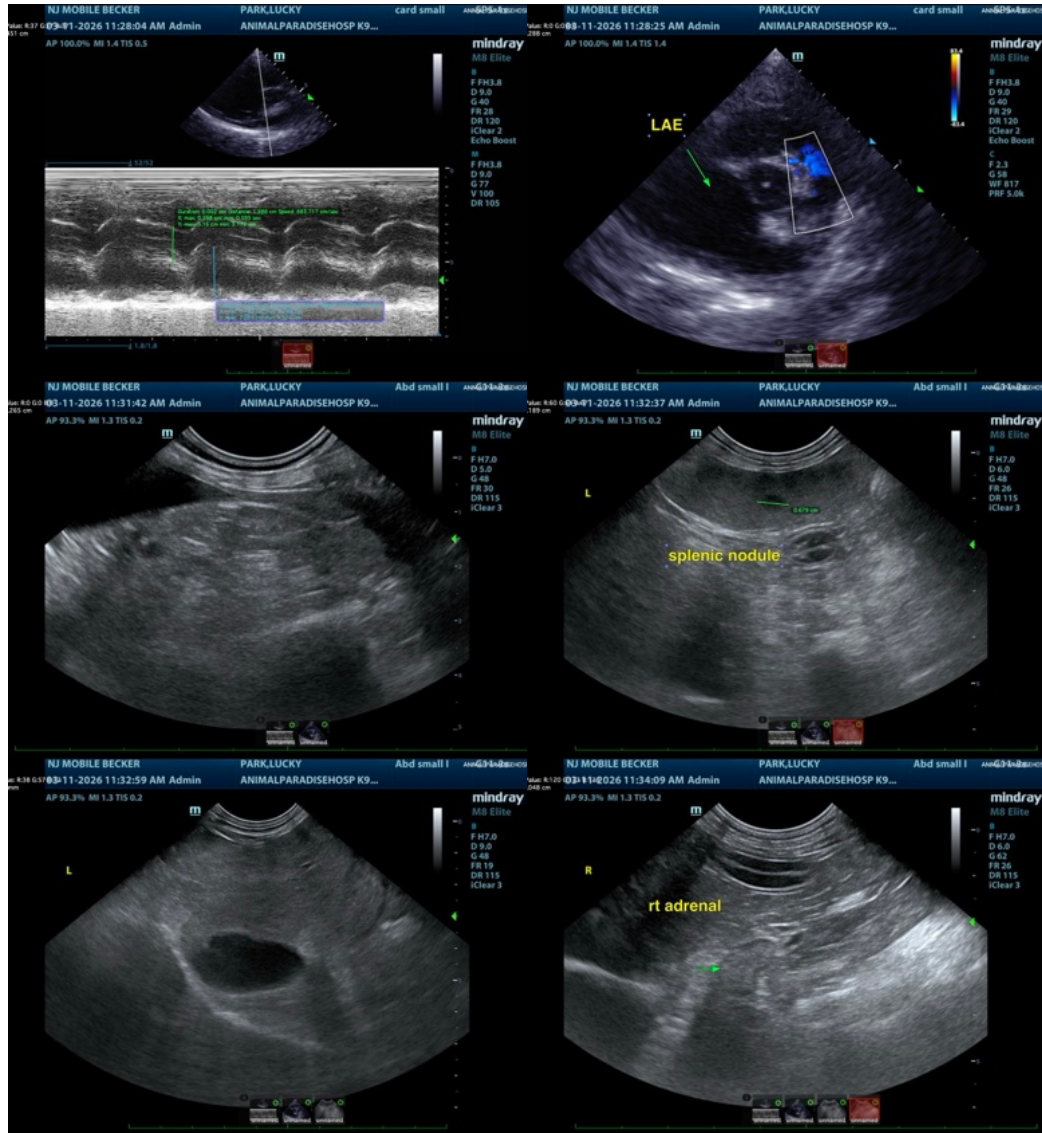
Dr. ElShafie

INVOICE

73397

DATE

3/11/26



The information and recommendations provided are based on the images presented by the referring veterinarian/sonographer. No evaluation can be communicated regarding pathology that was not visible in the image/video clips provided.

Thank you for this referral. If the clinical or image interpretation does not parallel your findings or if I can be of any further assistance please contact me.

Eric Lindquist, DMV, DABVP (CFM), Cert. IVUSS, CEO of SonoPath.com

Info@SonoPath.com