

PATIENT

Cabo Ferrara

SPECIES

Canine

BREED

Husky

SEX

Male

AGE

7 months

WEIGHT

62.9 lbs

PRESENTING CLINICAL SIGNS

- Episodes of vomiting, lethargy and ataxia
- BW WNL

ULTRASONOGRAPHIC EXAMINATION OF THE HEART

The echocardiogram in this patient demonstrated normal **left atrial** size based on 3 separate methods of LA evaluation. The cranial and caudal **mitral** valve leaflets presented normal linear structure, extension in systole, and union in diastole with normal kinesis. The **left ventricle** presented thicknesses with linear contour and was not dilated nor restricted. The **myocardium** presented normal echogenicity without subjective evidence of significant fibrotic or ischemic disease. **Contractility** of the ventricular walls was adequate and in normal range for this patient evidenced by the fractional shortening measurement and subjective evaluation of the different regions of the myocardium. The **left ventricular outflow** tract demonstrated normal laminar flow and subjective structural integrity. The **right atrium** and auricle revealed normal size, structure and content. No evidence of masses was noted. **Tricuspid** valvular assessment demonstrated adequate linear morphology and kinesis. The **right ventricle** was of normal size (1/3 diameter of LV), chordae structure, myocardial echogenicity and thickness. **Pulmonary outflow** tract assessment revealed normal valve structure, laminar flow, and diameter (approx.1:1 pa/ao ratio). No visible **pericardial** or free pleura fluid was noted. The cranial **mediastinum and pericardial and extra-cardiac regions** were free of masses in the visible window.

INTERPRETED BY

Eric Lindquist, DMV,
 DABVP (CFM), Cert.
 IVUSS, CEO of
 SonoPath.com

IMAGING PERFORMED BY

Vincent Ravancho,
 CVT

HOSPITAL NAME

Brenda King VMD

REFERRING VET

Dr. King

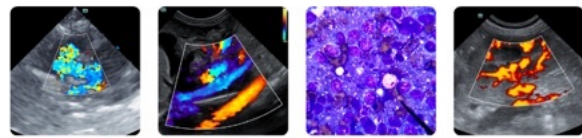
INVOICE

71394

DATE

2/9/26

CANINE CARDIAC PARAMETERS	MR VMAX (m/s)	TR VMAX (m/s)	LA/AO	LA/AO (Heart Base)	FS (%)	EF (%)	EPSS (cm)
NORMAL PARAMETER	4.5-5.5	<2.7	1.3	<1.6	28-40	40-100	<0.6
PATIENT	-	-	1.0	1.3	25	50	0.3
CANINE CARDIAC PARAMETERS	HR (BPM)	AV VMAX (m/s)	PV MAX (m/s)	BODY WEIGHT	LA 2D short axis Base view (cm)	LVIDd Avg; 2D and m-mode short axis (cm)	LVIDs Avg; 2D and m-mode short axis (cm)
NORMAL PARAMETER	50-100	0.7-1.7	0.7-1.6	BELOW	BELOW	BELOW	BELOW
PATIENT	82	1.35	0.7	62.9 lbs	2.9	3.56	



PATIENT

Cabo Ferrara

SPECIES

Canine

BREED

Husky

SEX

Male

AGE

7 months

WEIGHT

62.9 lbs

INTERPRETED BY

Eric Lindquist, DMV,
DABVP (CFM), Cert.
IVUSS, CEO of
SonoPath.com

IMAGING PERFORMED BY

Vincent Ravancho,
CVT

HOSPITAL NAME

Brenda King VMD

REFERRING VET

Dr. King

INVOICE

71394

DATE

2/9/26

ULTRASONOGRAPHIC EXAMINATION OF THE ABDOMEN

Urinary System

The **urinary bladder**, trigone, and pelvic urethra presented normal thicknesses and normal tone. The ureters were not visible which is normal. No uroliths or sediment were visualized and anechoic urine was present. No evidence of inflammatory or neoplastic changes was noted. Ureteral papillae were normal.

The **kidneys** revealed normal size and structure, corticomedullary definition and ratio for this age. The cortices presented largely uniform texture with normal echogenic relationship to liver and spleen. Medullary structure differed distinctly from the cortex and no evidence of pelvic dilation was present. The capsules were acceptably uniform without significant irregularities. The left kidney measured 6.56 cm. The right kidney measured 6.15 cm.

The prostate was uniform and measured 2.5 cm.

Adrenal Glands

The left **adrenal gland** was slightly subnormal in size and measured 2.15 x 0.27 cm at the cranial pole and 0.44 cm at the caudal pole. The right adrenal gland was subnormal in size measuring 2.02 x 0.77 cm at the caudal pole and 0.29 cm at the cranial pole.

Spleen

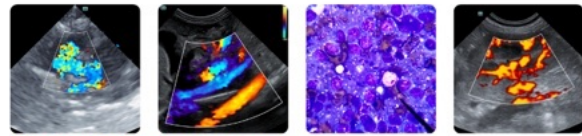
The **spleen** presented a smooth homogeneous parenchyma hyperechoic to liver and renal cortical parenchyma. The capsule was smooth without noticeable expansion or deviation from within the spleen or adjacent pathology. The splenic vasculature demonstrated normal volume without signs of congestion or thrombosis. No sonographic evidence of acute or chronic inflammatory, neoplastic, or infarctual changes was noted.

Liver

The **liver** images submitted revealed subjectively normal liver size, contour, and structure. Parenchymal echogenicity was naturally coarse and hypoechoic to the spleen. Vascular and biliary tracts were of normal volume with no evidence of congestion. The gallbladder presented acceptably thin walls with primarily anechoic content. The cystic and common bile ducts were normal. No pathological hepatic lymphadenopathy was evident. No overt structural evidence of inflammatory, infiltrative or regenerative pathology was evident.

Gastrointestinal

Examination of the **gastrointestinal tract** revealed a stomach and intestine free of stasis, of normal wall thickness, acceptable curvilinear mural detail, and peristaltic activity. Small and large intestine demonstrated normal luminal chyme and stool consistency respectively. No obstructive or overt infiltrative disease was noted. No associated abnormal lymphatic activity was noted.



PATIENT

Cabo Ferrara

SPECIES

Canine

BREED

Husky

SEX

Male

AGE

7 months

WEIGHT

62.9 lbs

INTERPRETED BY

Eric Lindquist, DMV,
DABVP (CFM), Cert.
IVUSS, CEO of
SonoPath.com

IMAGING PERFORMED BY

Vincent Ravancho,
CVT

HOSPITAL NAME

Brenda King VMD

REFERRING VET

Dr. King

INVOICE

71394

DATE

2/9/26

Pancreas

The base and limbs of the **pancreas** were observed to be largely isoechoic to surrounding omental fat. Pancreatic duct and capsular contour were acceptably normal and parenchyma respected normal curvilinear patterns. No overt evidence of active inflammatory or neoplastic disease was noted.

ULTRASONOGRAPHIC FINDINGS

Normal echocardiogram, no evidence of pathology.

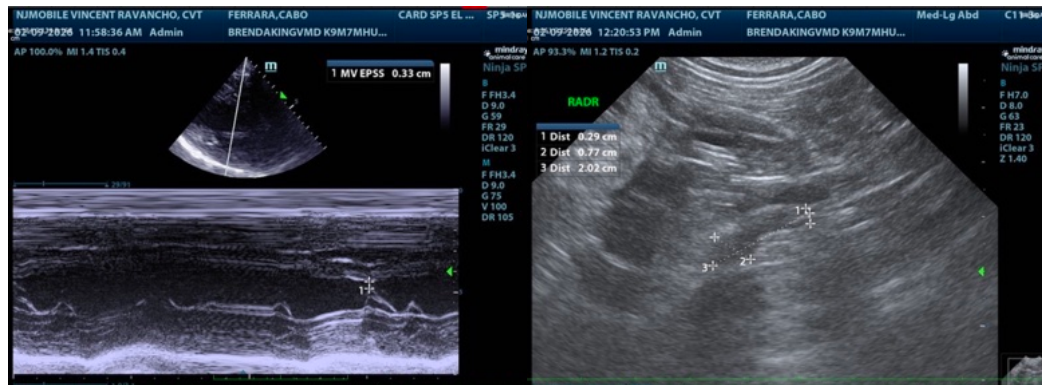
Slight subnormal adrenal size.

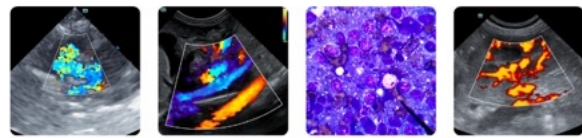
INTERPRETATION OF THE FINDINGS & FURTHER RECOMMENDATIONS

Structurally and functionally the heart appears normal. However, I cannot rule out a paroxysmal arrhythmia. Long EKG or Holter monitor would be appropriate if arrhythmogenic disease is suspected. This can be obtained from our office.

Baseline cortisol is warranted given the vague clinical signs to ensure that congenital Addison's is not in play in this patient.

Dietary indiscretion, food intolerance, structurally significant inflammatory bowel or occult parasitism and occult Addison's are all potentials.





PATIENT

Cabo Ferrara

SPECIES

Canine

BREED

Husky

SEX

Male

AGE

7 months

WEIGHT

62.9 lbs

INTERPRETED BY

Eric Lindquist, DMV,
 DABVP (CFM), Cert.
 IVUSS, CEO of
 SonoPath.com

**IMAGING
 PERFORMED BY**

Vincent Ravancho,
 CVT

HOSPITAL NAME

Brenda King VMD

REFERRING VET

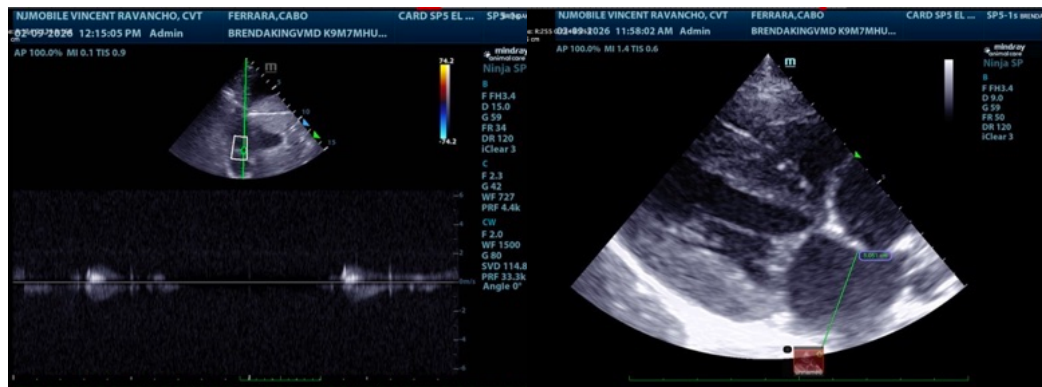
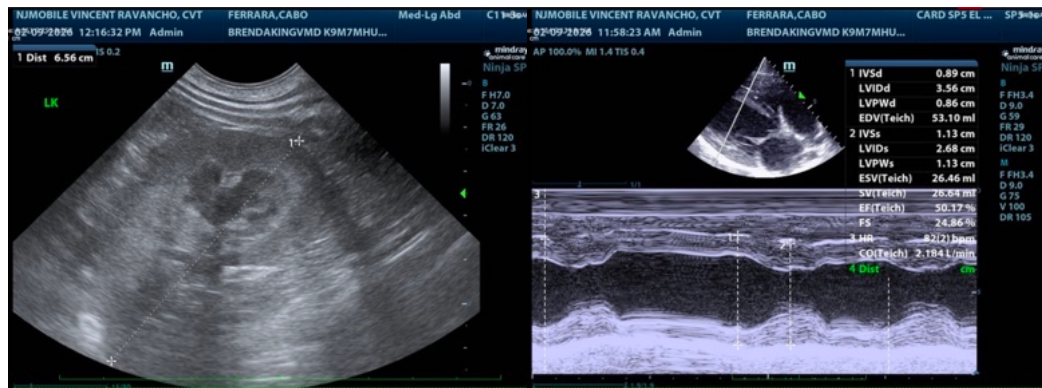
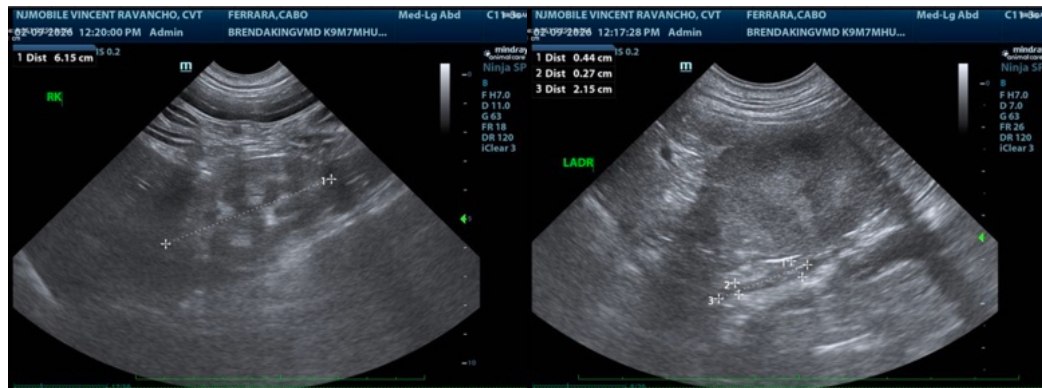
Dr. King

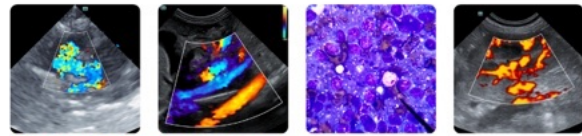
INVOICE

71394

DATE

2/9/26





PATIENT

Cabo Ferrara

SPECIES

Canine

BREED

Husky

SEX

Male

AGE

7 months

WEIGHT

62.9 lbs

INTERPRETED BY

Eric Lindquist, DMV, DABVP (CFM), Cert. IVUSS, CEO of SonoPath.com

IMAGING PERFORMED BY

Vincent Ravancho, CVT

HOSPITAL NAME

Brenda King VMD

REFERRING VET

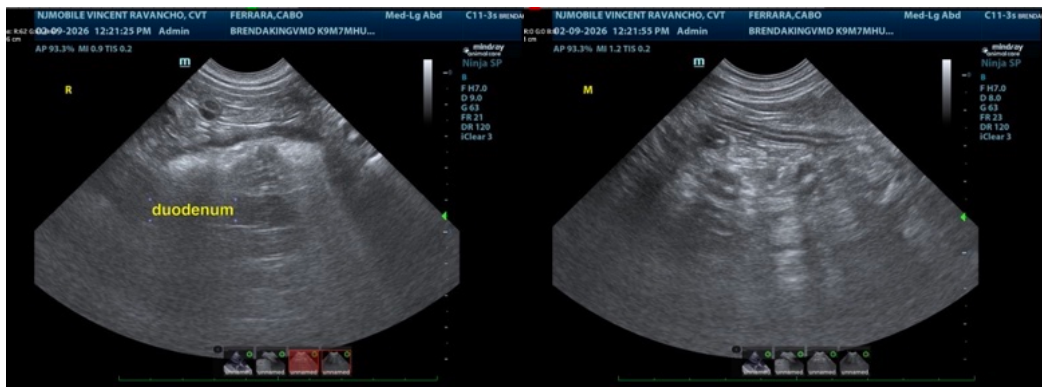
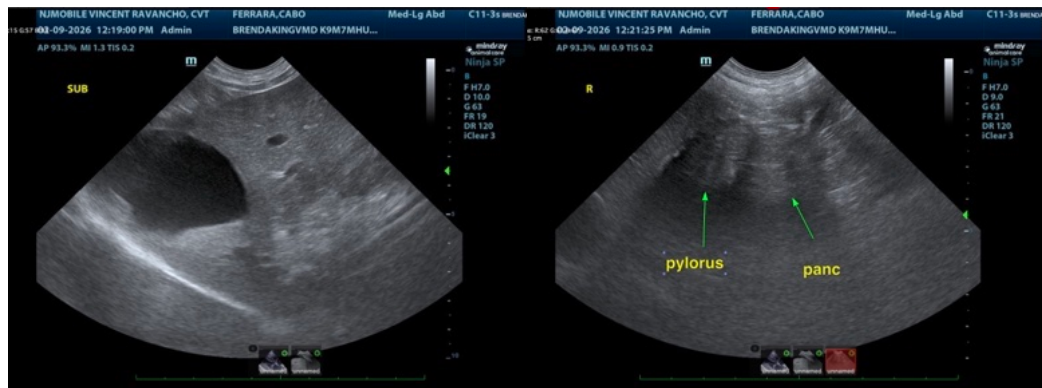
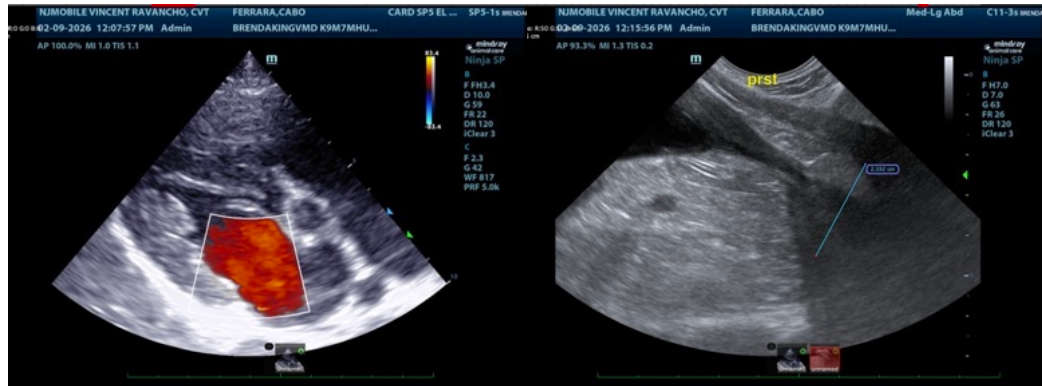
Dr. King

INVOICE

71394

DATE

2/9/26



The information and recommendations provided are based on the images presented by the referring veterinarian/sonographer. No evaluation can be communicated regarding pathology that was not visible in the image/video clips provided.

Thank you for this referral. If the clinical or image interpretation does not parallel your findings or if I can be of any further assistance please contact me.

Eric Lindquist, DMV, DABVP (CFM), Cert. IVUSS, CEO of SonoPath.com

Info@SonoPath.com