



PATIENT

Scrappy Cinove

SPECIES

Ferret

BREED

Domestic

SEX

Neutered male

AGE

5 year

WEIGHT

2.5 lbs

INTERPRETED BY

Eric Lindquist, DMV
 DABVP, Cert. IVUSS

IMAGING PERFORMED BY

Rebecca Hamilton

HOSPITAL NAME

Harmony AH

REFERRING VET

Dr. Gruber

INVOICE

71149

DATE

2/3/26

PRESENTING CLINICAL SIGNS

- suspect CHF, R/O HW DZ, increase RR/RE. Lethargic, coughing
- meds: Dose of Lasix, 1 dose Pimobendan in Hospital,
- CXR - appears to show cardiomegaly w/ interstitial -> alveolar pattern emerging. BG 90

ULTRASONOGRAPHIC EXAMINATION OF THE HEART

The echocardiogram in this patient demonstrated mild volume overload of the **left and right atria and left ventricle**. **Mitral** valve insufficiency was noted. Septal and free wall thicknesses were normal. The pulmonary artery was dilated with **pulmonic** insufficiency. The main and auxiliary branch of the pulmonary artery were dilated. Pulmonary edema lines were noted. The hepatic veins were dilated. This is consistent with emerging left-sided failure. No visible **pericardial** or free pleura fluid was noted or extra cardiac pathology in the visible planes. The cranial **mediastinum and pericardial regions** were free of masses in the visible window.

CARDIAC PARAMETERS	BODY WEIGHT	HR (BPM)	IVSd (cm)	LVIDd (cm)	LVWd (cm)	FS (%)	EF (%)
NORMAL PARAMETER	-----	150-240	0.3-0.6	1.0-2.1	0.25-0.6	35-67	80-100
PATIENT	2.5 lbs	200	0.5	1.8	0.5	30	70
CARDIAC PARAMETERS	LA/AO (M-mode)	LA/AO HEART BASE (Sisson)	LAD LA MAX 4 Chamber		LVOT VEL. (m/s)	RVOT VEL. (m/s)	IVRT (m/)
NORMAL PARAMETER	<1.5	1.6	0.7-1.7		<1.6	<1.3	40-60
PATIENT	1.4	2.0	2.0		0.9	0.9	NM

Adapted from June Boon, Veterinary Echocardiography, 1998
 Sisson D et al. JVIM 1991; 5: 232, Jacobs et al. Am J Vet Res 1985; 46:1705

ULTRASONOGRAPHIC FINDINGS

Unclassified cardiomyopathy with left and right-sided failure.

INTERPRETATION OF THE FINDINGS & FURTHER RECOMMENDATIONS

I recommend continuation of Pimobendan and Lasix. Consideration for infectious causes of myocarditis should also be considered. Ace inhibitor is also indicated. Stabilization with oxygen is recommended. Recheck sonogram is recommended in 10-14 days.



PATIENT

Scrappy Cinove

SPECIES

Ferret

BREED

Domestic

SEX

Neutered male

AGE

5 year

WEIGHT

2.5 lbs

INTERPRETED BY

Eric Lindquist, DMV
 DABVP, Cert. IVUSS

IMAGING PERFORMED BY

Rebecca Hamilton

HOSPITAL NAME

Harmony AH

REFERRING VET

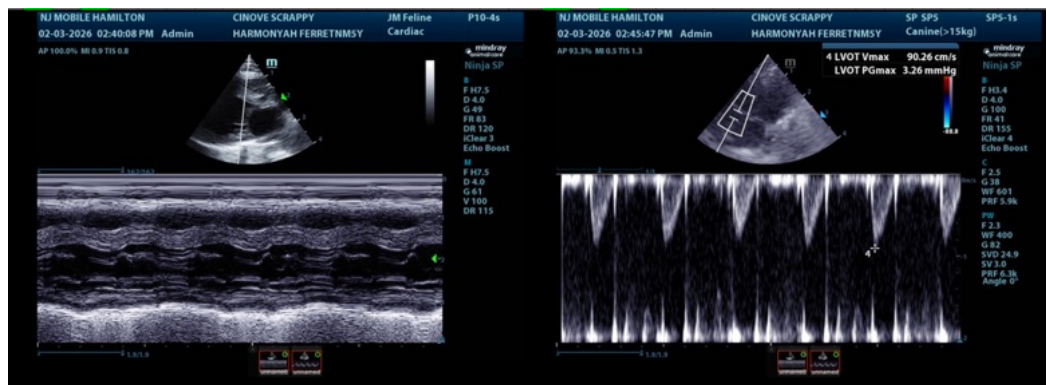
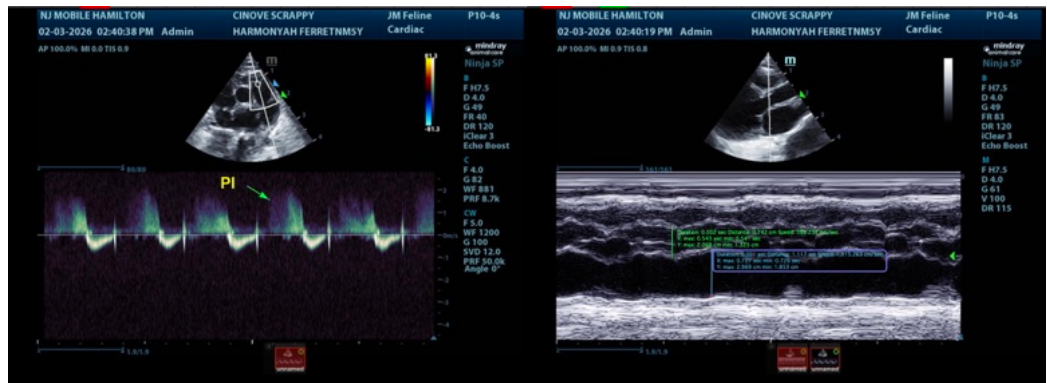
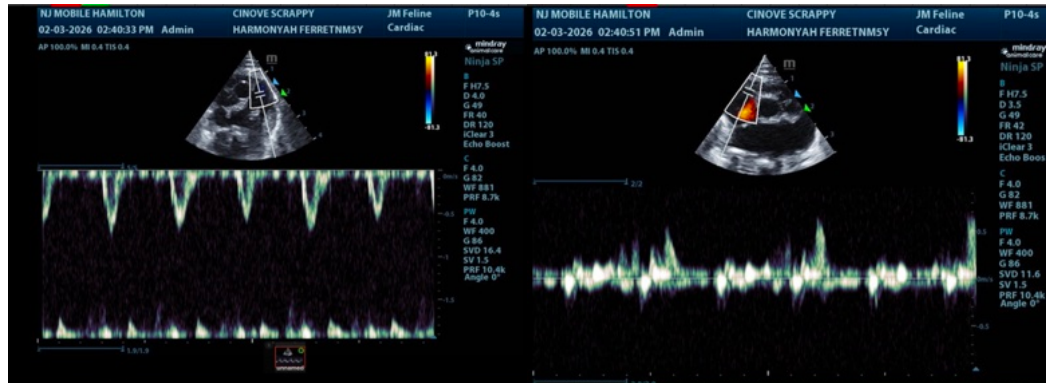
Dr. Gruber

INVOICE

71149

DATE

2/3/26





PATIENT

Scrapy Cinove

SPECIES

Ferret

BREED

Domestic

SEX

Neutered male

AGE

5 year

WEIGHT

2.5 lbs

INTERPRETED BY

Eric Lindquist, DMV
 DABVP, Cert. IVUSS

IMAGING PERFORMED BY

Rebecca Hamilton

HOSPITAL NAME

Harmony AH

REFERRING VET

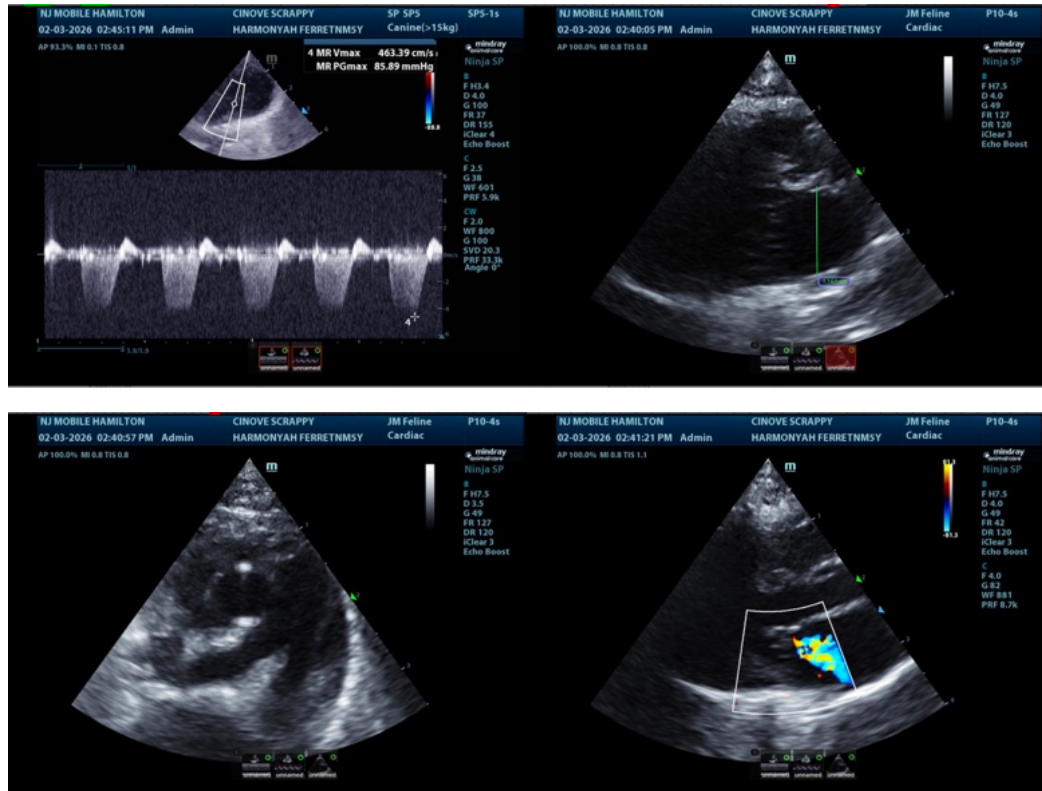
Dr. Gruber

INVOICE

71149

DATE

2/3/26



The information and recommendations provided are based on the images presented by the referring veterinarian/sonographer. No evaluation can be communicated regarding pathology that was not visible in the image/video clips provided.

Thank you for this referral. If the clinical or image interpretation does not parallel your findings or if I can be of any further assistance please contact me.

Eric Lindquist, DMV, DABVP, Cert. IVUSS, CEO of SonoPath.com

info@SonoPath.com