



PATIENT

Toby Pimental

SPECIES

Canine

BREED

Dachshund Mix

SEX

Neutered male

AGE

12 years

WEIGHT

Not provided

INTERPRETED BY

Eric Lindquist, DMV
 DABVP, Cert. IVUSS

IMAGING PERFORMED BY

Rebecca Hamilton

HOSPITAL NAME

Ramapo Valley AH

REFERRING VET

Dr. Katara

INVOICE

72051

DATE

2/27/26

PRESENTING CLINICAL SIGNS

- Recheck echo. Murmur getting louder, was 2-3/6 now is 4/6
- No current meds

ULTRASONOGRAPHIC EXAMINATION OF THE HEART

The echocardiogram in this patient presented persistently normal volumes with mitral and tricuspid insufficiency. The contractility was adequate. All four chambers revealed normal volumes without evidence of clots. Mitral insufficiency was moderate. Left and right ventricular outflow velocities were normal. There was no evidence of arrhythmogenic activity. There was no pericardial or pleural effusion was noted.

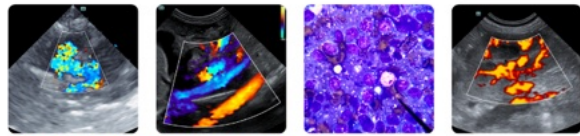
CANINE CARDIAC PARAMETERS	MR VMAX (m/s)	TR VMAX (m/s)	LA/AO	LA/AO (Heart Base)	FS (%)	EF (%)	EPSS (cm)
NORMAL PARAMETER	4.5-5.5	<2.7	1.3	<1.6	28-40	40-100	<0.6
PATIENT	6.0	2.86	1.5	1.3	52	84	0.1
CANINE CARDIAC PARAMETERS	HR (BPM)	AV VMAX (m/s)	PV MAX (m/s)	BODY WEIGHT (kg)	LA 2D short axis Base view (cm)	LVIDd Avg; 2D and m-mode short axis (cm)	LVIDs Avg; 2D and m-mode short axis (cm)
NORMAL PARAMETER	50-100	0.7-1.7	0.7-1.6	BELOW	BELOW	BELOW	BELOW
PATIENT	133	1.65	0.9	-	3.2	3.1	

ULTRASONOGRAPHIC FINDINGS

Stable stage B1 valvular disease.
 No progression from the prior echocardiogram.

INTERPRETATION OF THE FINDINGS & FURTHER RECOMMENDATIONS

The heart is stable without clinical disease. No overt contraindication for anesthesia of brief to moderate duration. I suggest Torbutrol premed, Propofol induction, Isoflo maintenance or similar protocol if anesthesia is desired. Blood pressure recommended if not already performed and target white coat negative systolic pressure of < 160 mmHg. If higher than this ACE-inhibitor is suggested to reach this level. Recheck echocardiogram is recommended in 6 months, earlier if murmur grade increases or clinical signs initiate.



PATIENT

Toby Pimental

SPECIES

Canine

BREED

Dachshund Mix

SEX

Neutered male

AGE

12 years

WEIGHT

Not provided

INTERPRETED BY

Eric Lindquist, DMV
 DABVP, Cert. IVUSS

IMAGING PERFORMED BY

Rebecca Hamilton

HOSPITAL NAME

Ramapo Valley AH

REFERRING VET

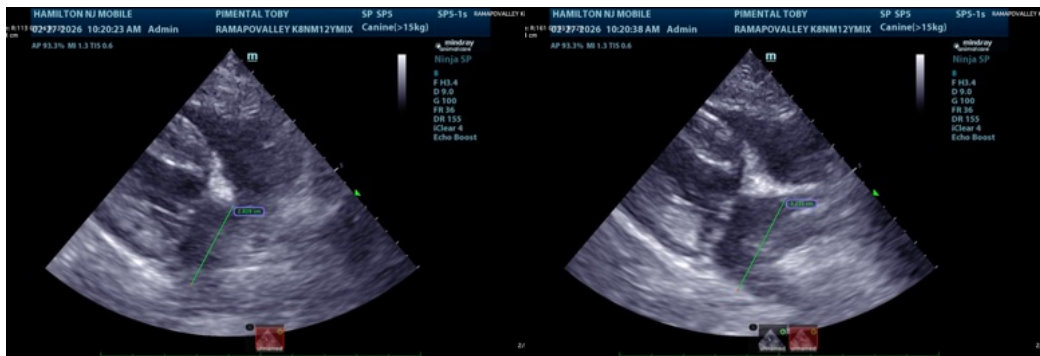
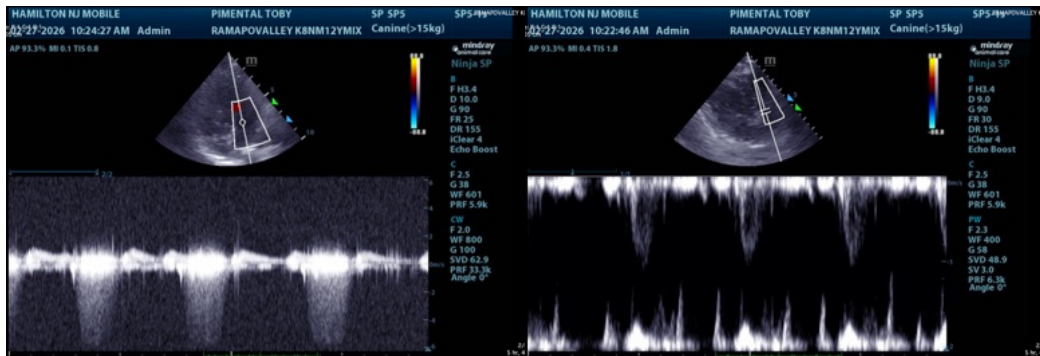
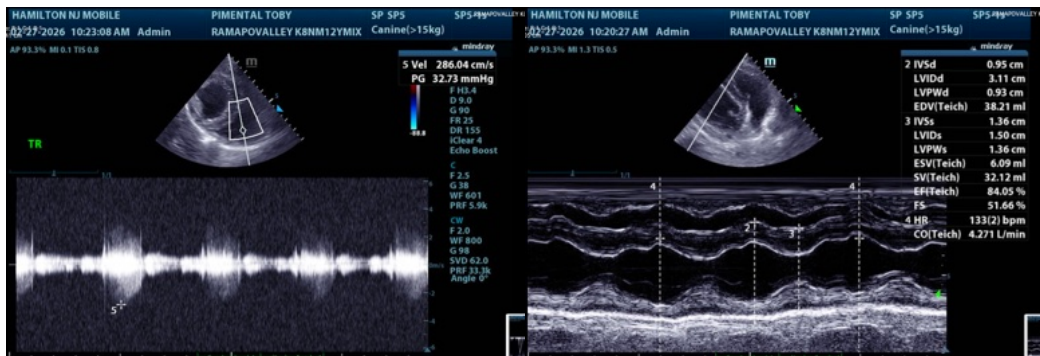
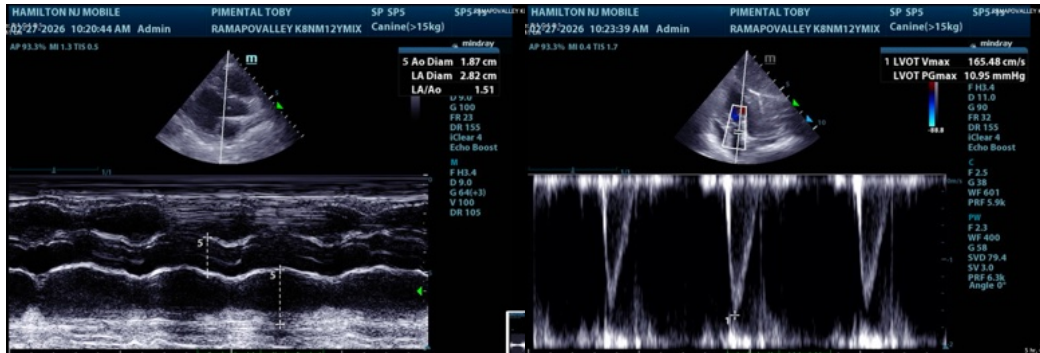
Dr. Katara

INVOICE

72051

DATE

2/27/26





PATIENT

Toby Pimental

SPECIES

Canine

BREED

Dachshund Mix

SEX

Neutered male

AGE

12 years

WEIGHT

Not provided

INTERPRETED BY

Eric Lindquist, DMV
DABVP, Cert. IVUSS

IMAGING PERFORMED BY

Rebecca Hamilton

HOSPITAL NAME

Ramapo Valley AH

REFERRING VET

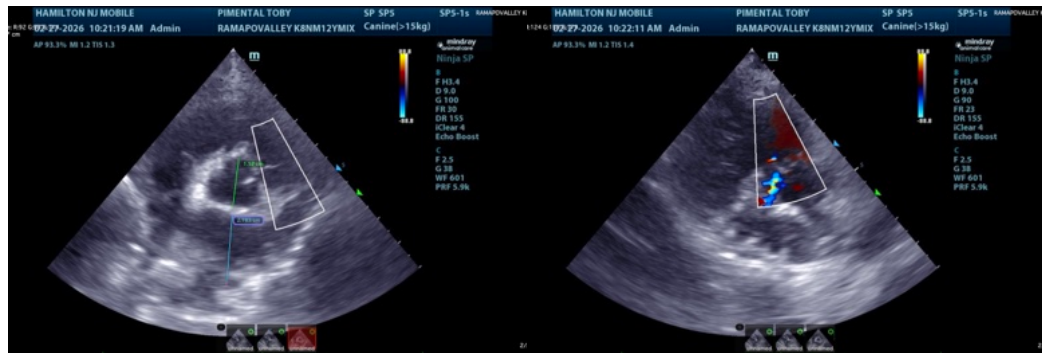
Dr. Katara

INVOICE

72051

DATE

2/27/26



The information and recommendations provided are based on the images presented by the referring veterinarian/sonographer. No evaluation can be communicated regarding pathology that was not visible in the image/video clips provided.

Thank you for this referral. If the clinical or image interpretation does not parallel your findings or if I can be of any further assistance please contact me.

Eric Lindquist, DMV, DABVP, Cert. IVUSS, CEO of SonoPath.com

info@SonoPath.com