



**PATIENT**

Rocky Giampa

**SPECIES**

Canine

**BREED**

Poodle Cross

**SEX**

Neutered male

**AGE**

7 years

**WEIGHT**

26 lbs

**INTERPRETED BY**

Eric Lindquist, DMV,  
DABVP, Cert. IVUSS,  
CEO of SonoPath.com

**IMAGING PERFORMED BY**

Eric Lindquist, DMV,  
DABVP, Cert. IVUSS,  
CEO of SonoPath.com

**HOSPITAL NAME**

Franklin Lakes AH

**REFERRING VET**

Dr.  
Greenhut/Mastrascusa

**INVOICE**

71816

**DATE**

2/24/26

**PRESENTING CLINICAL SIGNS**

Diarrhea, inappetence, lethargy. Albumin 1.6

**ULTRASONOGRAPHIC EXAMINATION OF THE ABDOMEN**

**Urinary System**

The **urinary bladder**, trigone, and pelvic urethra presented normal thicknesses and normal tone. The pelvic urethra was imaged 3.0 cm beyond the cystourethral junction and appeared normal. The ureters were not visible which is normal. No uroliths or sediment were visualized and anechoic urine was present. No evidence of inflammatory or neoplastic changes was noted. Ureteral papillae were normal.

The **kidneys** revealed normal size and structure, corticomedullary definition and ratio for this age. The cortices presented largely uniform texture with normal echogenic relationship to liver and spleen. Medullary structure differed distinctly from the cortex and no evidence of pelvic dilation was present. The capsules were acceptably uniform without significant irregularities. The left kidney measured 5.2 cm. The right kidney measured 4.9 cm.

The residual **prostate** measured 0.8 cm.

**Adrenal Glands**

The **adrenal glands** were flattened in this patient. If the patient was given Prednisone then this would be a normal variant. The left adrenal gland measured 1.24 x 0.28 cm. The right adrenal gland measured 1.5 x 0.4 cm.

**Spleen**

The **spleen** presented a smooth homogeneous parenchyma hyperechoic to liver and renal cortical parenchyma. The capsule was smooth without noticeable expansion or deviation from within the spleen or adjacent pathology. The splenic vasculature demonstrated normal volume without signs of congestion or thrombosis. No sonographic evidence of acute or chronic inflammatory, neoplastic, or infarctual changes was noted.

**Liver**

The **liver** images submitted revealed subjectively normal liver size, contour, and structure. Parenchymal echogenicity was naturally coarse and hypoechoic to the spleen. Vascular and biliary tracts were of normal volume with no evidence of congestion. The gallbladder presented acceptably thin walls with primarily anechoic content. The cystic and common bile ducts were normal. No pathological hepatic lymphadenopathy was evident. No overt structural evidence of inflammatory, infiltrative or regenerative pathology was evident.



**PATIENT**

Rocky Giampa

**SPECIES**

Canine

**BREED**

Poodle Cross

**SEX**

Neutered male

**AGE**

7 years

**WEIGHT**

26 lbs

**INTERPRETED BY**

Eric Lindquist, DMV,  
DABVP, Cert. IVUSS,  
CEO of SonoPath.com

**IMAGING PERFORMED BY**

Eric Lindquist, DMV,  
DABVP, Cert. IVUSS,  
CEO of SonoPath.com

**HOSPITAL NAME**

Franklin Lakes AH

**REFERRING VET**

Dr.  
Greenhut/Mastrascusa

**INVOICE**

71816

**DATE**

2/24/26

**Gastrointestinal**

Examination of the **gastrointestinal tract** revealed an unremarkable stomach and small intestine regarding structure. There were minor areas of luminal fluid noted. There was no evidence of obstructive pattern. Areas of mucosal speckling was noted. Curvilinear patterns were retained throughout the gastrointestinal tract. Areas of hyperperistalsis were noted. This is consistent with response to irritation. The colon was unremarkable.

**Pancreas**

The base and limbs of the **pancreas** were observed to be largely isoechoic to surrounding omental fat. Pancreatic duct and capsular contour were acceptably normal and parenchyma respected normal curvilinear patterns. No overt evidence of active inflammatory or neoplastic disease was noted.

**ULTRASONOGRAPHIC FINDINGS**

- Gastroenteritis.
- Flattened adrenal glands, yet Addison's has been ruled out with baseline cortisol.

**INTERPRETATION OF THE FINDINGS & FURTHER RECOMMENDATIONS**

Non-specific protein losing enteropathy is suspected if no significant proteinuria is present.

Differentials for diarrhea include occult parasitism. Dietary indiscretion, dietary intolerance, antibiotic responsive colitis, intestinal dysbiosis. A hydrolyzed diet trial may be in this patient's best interest +/- probiotics. 24-hour NPO and reintroduction of bland diet indicated. I recommend a baseline cortisol or ACTH stimulation test, a fresh fecal smear and fecal floatation analysis if not already performed.

Part or all of this protocol may be considered based on your clinical impression of the patient:

**OBJECTIVE: keep albumin levels > 2 g/dl, avoid thromboembolism and cavitory effusions, monitor concurrent PLN (Wheaton Terrier PLE/PLN) and liver disease:**

**Plasma** 10 mL / kilogram IV over 4 hours

Or **Human albumin** 2 ml/kg/h over 10 hours. Total daily volume 20.l/kg/day

**And Colloids/Hetastarch**

10 to 20 mL per kilogram per day and dogs

10 to 15 mL per kilogram per day cats

(Can bolus first 1/3 of dose over 15 minutes)

& maintain on LRS maintenance otherwise.

**Metronidazole** (10-20 mg/kg po bid)

**Famotidine** 1 mg/kg lv lm po dc Sid /bid

**Sucralfate** 0.5-1 g po tid dogs, 0.5 g bid cats in slurry Or **Misoprostol** 1-5 ug/kg po tid

**Diet:** Highly digestible high quality protein, low fiber, low fat diet (< 15% of dry matter). Hydrolyzed protein or novel protein. Purina HA or Royal Canine HP or similar.

**Prednisone** or prednisolone 2 mg/kg bid x 3-5 days then 2 mg/kg sid. **Chlorambucil** in refractive severe IBD/alimentary lymphoma cases (monitor cbc for rare bone marrow suppression) 4 mg/m<sup>2</sup>Q 24-48 hours.



**PATIENT**

Rocky Giampa

**SPECIES**

Canine

**BREED**

Poodle Cross

**SEX**

Neutered male

**AGE**

7 years

**WEIGHT**

26 lbs

**INTERPRETED BY**

Eric Lindquist, DMV,  
 DABVP, Cert. IVUSS,  
 CEO of SonoPath.com

**IMAGING PERFORMED BY**

Eric Lindquist, DMV,  
 DABVP, Cert. IVUSS,  
 CEO of SonoPath.com

**HOSPITAL NAME**

Franklin Lakes AH

**REFERRING VET**

Dr.  
 Greenhut/Mastrascusa

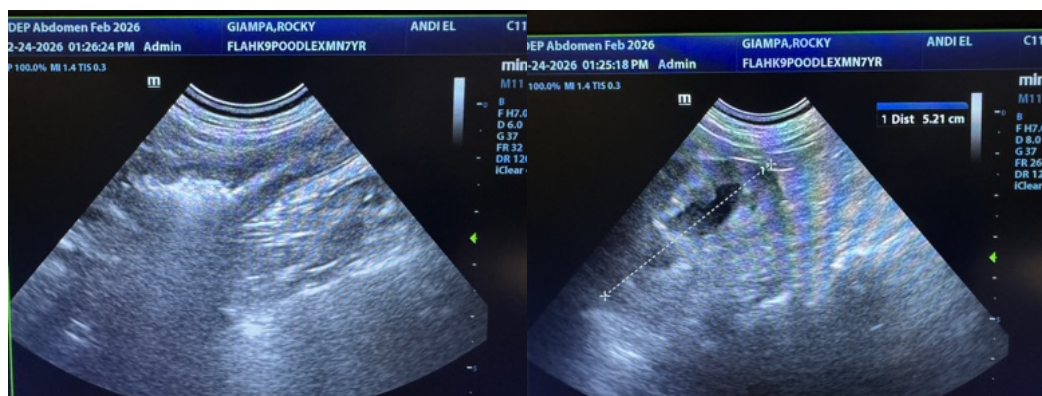
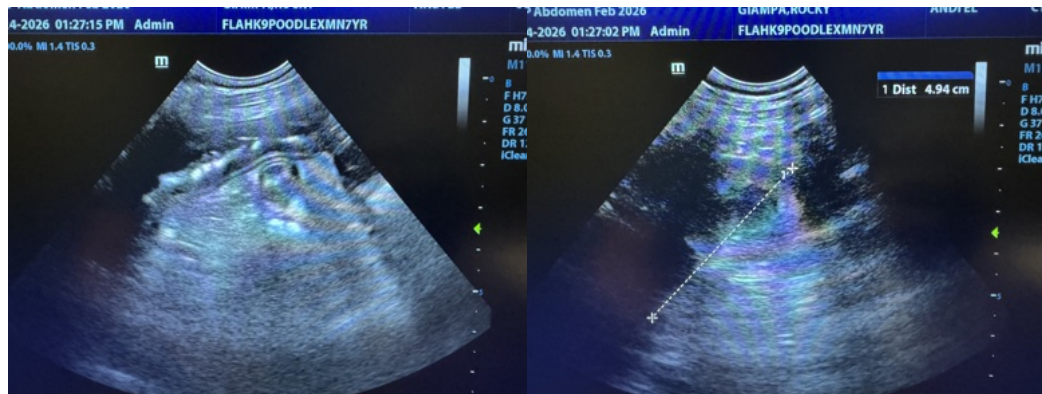
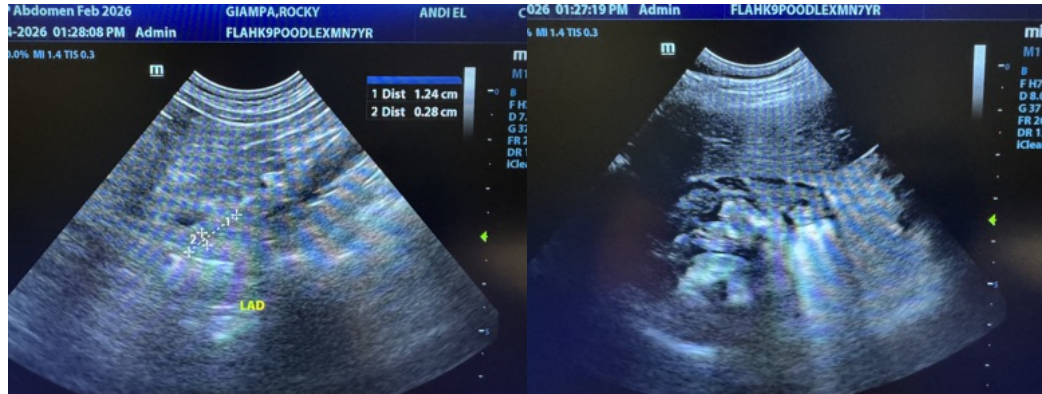
**INVOICE**

71816

**DATE**

2/24/26

**Cobalamine (B12) 250-1500 ug/dog weekly x 6 weeks.**  
**Calcium supplementation if necessary.**  
**Aspirin 0.5-1 mg/kg/day or Clopidrel (Plavix) 1-5 mg/kg/day.**





**PATIENT**

Rocky Giampa

**SPECIES**

Canine

**BREED**

Poodle Cross

**SEX**

Neutered male

**AGE**

7 years

**WEIGHT**

26 lbs

**INTERPRETED BY**

Eric Lindquist, DMV,  
 DABVP, Cert. IVUSS,  
 CEO of SonoPath.com

**IMAGING PERFORMED BY**

Eric Lindquist, DMV,  
 DABVP, Cert. IVUSS,  
 CEO of SonoPath.com

**HOSPITAL NAME**

Franklin Lakes AH

**REFERRING VET**

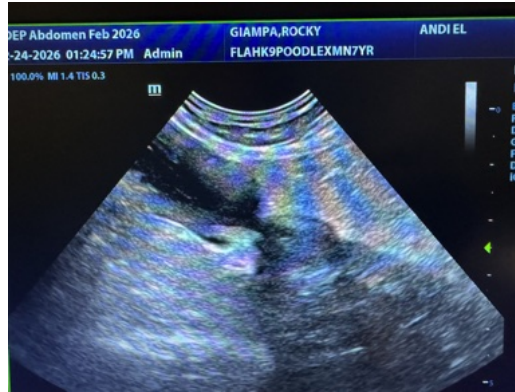Dr.  
 Greenhut/Mastrascusa

**INVOICE**

71816

**DATE**

2/24/26




The information and recommendations provided are based on the images presented by the referring veterinarian/sonographer. No evaluation can be communicated regarding pathology that was not visible in the image/video clips provided.

Thank you for this referral. If the clinical or image interpretation does not parallel your findings or if I can be of any further assistance please contact me.

Eric Lindquist, DMV, DABVP, Cert. IVUSS, CEO of SonoPath.com

[Info@SonoPath.com](mailto:Info@SonoPath.com)



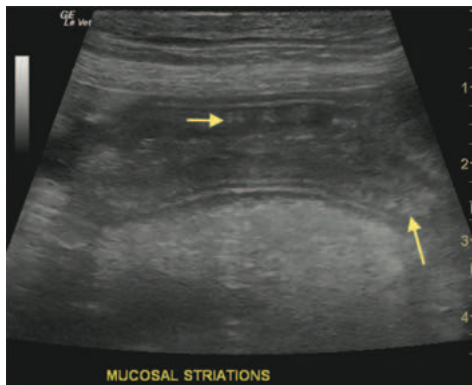
The following is an applicable excerpt from the *Curbside Guide to Diagnosis & Treatment of Sonographic Disease* offered by [SonoPath.com](http://sonopath.com) Lindquist, Frank, and Modler.

An essential quick guide for every general practitioner and sonographer.

<https://sonopath.com/products/curbside-guide-editing-due-release-12012015>

**Protein-Losing Enteropathy (PLE)**

<http://www.sonopath.com/PLE>



Long axis of the jejunum in a dog with protein losing enteropathy. Note the presence of multiple vertical hyperchoic mucosal striations (small arrow) also described as “tiger stripe pattern”— pathognomonic for lacteal dilation. Groupings of striations creating a nebulous echogenic mucosal appearance as seen here can be referred to as “mucosal fogging” (large arrow).



**PATIENT**

Rocky Giampa

**SPECIES**

Canine

**BREED**

Poodle Cross

**SEX**

Neutered male

**AGE**

7 years

**WEIGHT**

26 lbs

**INTERPRETED BY**

Eric Lindquist, DMV,  
 DABVP, Cert. IVUSS,  
 CEO of SonoPath.com

**IMAGING PERFORMED BY**

Eric Lindquist, DMV,  
 DABVP, Cert. IVUSS,  
 CEO of SonoPath.com

**HOSPITAL NAME**

Franklin Lakes AH

**REFERRING VET**

Dr.  
 Greenhut/Mastrascusa

**INVOICE**

71816

**DATE**

2/24/26

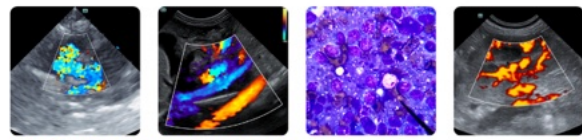
**Description:** Protein-losing enteropathy (PLE) is characterized by conditions or disease processes that cause protein loss through the gastrointestinal (GI) mucosa. Clinical signs related to hypoalbuminemia will occur when albumin levels drop below 1.5 g/dl; a loss of oncotic pressure will ensue and precipitate ascites, thoracic effusion, and peripheral edema. Causes of PLE may include: inflammatory changes to the gastrointestinal mucosa or inflammatory bowel disease (IBD); food allergies resulting in IBD; ulcerative disease; granulomatous disease (fungal disease); immunoproliferative enteropathy; neoplasia (lymphoma being most common); and lymphangiectasia. Intussusception and parasitic infection can result in PLE in young animals. Lymphangiectasia typically occurs as a secondary disease process, with lymphatic duct dilation secondary to underlying inflammation or neoplastic cells. Primary lymphangiectasia is a congenital disease typically found in young dogs, especially Basenjis and Norwegian Lundehunds. Some breeds, such as Wheaten Terriers, Rottweilers, German Shepherds, Norwegian Lundehunds, Yorkshire Terriers, and Basenjis, are more predisposed to PLE than others. Heritability has been demonstrated in Wheaten Terriers and Basenjis. Yorkshire Terriers are ten times more likely to develop IBD and nine times more likely to suffer hypocalcemia and hypomagnesemia with IBD.

**Clinical Signs:** Canine patients are typically the most susceptible to PLE (cats are less commonly affected), and will often display anorexia, weight loss, vomiting, and diarrhea. Interestingly, some patients may present with pleural or peritoneal effusion secondary to severe hypoalbuminemia, but may not exhibit primary signs of gastrointestinal disease, such as diarrhea or vomiting. Ascites and/or pleural effusion or subcutaneous edema can occur subsequent to hypoalbuminemia. Signs of thromboembolic disease, such as dyspnea due to pulmonary thromboembolism, can occur secondary to a lack of anti-thrombin III (AT-III).

**Diagnostics:** Typical laboratory abnormalities include hypoalbuminemia and/or hypoglobulinemia. If globulin levels are within normal limits, they are usually at the lower end of normal. Lymphocytes and cholesterol may be decreased, especially in cases of lymphangiectasia, due to a loss of lymphocytes and cholesterol in the lymph. A regenerative anemia can occur due to blood loss, although anemia due to iron deficiency may ensue in chronic cases. Hypocalcemia may transpire secondary to albumin loss (pseudohypocalcemia) or the calcium can be truly subnormal as a result of hypovitaminosis D due to PLE. Hypomagnesemia is common as well. Severe PLE can lead to a decline in AT-III levels, which can then result in a prothrombotic state. Thus, AT-III levels should be measured in severely hypoalbuminemic patients.

The clinician should consider ultrasound as a non-invasive method to help determine the cause of hypoalbuminemia. Ultrasound can be utilized to evaluate the GI tract, kidneys, liver, and adrenals. It will also help identify the potential sources of albumin loss (GI or renal), whether there is a lack of albumin production (liver), or if the condition is linked to hypoadrenocorticism (adrenal), which may also be associated with hypoalbuminemia (the ultrasound may reveal isoechoic flattened adrenals < 0.32 cm). These findings should also be considered in combination with a bile acid test to rule out hepatic insufficiency, a urine protein-creatinine (UPC) ratio to assess for urine protein loss, and a fecal Alpha 1-Proteinase Inhibitor test to assess for GI protein loss. An ACTH stimulation test may be indicated if hypoadrenocorticism is clinically suspected.

One should measure serum TLI, folate, and B<sub>12</sub> levels to evaluate for evidence of small intestinal bacteria overgrowth or to establish the presence of small intestinal disease due to cobalamin loss and elevated folate levels. The TLI will also confirm exocrine pancreatic insufficiency as a differential diagnosis for diarrhea and weight loss. A fecal exam should be submitted to rule out parasites.



**PATIENT**

Rocky Giampa

**SPECIES**

Canine

**BREED**

Poodle Cross

**SEX**

Neutered male

**AGE**

7 years

**WEIGHT**

26 lbs

**INTERPRETED BY**

Eric Lindquist, DMV,  
DABVP, Cert. IVUSS,  
CEO of SonoPath.com

**IMAGING PERFORMED BY**

Eric Lindquist, DMV,  
DABVP, Cert. IVUSS,  
CEO of SonoPath.com

**HOSPITAL NAME**

Franklin Lakes AH

**REFERRING VET**

Dr.  
Greenhut/Mastrascusa

**INVOICE**

71816

**DATE**

2/24/26

Sonographic abnormalities may include thickening of the intestinal wall and mucosal striations. One study has shown that the presence of mucosal striations has a sensitivity of 75% and specificity of 96% in dogs that have PLE; however, mucosal stippling appears to be a non-specific finding. Administration of corn oil (0.5-1 ml/kg) one hour prior to the ultrasound will enhance the visibility of mucosal striations in the small intestine during the sonogram. Solitary masses or focal intestinal thickening and lymphadenopathy can be evaluated, and sometimes fine needle aspiration (FNA) of a mass or enlarged lymph node may yield a diagnosis, especially in cases of lymphoma. If the results are inconclusive, then surgical biopsy should ideally be guided by an intraoperative ultrasound, especially if the lesions are focal. An ultrasound-guided core biopsy would only be considered if a bowel mass was large enough to biopsy the tissue without sampling through to the lumen, which could result in the leakage of bowel contents and subsequent peritonitis.

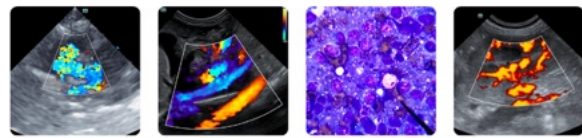
A definitive diagnosis of PLE can only be obtained via histopathology. This is preferably achieved with a surgically obtained full-thickness biopsy or an endoscopic-guided biopsy performed the morning after the patient has eaten a high-fat meal so that the lacteals are dilated and lymphangiectasia can be adequately diagnosed. There may be some increased risk to obtaining full-thickness biopsies in patients with severe hypoalbuminemia due to decreased healing and increased risk of dehiscence. Thus, the cost-benefit of full-thickness biopsy versus an endoscopic biopsy should be considered on a case-by-case basis.

Endoscopy should be performed using two approaches—via the stomach to biopsy the duodenum, and via the colon to biopsy the ileum—thereby maximizing the information one can yield from biopsy. Yet, transmural disease, such as lymphoma affecting the muscularis and submucosa, is not typically assessed very readily via endoscopy. A sonogram of the GI tract can help determine whether the pathology is luminal and thus available for sampling through endoscopy, or mural or serosal and therefore necessitating surgical biopsy.

**Treatment:** Therapy for PLE is dependent on the underlying disease process. Given that a significant fraction of PLE cases are the result of a food allergy causing IBD, whether or not lymphangiectasia is concurrent, dietary trials with a hydrolyzed protein diet or a novel protein diet are a good choice, especially if IBD has been confirmed on biopsy. If, however, severe lymphangiectasia has been diagnosed, a fat-restricted diet is preferred. In some cases, a specially formulated homemade diet may be most appropriate and should be determined in consultation with a veterinary nutritionist.

Empirical broad-spectrum deworming should be pursued using fenbendazole at 50 mg/kg PO Q24hr for 5 days; repeat in 2 weeks. Treating for small intestinal bacterial overgrowth can also be considered, especially if there is evidence of elevated folate levels. In such cases, one should administer metronidazole (15mg/kg PO BID) or tylosin (10-20 mg/kg PO BID).

If IBD has been confirmed, immunosuppressive therapy with prednisone should be administered at 2 mg/kg/day for a 2-4 week induction period. Subsequently, the patient should be weaned slowly to 1 mg/kg/day, and eventually dosed every other day. In large and giant breed dogs, dosing per body surface area is recommended to avoid overdosing and the precipitation of severe side effects; the recommended dose is 30-40mg/m<sup>2</sup> for large breed dogs. Concurrently administering azathioprine (Immunan) (2mg/kg PO Q24hr for 10 days, then 1 mg/kg PO Q24hr, and eventually every other day on alternate days to the prednisone; note that alternative protocols exist at a dose of 1-2 mg/kg PO Q24hr) can be considered if the patient is nonresponsive to prednisone alone. Cyclosporine is an alternative immunosuppressant; however, it can be quite expensive, especially in large dog breeds, and should be dosed at 3-5mg/kg PO Q12-24hr to start. Blood cyclosporine levels should be evaluated 7 days after initiating treatment; one can adjust the



**PATIENT**

Rocky Giampa

**SPECIES**

Canine

**BREED**

Poodle Cross

**SEX**

Neutered male

**AGE**

7 years

**WEIGHT**

26 lbs

**INTERPRETED BY**

Eric Lindquist, DMV,  
DABVP, Cert. IVUSS,  
CEO of SonoPath.com

**IMAGING PERFORMED BY**

Eric Lindquist, DMV,  
DABVP, Cert. IVUSS,  
CEO of SonoPath.com

**HOSPITAL NAME**

Franklin Lakes AH

**REFERRING VET**

Dr.  
Greenhut/Mastrascusa

**INVOICE**

71816

**DATE**

2/24/26

dosage at that point if need be. Concomitant use of ketoconazole (2.5-5 mg/kg PO BID) inhibits some metabolism of cyclosporine, leading to higher blood concentrations of the latter without increasing the overall dose (or cost to the owner). Typically, the dose of cyclosporine can be cut in half when dosed in conjunction with ketoconazole.

In the presence of effusions, colloid therapy may be beneficial and can include hetastarch at 10-20 ml/kg, which can be given as an initial bolus and the rest over 4-6 hours, or, alternatively, over a 24-hour period as a CRI (1-2 ml/kg/hr; do not to exceed 20 ml/kg/24 hours). Fresh frozen plasma is typically ineffective at raising albumin levels; however, in an emergency situation, one can give it at 10-20 ml/kg IV over 3-4 hours. Human albumin is more effective at raising serum albumin levels; it also helps provide oncotic support during diagnostic procedures, such as obtaining biopsies, for example. Repeat administration can result in anaphylactic reactions, but that outcome is rare.

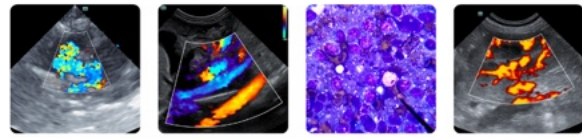
Diuretics can be utilized in the face of severe ascites, but they are not particularly effective. Spironolactone is preferred (2 mg/kg PO BID) and low-dose lasix can be added if necessary (1-2 mg/kg PO BID). Abdominocentesis should only be pursued if the patient is experiencing discomfort due to exaggerated abdominal distention. Excessive drainage will cause further depletion of the protein supply, which runs counter to restoring balanced protein levels and can also often result in rapid fluid shifts, leading to acute hypovolemia and hypotension.

Anticoagulant therapy is suggested in the face of severe hypoalbuminemia (less than 1.5 g/dl). Therapeutic options include clodiprogel (2 mg/kg PO Q24hr) or aspirin (1 mg/kg PO Q24hr) in the hopes of preventing a potential thromboembolic episode, which can be the source of sudden death in cases of significant hypoalbuminemia in which there has been AT-III loss.

Patients should be supplemented with cobalamin (vitamin B<sub>12</sub>) at 25-50 ug/kg once weekly for 4-6 weeks, then once every other week to once a month as needed.

If ionized calcium levels are decreased with corresponding clinical signs of hypocalcemia, calcium levels should be corrected with parenteral calcium gluconate (50-150 mg/kg IV over 12-24 hours). Long-term supplementation may be necessary for dogs suffering from concurrent hypovitaminosis D, secondary to IBD; this would entail administering calcitriol as well as oral calcium (calcium carbonate). In the face of hypomagnesiemia, magnesium sulphate (1mEq/kg/day IV) or magnesium oxide 10-20 mg/kg PO BID (milk of magnesia) may be utilized for magnesium supplementation; however, the latter may cause diarrhea.

**Conclusion:** PLE can be a challenging disease syndrome to treat given the multiple possible underlying etiologies and the severity of clinical sequelae characteristic of severe hypoalbuminemia. It is important, if possible, to obtain a definitive diagnosis, and addressing all potential comorbid issues is crucial to the success of its management. Dietary therapy is an important factor in long-term treatment as is attending to the underlying cause of the disease.



**PATIENT**

Rocky Giampa

**SPECIES**

Canine

**BREED**

Poodle Cross

**SEX**

Neutered male

**AGE**

7 years

**WEIGHT**

26 lbs

**INTERPRETED BY**

Eric Lindquist, DMV,  
 DABVP, Cert. IVUSS,  
 CEO of SonoPath.com

**IMAGING PERFORMED BY**

Eric Lindquist, DMV,  
 DABVP, Cert. IVUSS,  
 CEO of SonoPath.com

**HOSPITAL NAME**

Franklin Lakes AH

**REFERRING VET**

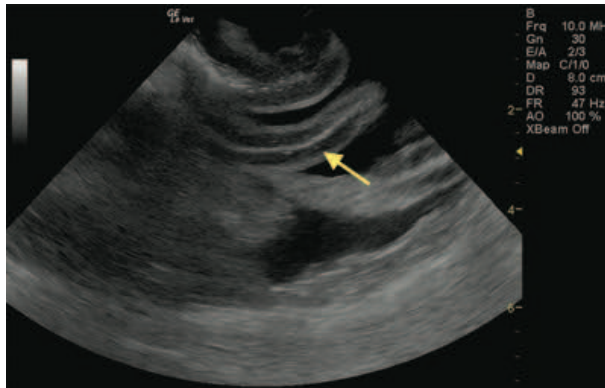
Dr.  
 Greenhut/Mastrascusa

**INVOICE**

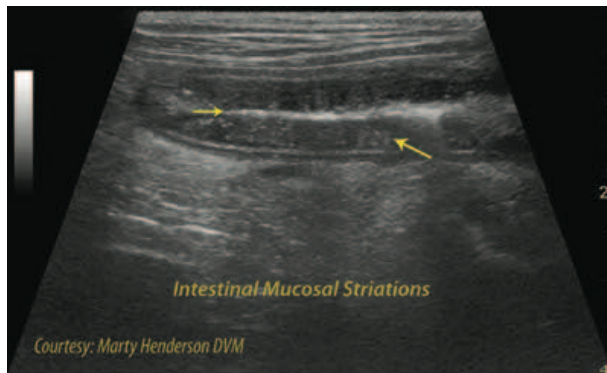
71816

**DATE**

2/24/26



Small intestine of a dog with protein losing enteropathy. A moderate amount of anechoic peritoneal effusion is present as sequel to the hypoalbuminemia (albumin < 1.5 g/dl). Note the generalized increased mucosal echogenicity and presence of multiple echogenic foci (arrow) throughout the small intestinal mucosa compatible with dilated lacteals. When these foci are scanned with standard scanning frequency (8 mHz), then high resolution linear probe should be employed for further investigation of the mucosae and GI wall similar to the title image or the following one.



Long axis of the jejunum in a dog with protein losing enteropathy. Note the multiple vertical hyperechoic mucosal striations (long arrow) pathognomonic for lacteal dilation. Also note the presence of a hyperechoic line (small arrow) within the mucosa parallel to the submucosa in the small intestine consistent with a dilated draining lymph vessel. A small amount of anechoic effusion is seen.

**References:**

Dossin O, Lavoué R. Protein-losing enteropathies in dogs. *Vet Clin North Am Small Anim Pract* 2011;41(2):399-418.

Gaschen L, Kircher P, Stüssi A, et al. Comparison of ultrasonographic findings with clinical activity index (CIBIDAI) and diagnosis in dogs with chronic enteropathies. *Vet Radiol Ultrasound* 2008;49(1):56-64.

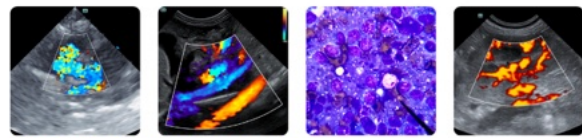
Gow AGG, Else R, Evans H, et al. Hypovitaminosis D in dogs with inflammatory bowel disease and hypoalbuminemia. *J Small Anim Pract* 2011;52(8):411-18.

Hill SL. Diagnosis of protein-losing enteropathies. Proceedings from the American College of Veterinary Internal Medicine, Seattle, WA, June 4-7, 2013.

Kimmel SE, Waddell LS, Michel KE. Hypomagnesemia and hypocalcemia associated with protein losing enteropathy in Yorkshire terriers: five cases (1992-1998). *J Am Vet Med Assoc* 2000;217(5):703-6.

Lindquist E, Casey D, Frank J. Intraoperative ultrasound for precise biopsy and resection of transabdominally detected intestinal lesions in 3 cats. Proceedings from the European College of Veterinary Internal Medicine, Porto, Portugal, September 8-10, 2009.

Littier R. Protein losing enteropathy: causes, clinical signs and diagnosis. *In Pract* 2013;35(7):373-81.



**PATIENT**

Rocky Giampa

Littman MP, Dambach DM, Vaden SL, Giger U. Familial protein-losing enteropathy and protein-losing nephropathy in Soft Coated Wheaten Terriers: 222 cases (1983-1997). *J Vet Intern Med* 2000;14(1):68-80.

**SPECIES**

Canine

Lobetti R, Lindquist E, Frank J, et al. Adrenal gland ultrasonography in dogs with hypoadrenocorticism. Proceedings from the American College of Veterinary Internal Medicine, Seattle, WA, June 4-7, 2013.

**BREED**

Poodle Cross

Neiger R. Protein-losing enteropathy (PLE) in dogs. Proceedings from the World Small Animal Veterinary Association Congress, Auckland, New Zealand, March 6-9, 2013.

**SEX**

Neutered male

Pollard RE, Johnson EG, Pesavento PA, et al. Effects of corn oil administered orally on conspicuity of ultrasonographic small intestinal lesions in dogs with lymphangiectasia. *Vet Radiol Ultrasound* 2013;54(4):390-97.

**AGE**

7 years

Rodríguez-Alarcón C, Beristáin-Ruiz D, Pérez-Casio F, et al. Protein-losing enteropathy in a dog with lymphangiectasia, lymphoplasmacytic enteritis and pancreatic exocrine insufficiency. *Vet Q* 2012;32(3-4):193-97.

**WEIGHT**

26 lbs

Valerie J Parker, Lisa M Freeman. Nutritional management of protein-losing nephropathy in dogs. *Compend Contin Educ Pract Vet* 2012;34(7):1-5.

**INTERPRETED BY**

Eric Lindquist, DMV,  
DABVP, Cert. IVUSS,  
CEO of SonoPath.com

Wenger M, Mueller C, Kook PH, Reusch CE. Ultrasonographic evaluation of adrenal glands in dogs with primary hypoadrenocorticism or mimicking diseases. *Vet Rec* 2010;167(6):207-10.

Willard MD. Protein-losing enteropathies: not what you might expect. Proceedings from the American College of Veterinary Internal Medicine, Seattle, WA, June 4-7, 2013.

**IMAGING PERFORMED BY**

Eric Lindquist, DMV,  
DABVP, Cert. IVUSS,  
CEO of SonoPath.com

**HOSPITAL NAME**

Franklin Lakes AH

**REFERRING VET**

Dr.  
Greenhut/Mastrascusa

**INVOICE**

71816

**DATE**

2/24/26