



## PATIENT

Ollie Cecil

## SPECIES

Canine

## BREED

Shih Tzu Mix

## SEX

Neutered male

## AGE

8 years

## WEIGHT

14.1 lbs

## INTERPRETED BY

Eric Lindquist, DMV,  
DABVP (CFM), Cert.  
IVUSS, CEO of  
SonoPath.com

## IMAGING PERFORMED BY

Chloe Lowe

## HOSPITAL NAME

All Creatures Great  
and Small Fairfield

## REFERRING VET

Dr. Perez

## INVOICE

71757

## DATE

2/18/26

## PRESENTING CLINICAL SIGNS

- Increased ALT (122) and ALP (741) likely due to pred
- Allergies
- apoquel and pred

## ULTRASONOGRAPHIC EXAMINATION OF THE ABDOMEN

### *Urinary System*

The **urinary bladder**, trigone, and pelvic urethra presented normal thicknesses and normal tone. The ureters were not visible which is normal. No uroliths or sediment were visualized and anechoic urine was present. No evidence of inflammatory or neoplastic changes was noted. Ureteral papillae were normal.

The **kidneys** revealed normal size and structure, corticomedullary definition and ratio for this age. The cortices presented largely uniform texture with normal echogenic relationship to liver and spleen. Medullary structure differed distinctly from the cortex and no evidence of pelvic dilation was present. The capsules were acceptably uniform without significant irregularities. The left kidney measured 4.27 cm. The right kidney measured 4.3 cm.

### *Adrenal Glands*

Both **adrenal glands** were visualized and recognized as having normal shape, size, position and echogenicity for this breed. The phrenic vasculature, glandular echogenicity and detail were unremarkable. Capsule, cortex, and medullary definition were normal for this age patient. The right adrenal gland measured 1.68 x 0.48 cm at the cranial pole and 0.47 cm at the caudal pole. The left adrenal gland measured 1.35 x 0.5 cm.

### *Spleen*

The **spleen** presented a smooth homogeneous parenchyma hyperechoic to liver and renal cortical parenchyma. The capsule was smooth without noticeable expansion or deviation from within the spleen or adjacent pathology. The splenic vasculature demonstrated normal volume without signs of congestion or thrombosis. No sonographic evidence of acute or chronic inflammatory, neoplastic, or infarctual changes was noted.

### *Liver*

The **liver** images from right and left intercostal as well as subcostal views revealed subjectively normal liver size, contour, and structure. Some age-related parenchymal remodeling was noted but likely not clinically significant at this time. Vascular and biliary tracts were of normal volume and no evidence of congestion was noted. The gallbladder presented some dependent debris with essentially normal contour. The cystic and common bile ducts were normal. No overt evidence of active inflammatory, infiltrative or regenerative pathology was noted but should be paired with current or past LE elevations regarding any clinical significance to this presentation. The hepatic lymph nodes were unremarkable.



**PATIENT**

Ollie Cecil

**SPECIES**

Canine

**BREED**

Shih Tzu Mix

**SEX**

Neutered male

**AGE**

8 years

**WEIGHT**

14.1 lbs

**INTERPRETED BY**

Eric Lindquist, DMV,  
 DABVP (CFM), Cert.  
 IVUSS, CEO of  
 SonoPath.com

**IMAGING PERFORMED BY**

Chloe Lowe

**HOSPITAL NAME**

All Creatures Great  
 and Small Fairfield

**REFERRING VET**

Dr. Perez

**INVOICE**

71757

**DATE**

2/18/26

**Gastrointestinal**

Examination of the **gastrointestinal tract** revealed a stomach and intestine free of stasis, of normal wall thickness, acceptable curvilinear mural detail, and peristaltic activity. Small and large intestine demonstrated normal luminal chyme and stool consistency respectively. No obstructive or overt infiltrative disease was noted. No associated abnormal lymphatic activity was noted.

**Pancreas**

The base and limbs of the **pancreas** were observed to be largely isoechoic to surrounding omental fat. Pancreatic duct and capsular contour were acceptably normal and parenchyma respected normal curvilinear patterns. No overt evidence of active inflammatory or neoplastic disease was noted.

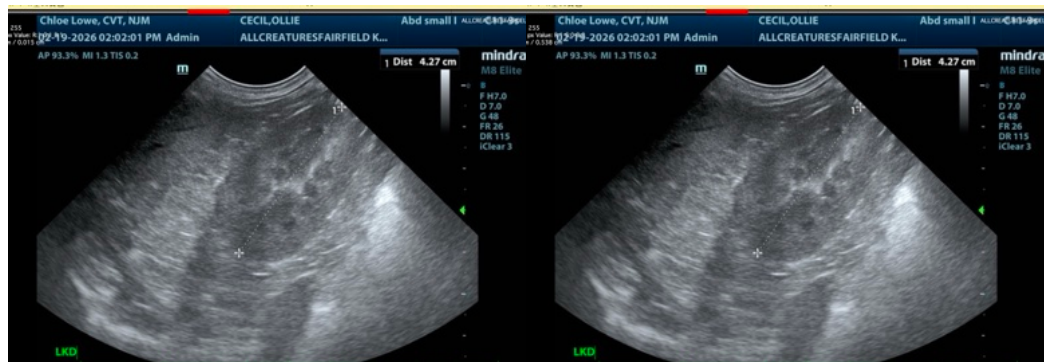
**ULTRASONOGRAPHIC FINDINGS**

Structurally unremarkable abdomen.

Benign hepatopathy.

**INTERPRETATION OF THE FINDINGS & FURTHER RECOMMENDATIONS**

There was no evidence of visceral pathology. There is no contraindication to anesthetic procedure if necessary.





**PATIENT**

Ollie Cecil

**SPECIES**

Canine

**BREED**

Shih Tzu Mix

**SEX**

Neutered male

**AGE**

8 years

**WEIGHT**

14.1 lbs

**INTERPRETED BY**

Eric Lindquist, DMV,  
 DABVP (CFM), Cert.  
 IVUSS, CEO of  
 SonoPath.com

**IMAGING PERFORMED BY**

Chloe Lowe

**HOSPITAL NAME**

All Creatures Great  
 and Small Fairfield

**REFERRING VET**

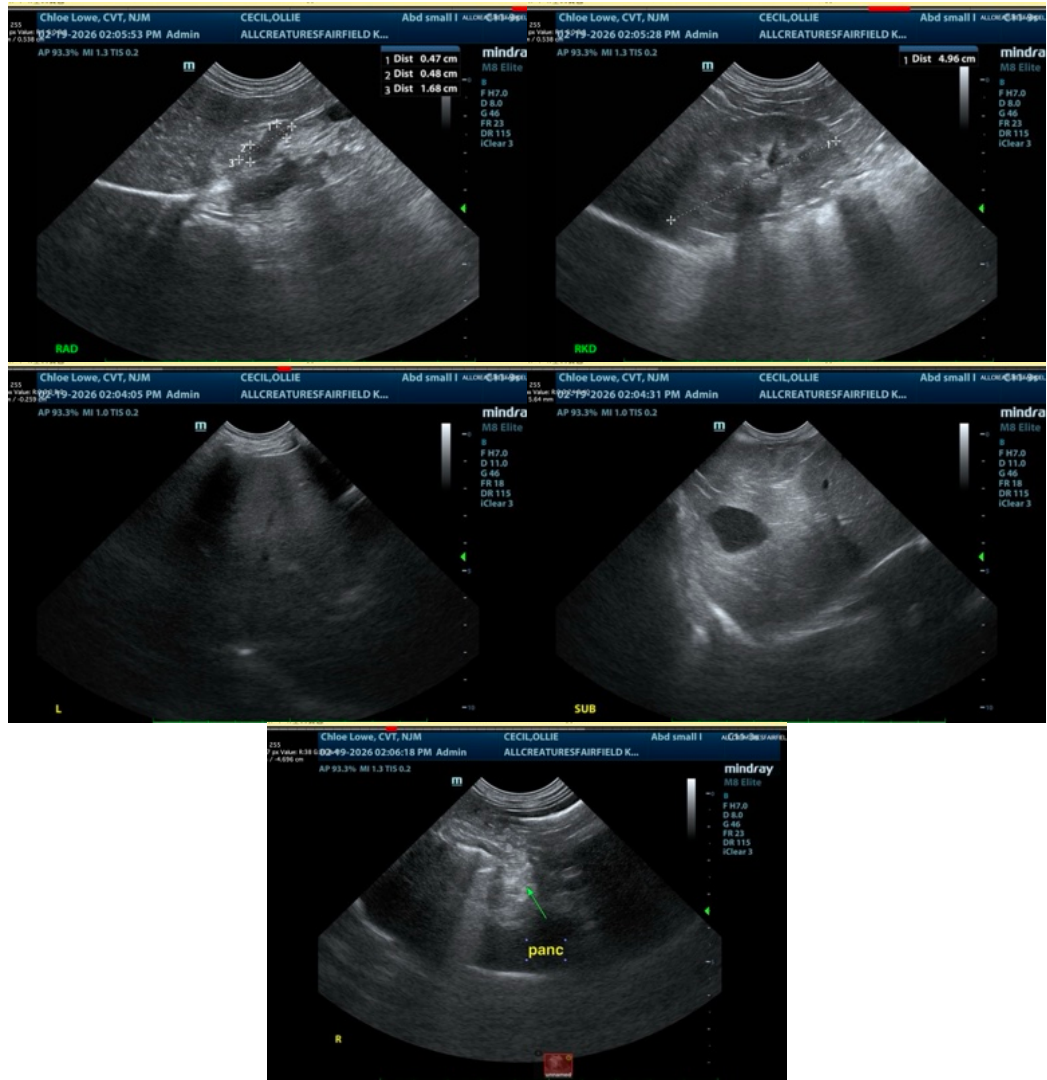
Dr. Perez

**INVOICE**

71757

**DATE**

2/18/26



The information and recommendations provided are based on the images presented by the referring veterinarian/sonographer. No evaluation can be communicated regarding pathology that was not visible in the image/video clips provided.

Thank you for this referral. If the clinical or image interpretation does not parallel your findings or if I can be of any further assistance please contact me.

Eric Lindquist, DMV, DABVP (CFM), Cert. IVUSS, CEO of SonoPath.com

Info@SonoPath.com