



PATIENT

Havana Chapman

SPECIES

Canine

BREED

Bichon Mix

SEX

Spayed female

AGE

1 year

WEIGHT

-

INTERPRETED BY

Eric Lindquist, DMV,
DABVP, Cert. IVUSS,
CEO of SonoPath.com

IMAGING PERFORMED BY

Shari Reffi, CVT

HOSPITAL NAME

Brodheads ville VC

REFERRING VET

Dr. Dollinsky

INVOICE

71714

DATE

2/19/26

PRESENTING CLINICAL SIGNS

- Lethargic, hyporexic, not drinking.
- Rectal temp 102
- CRT 3-4 seconds
- Pain on abdomen palp
- Ana (+) historic

ULTRASONOGRAPHIC EXAMINATION OF THE ABDOMEN

Urinary System

The **urinary bladder**, trigone, and pelvic urethra presented normal thicknesses and normal tone. The pelvic urethra was imaged 2.0 cm beyond the cystourethral junction and appeared normal. The ureters were not visible which is normal. No uroliths or sediment were visualized and anechoic urine was present. No evidence of inflammatory or neoplastic changes was noted. Ureteral papillae were normal.

The **kidneys** revealed normal size and structure, corticomedullary definition and ratio for this age. The cortices presented largely uniform texture with normal echogenic relationship to liver and spleen. Medullary structure differed distinctly from the cortex and no evidence of pelvic dilation was present. The capsules were acceptably uniform without significant irregularities. The left kidney measured 4.28 cm. The right kidney measured 5.6 cm.

Adrenal Glands

Both **adrenal glands** were visualized and recognized as having normal shape, size, position and echogenicity for this breed. The phrenic vasculature, glandular echogenicity and detail were unremarkable. Capsule, cortex, and medullary definition were normal for this age patient. The right adrenal gland measured 0.45 cm at the caudal pole and 0.49 cm at the cranial pole. The left adrenal gland measured 0.42 cm at the caudal pole and 0.38 cm at the cranial pole.

Spleen

The **spleen** presented a smooth homogeneous parenchyma hyperechoic to liver and renal cortical parenchyma. The capsule was smooth without noticeable expansion or deviation from within the spleen or adjacent pathology. The splenic vasculature demonstrated normal volume without signs of congestion or thrombosis. No sonographic evidence of acute or chronic inflammatory, neoplastic, or infarctual changes was noted.

Liver

The **liver** images submitted revealed subjectively normal liver size, contour, and structure. Parenchymal echogenicity was naturally coarse and hypoechoic to the spleen. Vascular and biliary tracts were of normal volume with no evidence of congestion. The gallbladder presented acceptably thin walls with primarily anechoic content. The cystic and common bile ducts were normal. No pathological hepatic



PATIENT

Havana Chapman

lymphadenopathy was evident. No overt structural evidence of inflammatory, infiltrative or regenerative pathology was evident.

SPECIES

Canine

Gastrointestinal

Examination of the **gastrointestinal tract** revealed an unremarkable stomach and small intestine regarding structure. There were minor areas of luminal fluid noted. The pylorus was empty. There was no evidence of obstructive pattern. Curvilinear patterns were retained throughout the gastrointestinal tract. Areas of hyperperistalsis were noted. This is consistent with response to irritation. The colon was unremarkable.

BREED

Bichon Mix

SEX

Spayed female

Pancreas

The **pancreas** was hypoechoic, irregular, mildly enlarged and edematous primarily in the right pancreatic base.

AGE

1 year

WEIGHT

-

ULTRASONOGRAPHIC FINDINGS

Non-specific gastroenteritis pattern.

INTERPRETED BY

Eric Lindquist, DMV,
DABVP, Cert. IVUSS,
CEO of SonoPath.com

Pancreatitis pattern.

INTERPRETATION OF THE FINDINGS & FURTHER RECOMMENDATIONS

There was no evidence of foreign body. Medical management should prove effective. 24-hour n.p.o., IV fluid support, GI protectants and pain management is indicated.

IMAGING PERFORMED BY

Shari Reffi, CVT

HOSPITAL NAME

Brodheads ville VC

REFERRING VET

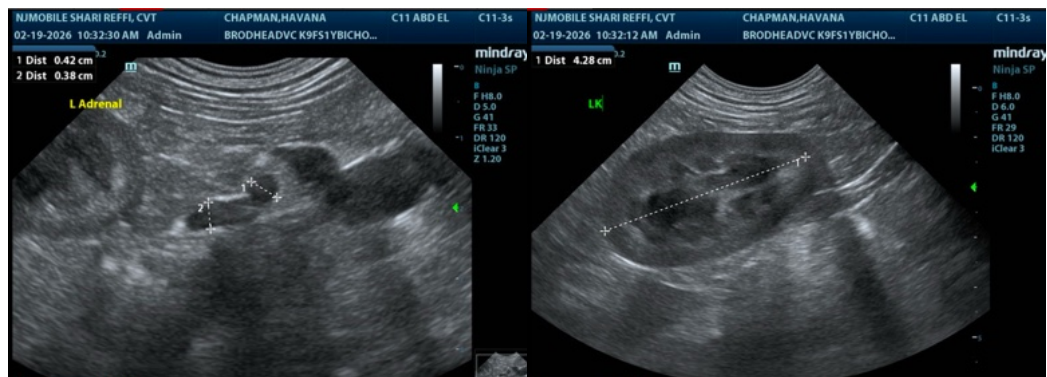
Dr. Dollinsky

INVOICE

71714

DATE

2/19/26





PATIENT

Havana Chapman

SPECIES

Canine

BREED

Bichon Mix

SEX

Spayed female

AGE

1 year

WEIGHT

-

INTERPRETED BY

Eric Lindquist, DMV,
 DABVP, Cert. IVUSS,
 CEO of SonoPath.com

IMAGING PERFORMED BY

Shari Reffi, CVT

HOSPITAL NAME

Brodheads ville VC

REFERRING VET

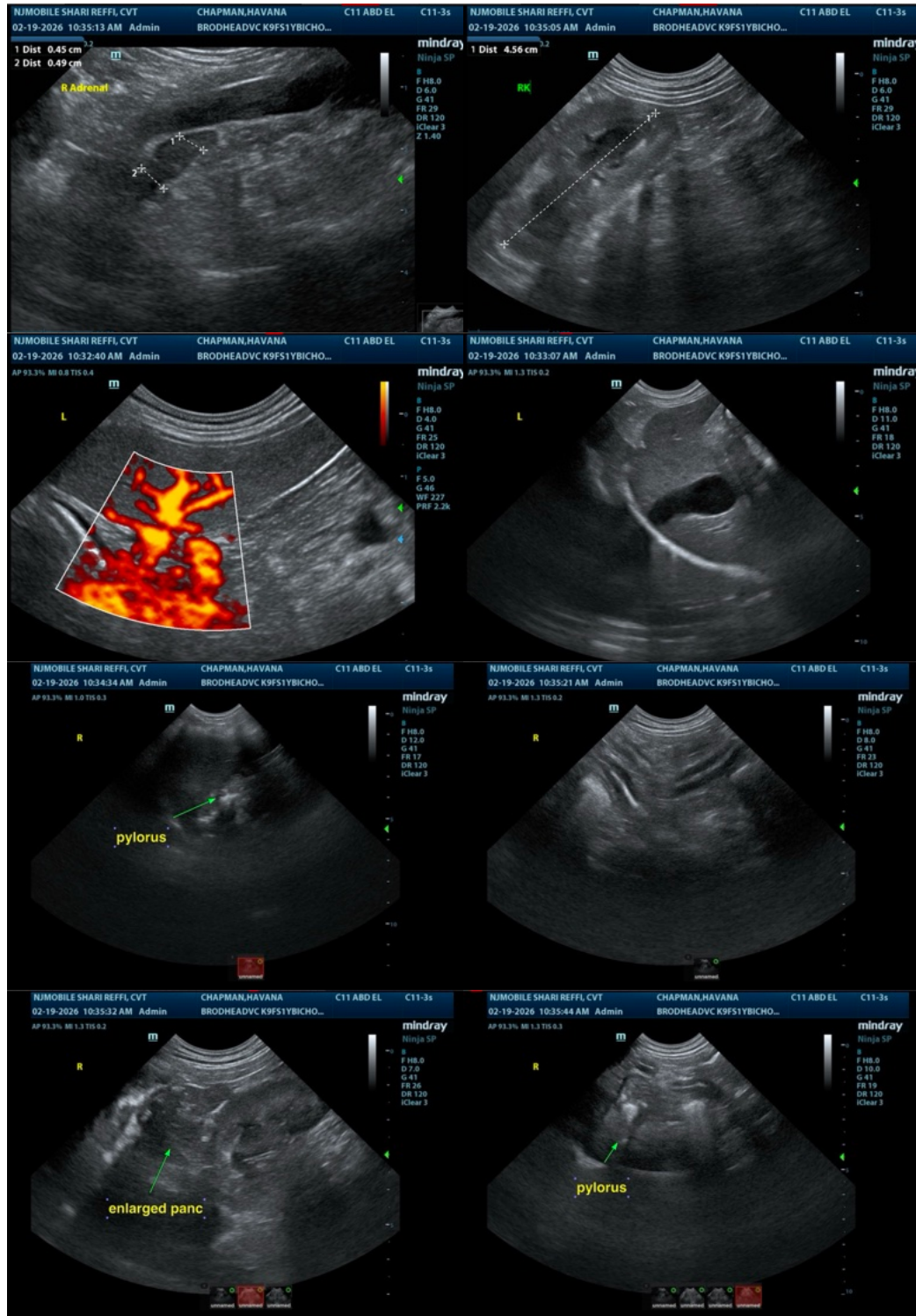
Dr. Dollinsky

INVOICE

71714

DATE

2/19/26





PATIENT

Havana Chapman

SPECIES

Canine

BREED

Bichon Mix

SEX

Spayed female

AGE

1 year

WEIGHT

-

INTERPRETED BY

Eric Lindquist, DMV,
DABVP, Cert. IVUSS,
CEO of SonoPath.com

IMAGING PERFORMED BY

Shari Reffi, CVT

HOSPITAL NAME

Brodheads ville VC

REFERRING VET

Dr. Dollinsky

INVOICE

71714

DATE

2/19/26

The information and recommendations provided are based on the images presented by the referring veterinarian/sonographer. No evaluation can be communicated regarding pathology that was not visible in the image/video clips provided.

Thank you for this referral. If the clinical or image interpretation does not parallel your findings or if I can be of any further assistance please contact me.

Eric Lindquist, DMV, DABVP, Cert. IVUSS, CEO of SonoPath.com

Info@SonoPath.com