



PATIENT

Charlie Fusco

SPECIES

Canine

BREED

Minature Schnauzer

SEX

Neutered male

AGE

10 years

WEIGHT

22.6 lbs

INTERPRETED BY

Eric Lindquist, DMV,
 DABVP, Cert. IVUSS,
 CEO of SonoPath.com

IMAGING PERFORMED BY

Meghan Morse, LVT,
 CVT

HOSPITAL NAME

Rondout Valley VA

REFERRING VET

Dr. Hexter

INVOICE

71703

DATE

2/18/26

PRESENTING CLINICAL SIGNS

- Cardiac evaluation for acquired asymptomatic 3/6 HM
- PMI L apex
- Current meds: Apoquel

ULTRASONOGRAPHIC EXAMINATION OF THE HEART

The echocardiogram in this patient demonstrated normal **left atrial** size based on 3 different LA measurement methods. Chamber volumes and echogenicity were normal. The cranial and caudal **mitral** valve leaflets presented vegetative thickening consistent with endocardiosis. Trace mitral valve prolapse was noted at the anterior leaflet. Doppler indicated measurable insufficiency. The **left ventricle** presented thicknesses with linear contour and was not dilated nor restricted. The **myocardium** presented normal echogenicity without subjective evidence of significant fibrotic or ischemic disease. **Contractility** of the ventricular walls was adequate and in normal range for this patient evidenced by the fractional shortening measurement and subjective evaluation of the different regions of the myocardium. The **left ventricular outflow** tract demonstrated normal laminar flow and subjective structural integrity. The **right atrium** and auricle revealed normal size, structure and content. No evidence of masses was noted or chamber overload. **Tricuspid** valvular assessment demonstrated adequate linear morphology. The **right ventricle** was of normal size (1/3 diameter of LV), chordae structure, myocardial echogenicity and thickness. **Pulmonic** tract assessment revealed normal valve structure, laminar flow, and diameter (approx. 1:1 pa/ao ratio). No visible **pericardial** or free pleura fluid was noted. No echographically detectable evidence of infiltrative disease was visible. The cranial **mediastinum and pericardial regions** were free of masses in the visible window.

E Wave Velocity 0.9 m/sec

CANINE CARDIAC PARAMETERS	MR VMAX (m/s)	TR VMAX (m/s)	LA/AO	LA/AO (Heart Base)	FS (%)	EF (%)	EPSS (cm)
NORMAL PARAMETER	4.5-5.5	<2.7	1.3	<1.6	28-40	40-100	<0.6
PATIENT	6.0	-	1.3	1.55	56	88	0.1
CANINE CARDIAC PARAMETERS	HR (BPM)	AV VMAX (m/s)	PV MAX (m/s)	BODY WEIGHT	LA 2D short axis Base view (cm)	LVIDd Avg; 2D and m-mode short axis (cm)	LVIDs Avg; 2D and m-mode short axis (cm)
NORMAL PARAMETER	50-100	0.7-1.7	0.7-1.6	BELOW	BELOW	BELOW	BELOW
PATIENT	110	1.8	1.01	22.6 lbs	3.5	3.3	

ULTRASONOGRAPHIC FINDINGS

Stage B1 valvular disease with slight prolapse, compensated.



PATIENT

Charlie Fusco

SPECIES

Canine

BREED

Miniature Schnauzer

SEX

Neutered male

AGE

10 years

WEIGHT

22.6 lbs

INTERPRETED BY

Eric Lindquist, DMV,
 DABVP, Cert. IVUSS,
 CEO of SonoPath.com

IMAGING PERFORMED BY

Meghan Morse, LVT,
 CVT

HOSPITAL NAME

Rondout Valley VA

REFERRING VET

Dr. Hexter

INVOICE

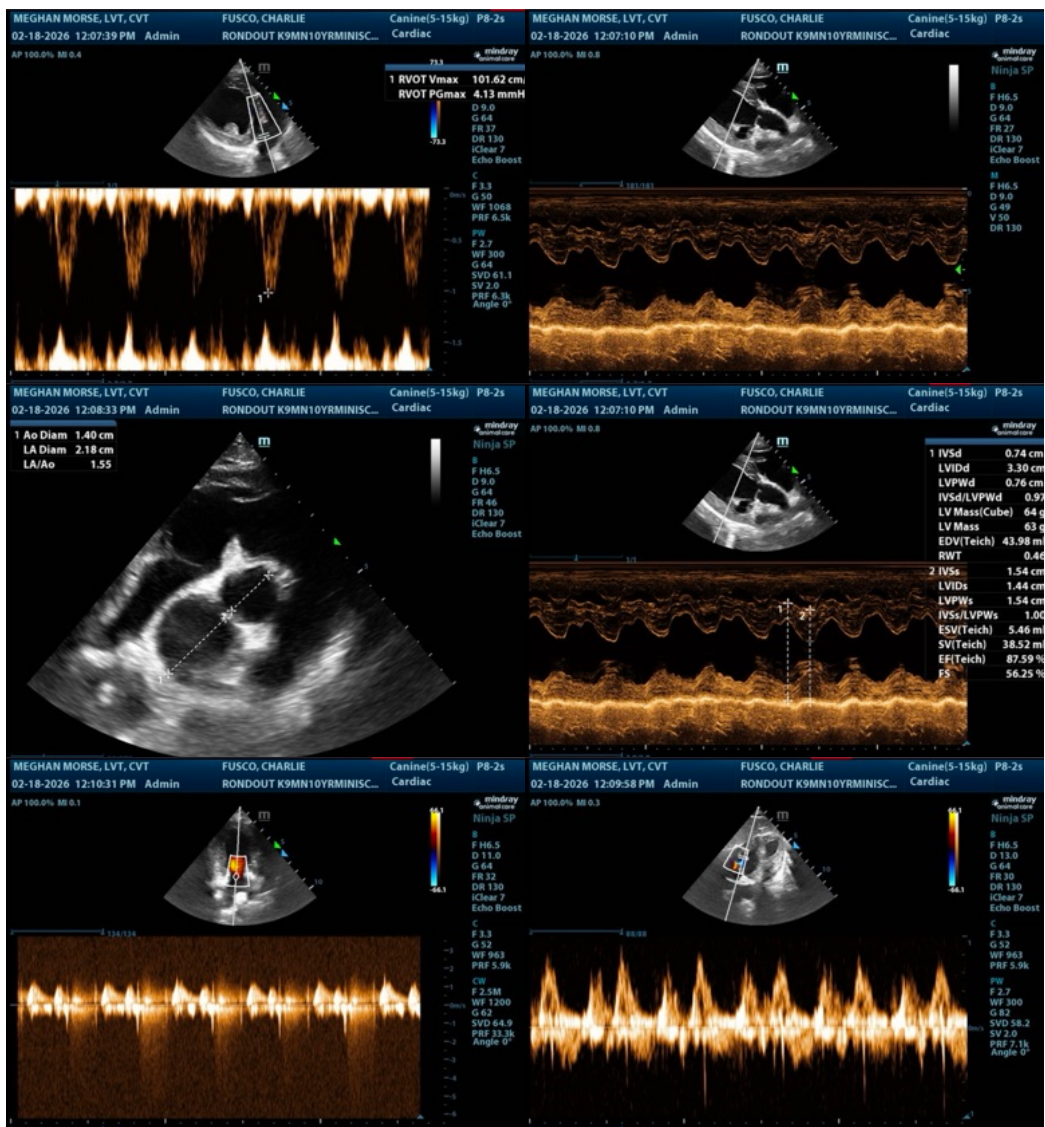
71703

DATE

2/18/26

INTERPRETATION OF THE FINDINGS & FURTHER RECOMMENDATIONS

The heart is stable without clinical disease. No overt contraindication for anesthesia of brief to moderate duration. I suggest Torbutrol premed, Propofol induction, Isoflor maintenance or similar protocol if anesthesia is desired. Blood pressure recommended if not already performed and target white coat negative systolic pressure of < 160 mmHg. If higher than this ACE-inhibitor is suggested to reach this level. Recheck echocardiogram is recommended in 6 months, earlier if murmur grade increases or clinical signs initiate.





PATIENT

Charlie Fusco

SPECIES

Canine

BREED

Miniature Schnauzer

SEX

Neutered male

AGE

10 years

WEIGHT

22.6 lbs

INTERPRETED BY

Eric Lindquist, DMV,
 DABVP, Cert. IVUSS,
 CEO of SonoPath.com

IMAGING PERFORMED BY

Meghan Morse, LVT,
 CVT

HOSPITAL NAME

Rondout Valley VA

REFERRING VET

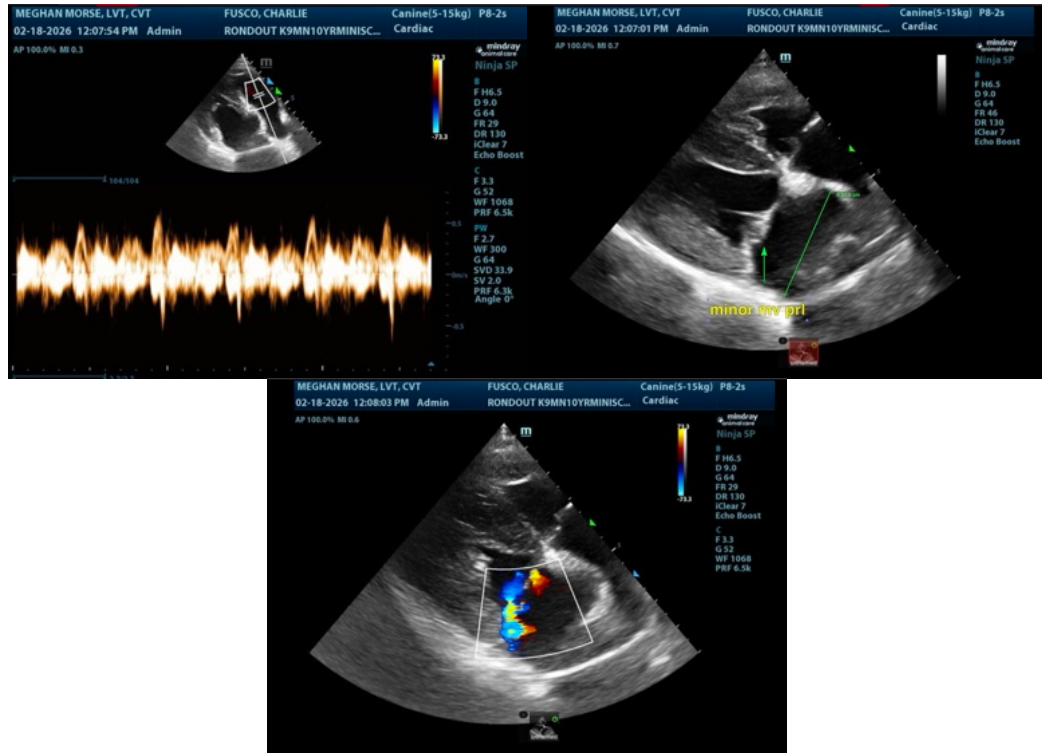
Dr. Hexter

INVOICE

71703

DATE

2/18/26



The information and recommendations provided are based on the images presented by the referring veterinarian/sonographer. No evaluation can be communicated regarding pathology that was not visible in the image/video clips provided.

Thank you for this referral. If the clinical or image interpretation does not parallel your findings or if I can be of any further assistance please contact me.

Eric Lindquist, DMV, DABVP, Cert. IVUSS, CEO of SonoPath.com

Info@SonoPath.com