



PATIENT

Louie Ortega

SPECIES

Canine

BREED

Shih Tzu

SEX

Neutered male

AGE

11 years

WEIGHT

5.7 kgs

INTERPRETED BY

Eric Lindquist, DMV
DABVP, Cert. IVUSS

IMAGING PERFORMED BY

Rebecca Hamilton

HOSPITAL NAME

Bond Vet Edgewater

REFERRING VET

Dr. Odronez

INVOICE

71638

DATE

2/17/26

PRESENTING CLINICAL SIGNS

- Regression of perineal hernia
- hx of perineal hernia X 3 times Sx correction, no evident signs of herniation noted but radiographs indicated potential regressing

ULTRASONOGRAPHIC EXAMINATION OF THE ABDOMEN

Urinary System

The **urinary bladder**, trigone, and pelvic urethra presented normal thicknesses and normal tone. The ureters were not visible which is normal. No uroliths or sediment were visualized and anechoic urine was present. No evidence of inflammatory or neoplastic changes was noted. Ureteral papillae were normal.

The **kidneys** revealed largely normal size and structure, corticomedullary definition and ratio (cortex 1/3 of medulla) were essentially maintained with some age-related loss of curvilinear patterns regarding the capsule and C/M junction. The cortices presented largely uniform texture with some increased echogenicity expected for this age patient. Medullary structure differed distinctly from that of the cortex and no evidence of pelvic dilation was present. Slight pinpoint mineralization was noted. The right kidney measured 3.7 cm. The left kidney measured 3.92 cm.

Adrenal Glands

Both **adrenal glands** were visualized and recognized as having normal shape, size, position and echogenicity for this breed. The phrenic vasculature, glandular echogenicity and detail were unremarkable. Capsule, cortex, and medullary definition were normal for this age patient. The left adrenal gland measured 1.33 x 0.41 cm at the cranial pole and 0.59 cm at the caudal pole. The right adrenal gland measured 1.32 x 0.72 cm at the cranial pole and 0.48 cm at the caudal pole.

Spleen

The **spleen** presented a smooth homogeneous parenchyma hyperechoic to liver and renal cortical parenchyma. The capsule was smooth without noticeable expansion or deviation from within the spleen or adjacent pathology. The splenic vasculature demonstrated normal volume without signs of congestion or thrombosis. No sonographic evidence of acute or chronic inflammatory, neoplastic, or infarctual changes was noted.

Liver

The **liver** images from right and left intercostal as well as subcostal views revealed subjectively normal liver size, contour, and structure. Some age-related parenchymal remodeling was noted but likely not clinically significant at this time. Vascular and biliary tracts were of normal volume and no evidence of congestion was noted. The gallbladder presented some dependent debris with essentially normal contour. The cystic and common bile ducts were normal. No overt evidence of active inflammatory,



PATIENT

Louie Ortega

SPECIES

Canine

BREED

Shih Tzu

SEX

Neutered male

AGE

11 years

WEIGHT

5.7 kgs

INTERPRETED BY

Eric Lindquist, DMV
 DABVP, Cert. IVUSS

IMAGING PERFORMED BY

Rebecca Hamilton

HOSPITAL NAME

Bond Vet Edgewater

REFERRING VET

Dr. Odronez

INVOICE

71638

DATE

2/17/26

infiltrative or regenerative pathology was noted but should be paired with current or past LE elevations regarding any clinical significance to this presentation. The hepatic lymph nodes were unremarkable.

Gastrointestinal

Examination of the **gastrointestinal tract** revealed a stomach and intestine free of stasis, of normal wall thickness, acceptable curvilinear mural detail, and peristaltic activity. Small and large intestine demonstrated normal luminal chyme and stool consistency respectively. The descending colon was unremarkable. 1.2 cm wide x 1.82 cm long extrusion of the colon appears to be present in the perineal region. This is consistent with regressing perineal hernia. This would likely change depending upon the content of the colon at any given time.

Pancreas

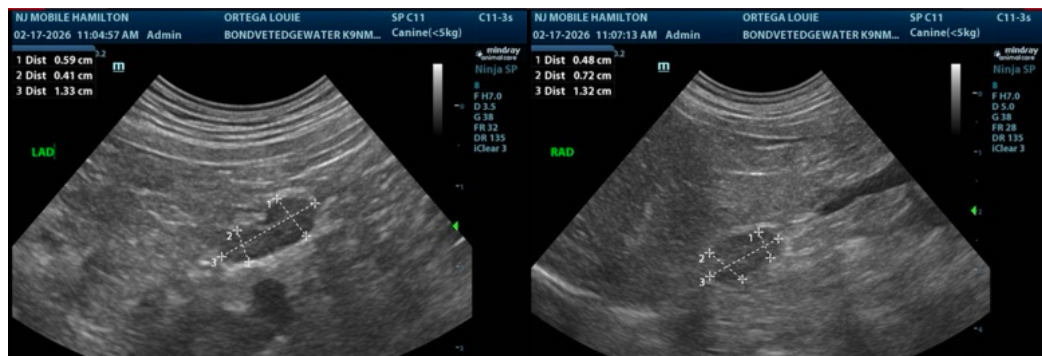
The base and limbs of the **pancreas** were observed to be largely isoechoic to surrounding omental fat. Some parenchymal remodeling, however, with mild deviation from curvilinear normalcy was observed. Pancreatic duct and capsular irregularities were present consistent with age related changes. If pain upon imaging (+ Murphy sign) was present or if the patient is focally painful in subxiphoid palpation then low-grade smoldering chronic pancreatitis should be suspected.

ULTRASONOGRAPHIC FINDINGS

Partial regression of perineal hernia.
 Otherwise, unremarkable abdomen.

INTERPRETATION OF THE FINDINGS & FURTHER RECOMMENDATIONS

Barium enema would be recommended for further definition or pelvic CT. Surgical consult is recommended. There was no evidence of anal gland pathology.





PATIENT

Louie Ortega

SPECIES

Canine

BREED

Shih Tzu

SEX

Neutered male

AGE

11 years

WEIGHT

5.7 kgs

INTERPRETED BY

Eric Lindquist, DMV
 DABVP, Cert. IVUSS

IMAGING PERFORMED BY

Rebecca Hamilton

HOSPITAL NAME

Bond Vet Edgewater

REFERRING VET

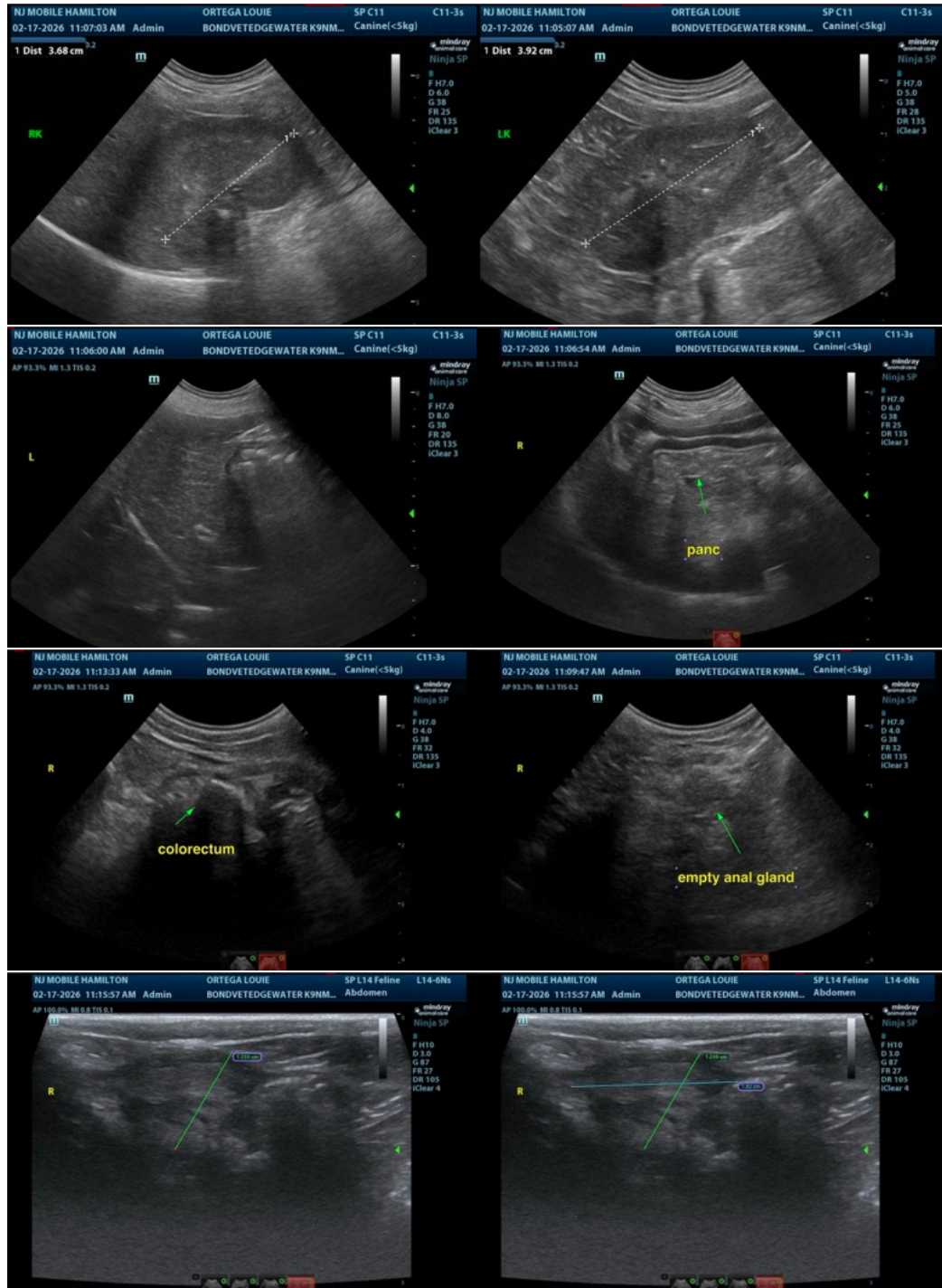
Dr. Odronez

INVOICE

71638

DATE

2/17/26





PATIENT

Louie Ortega

SPECIES

Canine

BREED

Shih Tzu

SEX

Neutered male

AGE

11 years

WEIGHT

5.7 kgs

INTERPRETED BY

Eric Lindquist, DMV
DABVP, Cert. IVUSS

IMAGING PERFORMED BY

Rebecca Hamilton

HOSPITAL NAME

Bond Vet Edgewater

REFERRING VET

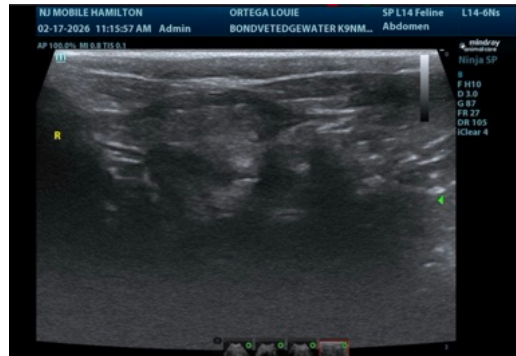Dr. Odronez

INVOICE

71638

DATE

2/17/26



The information and recommendations provided are based on the images presented by the referring veterinarian/sonographer. No evaluation can be communicated regarding pathology that was not visible in the image/video clips provided.

Thank you for this referral. If the clinical or image interpretation does not parallel your findings or if I can be of any further assistance please contact me.

Eric Lindquist, DMV, DABVP, Cert. IVUSS, CEO of SonoPath.com

info@SonoPath.com